Braz J Vet Pathol, 2026, vol. 19, Suppl. 1, e019S107
DOI: https://doi.org/10.24070/bjvp.1983-0246.019S107

BJVP
Brazilian Journal of Veterinary Pathology
ISSN 1983-0246

Diagnostic Exercise
From the Latin Comparative Pathology Group and the Davis-Thompson Foundation

Orbital meningioma in a French bulldog

Erin L Schwalbe[1], Luis S Tondo[1], Denver J Coleman[2], Abbigail Granger[2], Pilar Camacho-Luna[2], and Emi Sasaki[1]

[1] Department of Pathobiological Sciences and Louisiana Animal Disease Diagnostic Laboratory, School of Veterinary Medicine, Louisiana State University, Baton Rouge, LA
[2] Department of Veterinary Clinical Sciences, School of Veterinary Medicine, Louisiana State University, Baton Rouge, LA

***Corresponding author:** Emi Sasaki (emi@lsu.edu)

History: A 5-year-old castrated male French bulldog was presented for a history of complete loss of vision in the left eye. On ophthalmic examination, the left eye had both a negative dazzle reflex and menace response. No major clinical findings were noted in the right eye. Further examination of the left eye revealed exophthalmos and lagophthalmos with reduced retropulsion, a prolapsed nictitating membrane, conjunctival chemosis and hyperemia, geographic vascularization of the cornea with associated fibrosis of the inferior temporal cornea, and tortuous retinal vessels with optic nerve head atrophy and compressive deformation of the retina, which was noted on indirect ophthalmoscopy. Additionally, 1+ aqueous flare was noted as well as glaucoma of the left eye with a pressure of 28 mmHg. A compressive lesion deforming the posterior globe was noted on B-wave ultrasound. On MRI, a moderately contrast-enhancing mass that was isointense to hyperintense to the cerebral cortex on T1-W and T2-W images filled the left retro-orbit, resulting in dorsomedial displacement, exophthalmos, and compression of the left eye causing concavities at its posterior surface, giving the left globe a pyriform shape (Figure 1). The mass encircled the optic neurovascular bundle, which was moderate to severely thick and hypointense on all sequences. A rim of signal void

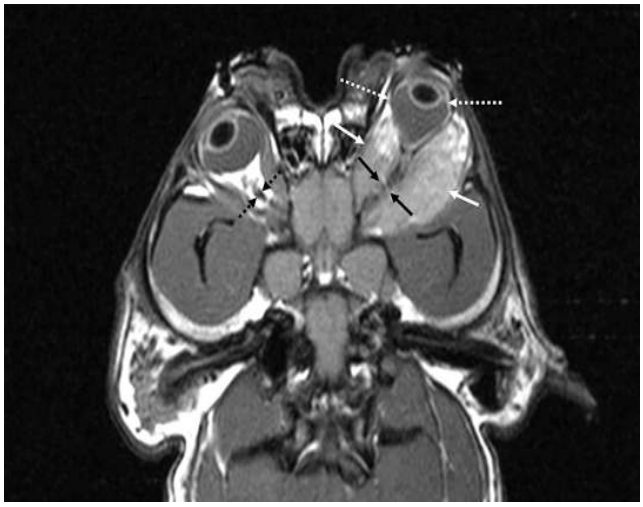

Figure1. Optimized coronal post-contrast T1-W image of the retroorbital space. A mass fills the entire left retro orbit (between solid white arrows), causing severe displacement and compression of the left eye (between dotted white arrows) as compared to the normal right eye. The left optic neurovascular bundle (between solid black arrows) is thick compared to the normal right neurovascular bundle (between dotted black arrows).

The Diagnostic Exercises are an initiative of the Latin Comparative Pathology Group (LCPG), the Latin American subdivision of The Davis-Thompson Foundation (DTF). These exercises are contributed by members and non-members from any country of residence. Consider submitting an exercise! A final document containing this material with answers and a brief discussion will be posted on the DTF website: https://davisthompsonfoundation.org/diagnostic-exercise/

Editor-in-chief for this Diagnostic Exercise: *Claudio Barros*
Associate Editor for this Diagnostic Exercise: *Andréia Vielmo*

surrounded the thickened left optic neurovascular bundle and was variably located in the T1 hyperintense regions within the mass, most consistent with mineralization, though chronic hemorrhage (hemosiderin) could not be ruled out (Figure 2). The remaining neuroparenchymal structures were normal with no intracranial origin or extension identified. Enucleation of the left eye was elected, and a firm space-occupying mass was appreciated in the retrobulbar space, corresponding to the space-occupying lesion noted on ultrasound and MRI.

Gross findings: The left eye with the retrobulbar mass and the periocular tissue were fixed in 10% buffered formalin and submitted for histopathological examination. On the posterior aspect of the left eye, there was a firm and pale tan mass measuring 3.2 cm in diameter, firmly attached to, and encompassing the region of the optic nerve and sclera (Figure 3).

Histopathology

Follow-up questions:

- *Gross and histopathological descriptions:*
- *Morphologic diagnosis:*
- *The origin of neoplastic cells:*

ANSWERS

Histopathology:

See Figures 4 and 5.

Histologic description:

The examined sections included the cornea, uvea, lens, retina, choroid, sclera, attached conjunctiva, and a non-encapsulated, poorly demarcated, and infiltrative mass that compressed the globe, resulting in a markedly narrowed posterior chamber (Figure 4A). The mass was composed of polygonal and spindloid neoplastic cells arranged in sheets, nests, and, rarely, densely packed bundles, supported by a fibrovascular stroma. The neoplastic cells had a large amount of eosinophilic cytoplasm with variably distinct cell borders, and a large eccentric, round to oval nucleus with finely stippled chromatin, with a prominent nucleolus. Sporadic bi- and tri-nucleation were also appreciated, as well as moderate anisocytosis and anisokaryosis and small multifocal



Figure 3. Sagittal cross section view of the left eye submitted for histopathological examination of a 5-year-old male castrated French bulldog. Encompassing the optic nerve and sclera is a pale tan, firm mass.

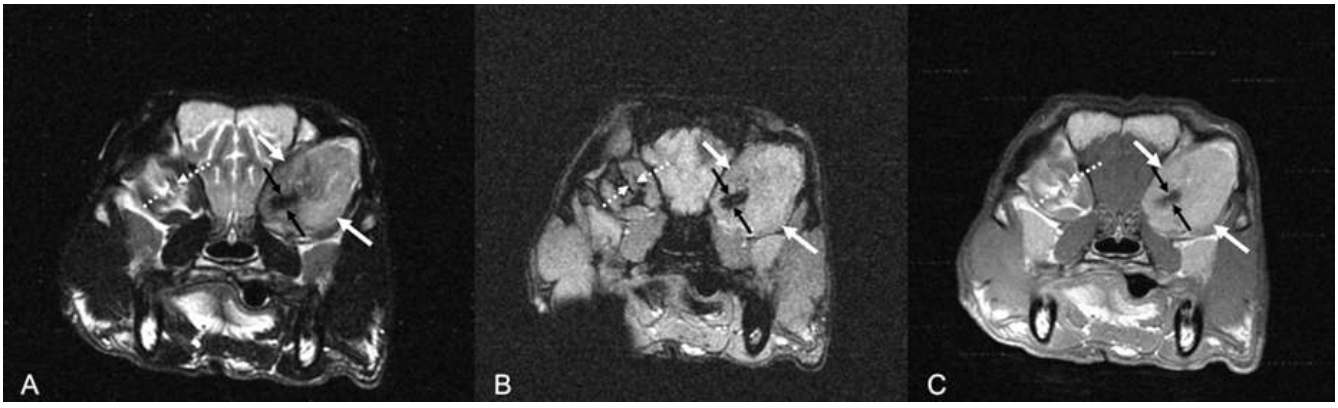

Figura 2. Transverse T2-W (A), T2* (B), and post-contrast T1-W (C) images of the retro orbit. A predominantly homogeneous mass fills the left retroorbital space (between solid white arrows). The mass encircles the left optic neurovascular bundle (between black arrows), which is thick compared to the contralateral side (between dotted white arrows). On the T2* sequence, the entire length of the left optic neurovascular bundle has a rim of signal void.

intra-tumoral necrosis. The mitotic count was 5 per 2.37mm^2 (equivalent to 10 FN22/400X fields or 10 high-power fields). In one examined section, multifocal to coalescing deposits of osseous matrix were within the mass (Figure 4B). On the posterior aspect of the globe, neoplastic cells compressed and invaded the optic nerve and sheath and focally invaded the sclera and choroid (Figure 5). Within the optic nerve, the neuroparenchyma was moderately vacuolated, with an increased number of glial cells. Additionally, there were areas of retinal detachment, and neoplastic cells infiltrated and dissected periocular myofibers and adipose tissue. In the anterior aspect of the eye, the corneal epithelium was vacuolated and, in some areas, hyperplastic. In the corneal stroma, moderate edema was present, along with scattered lymphocytes, macrophages, rare neutrophils, and fibroblasts. In-growing vessels oriented vertically to the corneal surface were also noted.

Morphologic diagnosis:

Orbital meningioma with optic nerve infiltration.

The origin of neoplastic cells: Arachnoid cells

Comments:

Orbital meningiomas are slow-growing and less common neoplasms in comparison to their central nervous system counterparts. They arise from the arachnoid cells surrounding the optic nerve and can invade into the connective and muscular tissue around the orbit (1,2), as seen in this case. Common clinical signs of an orbital meningioma include exophthalmos, ocular proptosis, orbital edema, lagophthalmos, abnormal or negative pupillary light reflex, and ipsilateral blindness (4). Diagnosis is often made through clinical findings, computed tomography, ultrasound, and MRI; however, histopathology is necessary to obtain a definitive diagnosis (4).

Typical gross appearances of an orbital meningioma include a tightly adhered tan slightly granular to solid mass with a conical shape on the posterior aspect of the globe, following the optic nerve (1,3). Histologically, these masses can have variable morphology including variability in cell size and organization; however, glassy eosinophilic cytoplasms, pleomorphic cells arranged in cords, nests, and lobules can be observed (1,3). Additionally, they often exhibit cartilaginous and osseous metaplasia, as observed in this case, or myxoid metaplasia (3), which are common and characteristic features of this neoplasm but are not seen in intracranial meningiomas.

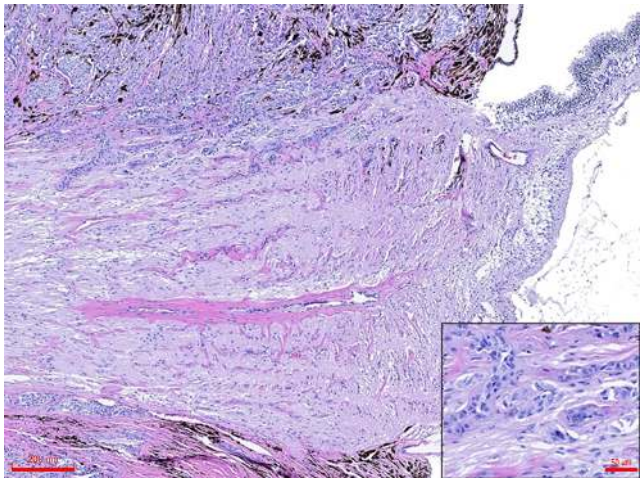

Figure 5: Photomicrograph of the left optic nerve. Clusters of polygonal and spindloid neoplastic cells infiltrate the optic nerve and focally invade the sclera and choroid; bar = 200 µm. Insert. Higher magnification showing neoplastic infiltration into the optic nerve. H&E stain; bar =50 µm.

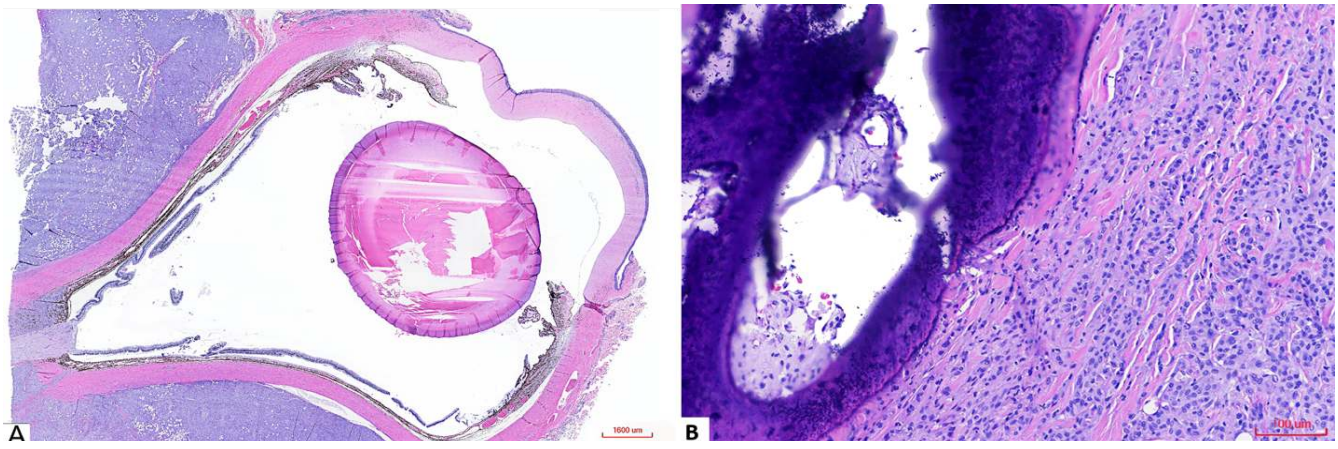

Figure 4. Photomicrograph of the submitted left eye. **A.** Examined section of the eye, including the cornea, uvea, lens, retina, choroid, sclera, and attached conjunctiva. In the posterior aspect of the eye, there is a poorly demarcated, non-encapsulated, infiltrative mass that is compressing the globe. Hematoxylin and eosin (H&E) stain; bar = 1600 µm. **B.** Deposit of osseous metaplasia within the mass. H&E stain; 10X; bar = 100 µm.

Whorl patterns and psammoma bodies, which are often characteristic of intracranial meningiomas, are rarely observed and can make differentiation of orbital meningiomas from other neoplasms difficult (1,3). Thus, potential differentials for retrobulbar masses include other neoplasms such as squamous cell carcinoma and other invasive carcinomas (1,4). In this case, the extension of a nasal cavity neoplasm was ruled out due to the lack of evidence of nasal cavity involvement on MRI, and no prominent areas of inflammation were observed to consider abscessation or a granuloma. Thus, anatomic location associated with the morphologic features of areas of osseous matrix deposits, which is often a hallmark feature, suffices for the diagnosis of an orbital meningioma. Calcification of the optic nerve and orbital tumors is a common feature, as seen in this case on MRI diagnostic imaging and on histologic sections. There are no specific immunohistochemistry markers for periocular meningiomas in dogs; however, meningiomas have immunoreactivity for vimentin, S100, occasionally E-cadherin, and are negative for cytokeratin (1,3,4). The immunohistochemistry pattern is helpful to differentiate meningiomas from other differentials, such as carcinomas, which in some cases can present similar morphologic cellular features and can occur due to extension of a nasal cavity neoplasm (4)

Treatment for orbital meningiomas is often directed at aggressive surgical exenteration of the globe and the complete orbital contents with follow-up of radiation therapy in dogs (3,4,5). Survival, postoperatively with surgery alone, averages 1.7 years and has been reported up to 4.5 years (3). Recurrence locally is possible as well as extension and infiltration into the optic chiasm

resulting in blindness in the other eye (3). Early evidence of the mean survival time with surgery and radiation is 943 days (5). Overall, treatment protocol, success, and follow-up length can vary amongst patients, and intracranial extension is an important characteristic when considering optimal care for the patient.

References:

1. Dubielzig R. Tumors of eye. In: Tumors in Domestic Animals. 5th ed. John Wiley & Sons; 2017. p. 915-6.
2. Langham RF, Bennett RR, Zydeck FA. Primary Retrobulbar Meningioma of the Optic Nerve of a Dog. J Am Vet Med A. 1971; 159 (2): 175-6.
3. Mauldin EA, Deehr AJ, Hertzke D, Dubielzig RR. Canine orbital meningiomas: a review of 22 cases. Vet Ophthalmol. 2000; 3(1): 11-6.
4. Regan DP, Kent M, Mathes R, Almy FS, Moore PA, Howerth EW. Clinicopathologic findings in a dog with a retrobulbar meningioma. J Vet Diagn Invest. 2011; 23(4): 857-62.
5. Uno A, Iwasaki R, Mori T. Treatment outcomes of canine orbital meningiomas in seven cases. J Am Anim Hosp Assoc. 2025; 61(1): 1-6.