Braz J Vet Pathol, 2026, vol. 19, Suppl. 1, e019S108
DOI: https://doi.org/10.24070/bjvp.1983-0246.019S108

BJVP
Brazilian Journal of Veterinary Pathology
ISSN 1983-0246

Diagnostic Exercise
From the Latin Comparative Pathology Group and the Davis-Thompson Foundation

Xanthogranulomatous dermatitis and cutaneous lymphoma in a chicken

Laura Diehl[1], Robert B Moeller Jr[2], Asli Mete[3], Nicolás Streitenberger[4]

[1]District Office North Saxony, Germany; [2]California Animal Health and Food Safety Laboratory System, Tulare Branch, [3D]avis Branch and [4]San Bernardino Branch University of California, Davis, CA, USA[4].

***Corresponding author:** streitenberger@ucdavis.edu

History: A five-year-old layer presented with a one--month history of progressive decline in overall condition, characterized by reduced activity and general unthriftiness. The owner reported the presence of persistently swollen feather follicles located dorsally and ventrally on both wings, observed for an undetermined duration prior to presentation. In an effort to manage the follicular swelling, the bird was administered liquid diphenhydramine (Benadryl) orally over a three-day period; no significant improvement was noted.

Approximately 24 hours prior to euthanasia, the hen exhibited acute respiratory signs, including audible wheezing, along with complete anorexia. Given the rapid clinical deterioration and poor prognosis, the hen was humanely euthanized.

Gross findings: The carcass is in fair nutritional condition with moderate amounts of visceral and subcutaneous fat reserves, and in a mild state of post-mortem decomposition. The wings have multiple large, firm, yellow, oval masses measuring approximately 1 × 0.5 × 0.5 cm, located between the feather follicles. Swelling of the more distal wing tissues was also observed (Fig. 1). The spleen was enlarged approximately fourfold, with numerous white masses up to 0.4 cm in diameter present throughout the parenchyma. The liver exhibited multifocal pinpoint off-white spots scattered within the hepatic parenchyma.

Histologic description

The superficial dermis is severely expanded by numerous large, foamy macrophages interspersed with many clear, acicular cholesterol clefts (Fig. 2). Among the macrophages and cholesterol clefts are perivascular clusters of atypical round cells, consisting of a mix of atypical cells and more mature lymphocytes (Fig. 3 and Fig. 4). These cells infiltrate deeper into the dermal connective tissue, extending away from the cholesterol clefts. The large, atypical round cells exhibit abundant amphophilic to lightly basophilic cytoplasm, large moderately stippled nuclei, and a single nucleolus. One mitotic figure is observed per 2.37 mm². Smaller, more mature lymphocytes with hyperchromatic

**The Diagnostic Exercises are an initiative of the Latin Comparative Pathology Group (LCPG), the Latin American subdivision of The Davis-Thompson Foundation (DTF). These exercises are contributed by members and non-members from any country of residence. Consider submitting an exercise! A final document containing this material with answers and a brief discussion will https://davisthompsonfoundation.org/diagnostic-exercise/*

Editor-in-chief for this Diagnostic Exercise: *Claudio Barros*
Associate Editor for this Diagnostic Exercise: *Andréia Vielmo*

nuclei are scattered among the atypical cells. Cellular debris is present throughout the affected areas. The overlying epithelium is multifocally ulcerated and replaced by a serocellular crust composed of fibrin, cellular debris, degenerate inflammatory cells, heterophils, plant material fragments, and red blood cells.

Morphological Diagnosis

Skin (wings):
- Severe, xanthogranulomatous dermatitis with cholesterol clefts, necrosis, phagocytized and extracellular lipid, and multifocal epithelial ulceration
- Cutaneous lymphoma

Differential diagnosis:

Xanthogranulomatosis
Avian Leukosis or Marek's disease
Diagnostic methods: Oil Red O stain, immunohistochemistry (CD3 and pax5)

Comments:

The cutaneous lesions observed in this chicken are consistent with xanthogranulomatosis (xanthoma) in association with cutaneous lymphoma. Xanthogranulomatosis,

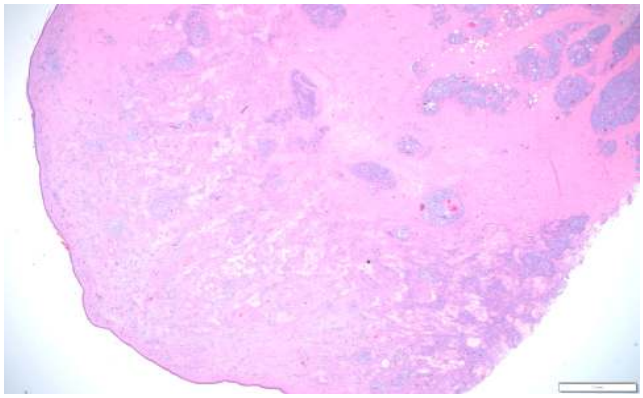

Figure 2. Skin. Multiple densely cellular nodules including multiple, pale eosinophili areas.

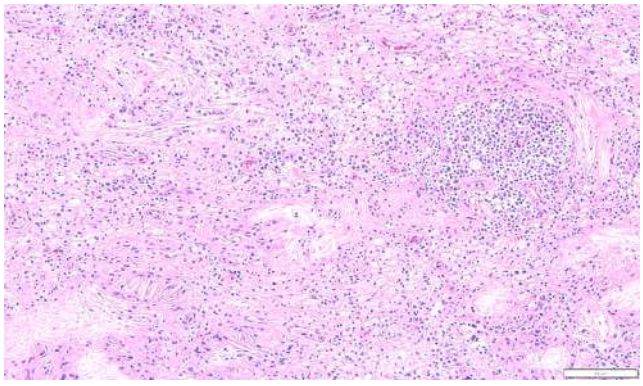

Figure 3. Skin (dermis): Densely cellular neoplastic infiltrates, numerous foamy macrophages and frequent acicular clefts (cholesterol clefts).





Figure 1. Hen. Bilateral swelling of the feather follicles affecting the wings. Close-up view picture of the left wing.

Braz J Vet Pathol, 2026, vol. 19, Suppl. 1, e019S108
DOI: https://doi.org/10.24070/bjvp.1983-0246.019S108

also referred to as xanthoma, xanthomatosis, or xanthogranulomas, is a tumor-like condition characterized by localized accumulation of cholesterol-rich lipids and lipid-laden macrophages within the dermis and subcutaneous tissue. The term *xanthoma* is derived from the Greek words *xanthos* ("yellow") and *oma* ("mass").

Xanthomas are uncommon in chickens but are more frequently reported in pet birds, including budgerigars, cockatiels, and eclectus parrots. They have also been described in other avian species, including pigeons, as well as rarely in mammals (e.g., dogs) and humans. In birds, cutaneous xanthomas typically present grossly as yellow to tan, firm, well-demarcated plaques or masses that are usually not associated with ulceration of the overlying skin. Histologically, these lesions are composed of lipid-laden (foamy) macrophages, dispersed cholesterol clefts, necrotic cellular debris, multinucleated giant cells, and occasional mineralization. Lipid within these lesions stains red with Oil Red O. Disseminated forms, including intracoelomic xanthogranulomatosis, have also been reported in birds, in which case differential diagnoses at necropsy include mycobacteriosis, aspergillosis, egg yolk peritonitis, and diffuse neoplastic disease.

The etiology and pathogenesis of xanthogranulomatosis remain poorly understood and are likely multifactorial. Proposed contributing factors include hypercholesterolemia or hypertriglyceridemia associated with high-fat or high-cholesterol diets, lipid metabolism disorders, fat-related toxic hydrocarbons in feed, endocrine or metabolic abnormalities, pancreatitis, and chronic irritation or trauma. Xanthomas are thought to originate from abnormal dermal lipid deposition, which stimulates macrophage recruitment; phagocytosis of cholesterol by these macrophages results in their characteristic foamy appearance. Recent studies have documented concurrent atherosclerosis in birds with xanthogranulomatosis, suggesting a possible shared or related pathogenesis between these conditions.

In the present case, the xanthomatous lesion was notably infiltrated by neoplastic round cells consistent with lymphoma. Neoplastic lymphoid infiltrates were also identified in multiple organs, including the spleen, liver, lungs, kidneys, heart, mesenteric connective tissue, and skin. Two distinct populations of neoplastic lymphoid cells were observed: a larger, atypical lymphocyte population and a smaller, more mature-appearing lymphocyte population. This histologic pattern is most consistent with Marek's disease, a lymphoproliferative disorder of chickens caused by Gallid alphaherpesvirus type 2. Marek's disease is characterized by infiltration of neoplastic mononuclear cells—predominantly $CD4^+$ T lymphocytes—into multiple organs, including peripheral nerves, skin, and viscera. However, infection with avian leukosis virus (a retrovirus) remains an important differential diagnosis.

Differentiation between Marek's disease and avian leukosis is critical and can be supported by immunohistochemistry. T-cell lymphomas typically express CD3 and CD4 (Fig 5), whereas B-cell lymphomas associated with avian leukosis are positive for PAX-5.

While xanthomas are generally regarded as metabolic or reactive lesions, the presence of neoplastic lymphoid infiltration within the xanthomatous lesion in this case suggests a more complex pathogenesis involving an underlying lymphoproliferative disease. Infiltration of neoplastic T lymphocytes into the dermis and subcutis may promote local inflammation, macrophage activation, and altered lipid handling, thereby triggering or exacerbating lipid accumulation and foam cell formation.

Although this association has not been formally described in avian species, parallels exist in the human literature. Rare cases of xanthomatous change occurring secondary to cutaneous T-cell lymphoma have been reported, including dystrophic xanthomatosis associated with various forms of cutaneous T-cell lymphomas. These reports propose a pathogenetic link between lymphoproliferation and abnormal dermal lipid deposition. Further investigation is warranted to better elucidate this potential relationship in avian species.

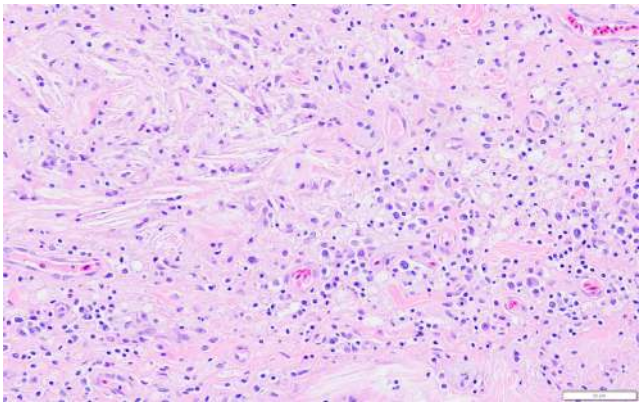

Figure 4. Skin (dermis): Infiltrates of neoplastic round cells. Numerous foamy macrophages and frequent acicular clefts (cholesterol clefts) are also noted.

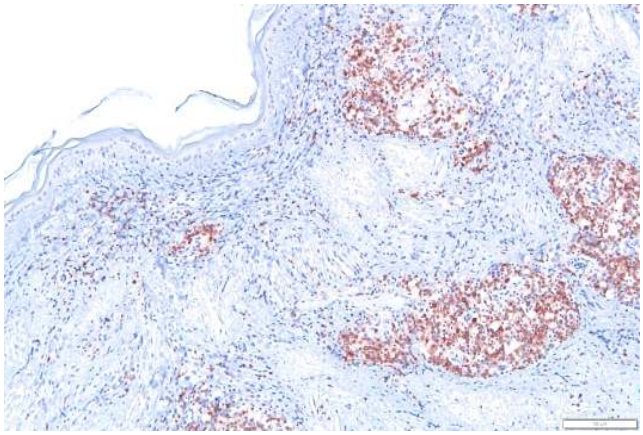

Figure 5. The majority of neoplastic lymphocytes exhibited immunolabeling for CD3.

References:

1. Kheirandish R, Azizi S, Azari O. Cutaneous Xanthoma in a Domestic Pigeon: Pathologic Study (Case Report). *Global Veterinaria*. 2013; 10(2):140-143.
2. Swayne, D. E. (2013). Diseases of poultry. John Wiley & Sons.
3. Giménez S, Gallardo F, Curcó N, Marcoval J, Romagosa V, Servitje O, Pujol RM. Dystrophic xanthomatosis in primary CD30-positive cutaneous T-cell lymphoma. Report of two cases and review of the literature. *Dermatology*. 2005;211(3):267-72. doi: 10.1159/000087022. PMID: 16205073.
4. Hanson ME, Donovan TA, Quesenberry K, Dewey A, Brown C, Chen S, Le Roux AB. Imaging features of disseminated xanthogranulomatous inflammation in eclectus parrots (Eclectus roratus). *Vet Radiol Ultrasound*. 2020 Jul;61(4):409-416. doi: 10.1111/vru.12861. Epub 2020 May 20. PMID: 32436257.
5. Boodhoo N, Gurung A, Sharif S, Behboudi S. Marek's disease in chickens: a review with focus on immunology. *Vet Res*. 2016 Nov 28;47(1):119. doi: 10.1186/s13567-016-0404-3. PMID: 27894330; PMCID: PMC5127044.
6. Darwin, B. S., Herzberg, A. J., Murray, J. C., & Olsen, E. A. (1992). Generalized papular xanthomatosis in mycosis fungoides. *J Am Acad Dermatol*. 26(5), 828-832.
7. Meinecke, C. F., Flowers, A. I., & Beasley, J. N. (1962). Observations of xanthomatosis in chickens.
8. Pazhanivel, N., Balachandran, C., Saahithya, R., Sudhakar Rao, G. V., Shafiuzama, M., & Krishnaveni, N. (2018). A case report of cutaneous xanthoma in a cockatiel (Nymphicus hollandicus).*J Entomol Zool Stud*. 6(5), 556-558.
9. D.A. Pass (1989) The pathology of the avian integument: A review. *Avian Pathol*, 18:1, 1-72, DOI: 10.1080/03079458908418580
10. Abdul-Aziz, T., & Barnes, H. J. (2018). Gross pathology of avian diseases: text and atlas. American Association of Avian Pathologists (AAAP).