Braz J Vet Pathol, 2026, vol. 19, Suppl. 1, e019S110
DOI: https://doi.org/10.24070/bjvp.1983-0246.019S110

BJVP
Brazilian Journal of Veterinary Pathology
ISSN 1983-0246

Diagnostic Exercise
From the Latin Comparative Pathology Group and the Davis-Thompson Foundation

Primary cardiac hemangiosarcoma originating at the right atrio ventricular valve and projecting into the right ventricular outflow tract in a dog

Daiana N. Merida[1], Giulio Menciotti[1] and Francisco R Carvallo[1]
[1]Virginia Maryland College of Veterinary Medicine, Virginia Tech, Blacksburg, VA

Corresponding author: fcarvallo@vt.edu

History: The body of a 4.5-year-old female spayed Boxer mix dog was submitted for necropsy. The patient had a 2–3-month history of a soft, non-productive cough prior to referral. Previous diagnostics performed by the referring veterinarian included a negative SNAP 4Dx Plus test. Upon referral evaluation, thoracic radiographs reportedly demonstrated a moderate diffuse bronchial pattern, and no prior medications had been administered. Nine days later, computed tomography (CT), bronchoscopy, and bronchoalveolar lavage (BAL) were performed. Thoracic CT revealed multifocal pulmonary nodules and patchy alveolar infiltrates most suspicious for metastatic neoplasia. Bronchoscopy revealed diffuse bronchial hemorrhage, and BAL findings were consistent with chronic hemorrhage and mixed inflammatory cells. Abdominal radiographs obtained the following week revealed no evidence of a primary mass. Subsequently, BAL culture yielded a suspected *Mycobacterium* species, and treatment with moxifloxacin, doxycycline, and prednisone was initiated. Although clinical improvement was initially observed, the patient developed increased respiratory rate and effort after 10 days of treatment. The patient's respiratory status progressively deteriorated over the following two days before presenting deceased to a local emergency hospital. The carcass was submitted to the Virginia-Maryland College of Veterinary Medicine for necropsy.

Necropsy findings: The carcass is received in good postmortem condition with a body condition score of 6/9. Approximately 50 mL of dark red low-viscosity fluid is present within the thoracic cavity. The lungs have numerous well-demarcated, round, red nodules measuring 0.2 to 1 cm in diameter, involving greater than 50% of the pulmonary parenchyma (Fig. 1). The right auricle of the heart was slightly dilated, diffusely mottled with a purple discoloration. A 1 x 1 x 1 cm firm, dark red to purple mass was located on the ventricular aspect of the septal leaflet of the tricuspid valve (Fig. 2). Originating from this mass was a 2 x 2 x 9 cm conglomerate of intertwined stringy, firm, white and pink material extending into the pulmonary artery and resulting in a near-complete occlusion of the right ventricular outflow tract and pulmonary artery. An estimated 100 mL of dark red low-viscosity fluid was present within the abdominal cavity.

**The Diagnostic Exercises are an initiative of the Latin Comparative Pathology Group (LCPG), the Latin American subdivision of The Davis-Thompson Foundation (DTF). These exercises are contributed by members and non-members from any country of residence. Consider submitting an exercise! A final document containing this material with answers and a brief discussion will* https://davisthompsonfoundation.org/diagnostic-exercise/

Editor-in-chief for this Diagnostic Exercise: *Claudio Barros*
Associate Editor for this Diagnostic Exercise: *Francisco Carvallo*

Braz J Vet Pathol, 2026, vol. 19, Suppl. 1, e019S110
DOI: https://doi.org/10.24070/bjvp.1983-0246.019S110

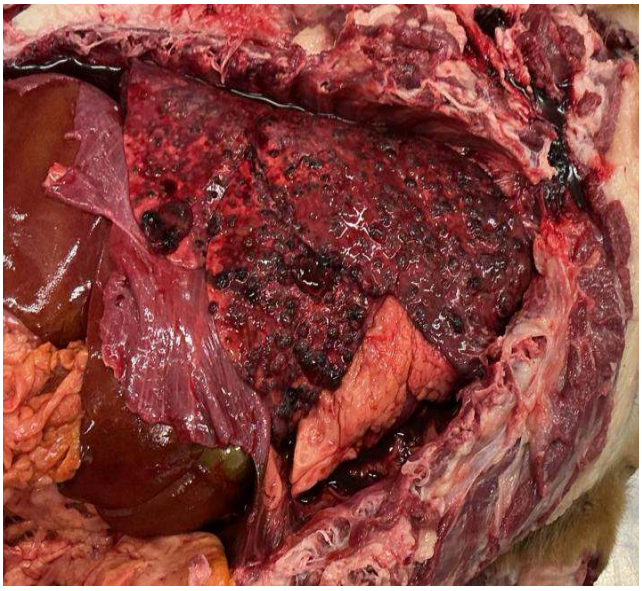

Figure 1: Right Lung, dog. Multifocal well-demarcated, round, red nodules measuring 0.2 to 1 cm in diameter dispersed all throughout.

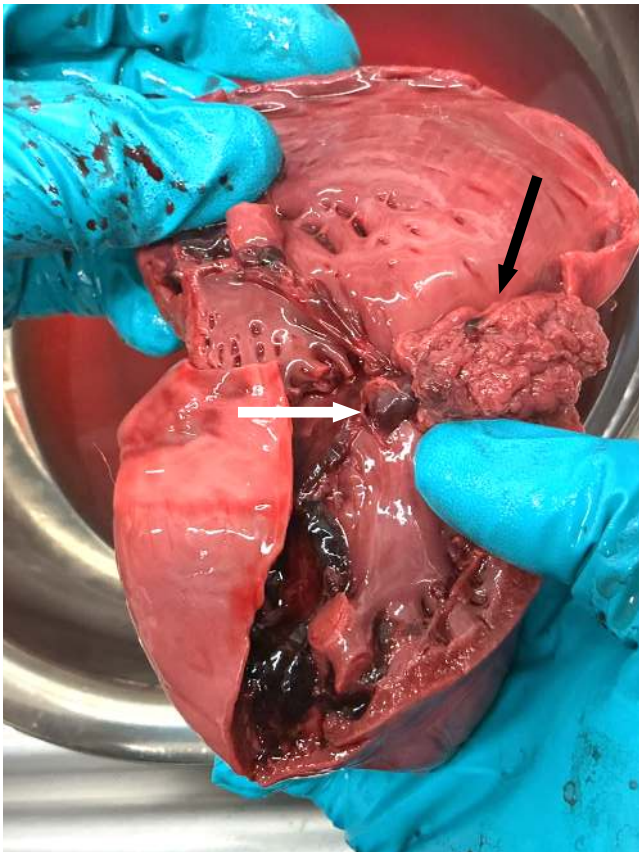

Figure 2: Heart, dog. Red to purple mass (white arrow) located on the ventricular aspect of the septal leaflet of the tricuspid valve with an attached proliferative growth composed of a conglomerate of intertwined stringy, firm, white and pink material extending into the pulmonary artery (black arrow).

Follow-up questions:

- *Morphologic diagnosis*
- *Possible differentials*

Histopathology

Histologic description:

- **Mass originating at the tricuspid valve**: At the margin of the atrioventricular valve, the mass is composed of elongated cells with small amounts of eosinophilic cytoplasm, sustained in a fine fibrous stroma (Figs. 3 A and 3B). The portion of the mass that is projecting into the lumen of the right ventricle is composed of a poorly demarcated, nonencapsulated, dense cellular aggregates of markedly anaplastic neoplastic cells, all sustained in small amounts of fibrovascular stroma. Individual cells are elongated to polyhedral, have moderate to abundant pale basophilic cytoplasm with conspicuous cell margins. Nuclei are oval to pleomorphic, with vesicular chromatin, one or two prominent nucleoli, and marked anisokaryosis. There are one or two mitoses in each high-power field, some of them highly atypical (Fig. 3C). It is very frequent to find multinucleated cells within the mass, with up to eight nuclei. Also, there are multifocal areas of necrosis and occasional hemorrhages. Neoplastic cells are moderately positive for Factor VIII immunohistochemistry (Fig. 3D)
- **Tricuspid valve**: Expanded with moderate amounts of myxomatous tissue (Fig. 3A).

Other histopathology findings (not included):

- **Right auricle**: No histologic evidence of neoplastic process is identified in the section. A focal, very small area of myocardial degeneration/necrosis, encompassing a few fibers is noted.
- **Lung:** Effacing most of the parenchyma, there are multiple, poorly demarcated masses, composed of elongated cells similar to those described above, lining irregular vascular channels. There are numerous thrombi, multiple areas of necrosis and extensive hemorrhages within the masses, and also extending into the adjacent pulmonary parenchyma.
- **Kidney**: Mild segmental thickening of the mesangium is multifocally observed in glomeruli. No significant findings in the rest of the parenchyma.
- **Liver**: There is hydropic vacuolar degeneration of centrilobular areas, plus the presence of occasional fibrin thrombi in hepatic sinusoids. Also, moderate intrahepatic cholestasis is noted.

Braz J Vet Pathol, 2026, vol. 19, Suppl. 1, e019S110
DOI: https://doi.org/10.24070/bjvp.1983-0246.019S110

Morphologic diagnosis:

1. Heart, atrioventricular valve:
a. hemangiosarcoma originating at the right atrio ventricular valve and projecting into the right ventricle outflow tract.
b. Myxomatous degeneration, moderate.

2. Lung: hemangiosarcoma, metastatic.

Other morphologic diagnoses (not included):

3. Heart, right auricle: myocardial degeneration/necrosis, multifocal.

4. Kidney: membranous glomerulopathy segmental, multifocal, mild.

5. Liver: centrilobular vacuolar degeneration; fibrin thrombi in sinusoids.

Comments:

Hemangiosarcoma (HSA) is a malignant mesenchymal neoplasm arising from vascular endothelial cells. It is a highly aggressive neoplasm that metastasizes early in the disease course, typically affecting middle-aged to older dogs between 7 and 15 years of age (1, 10). HSA most frequently arises in the spleen, liver, right auricle of the heart, and

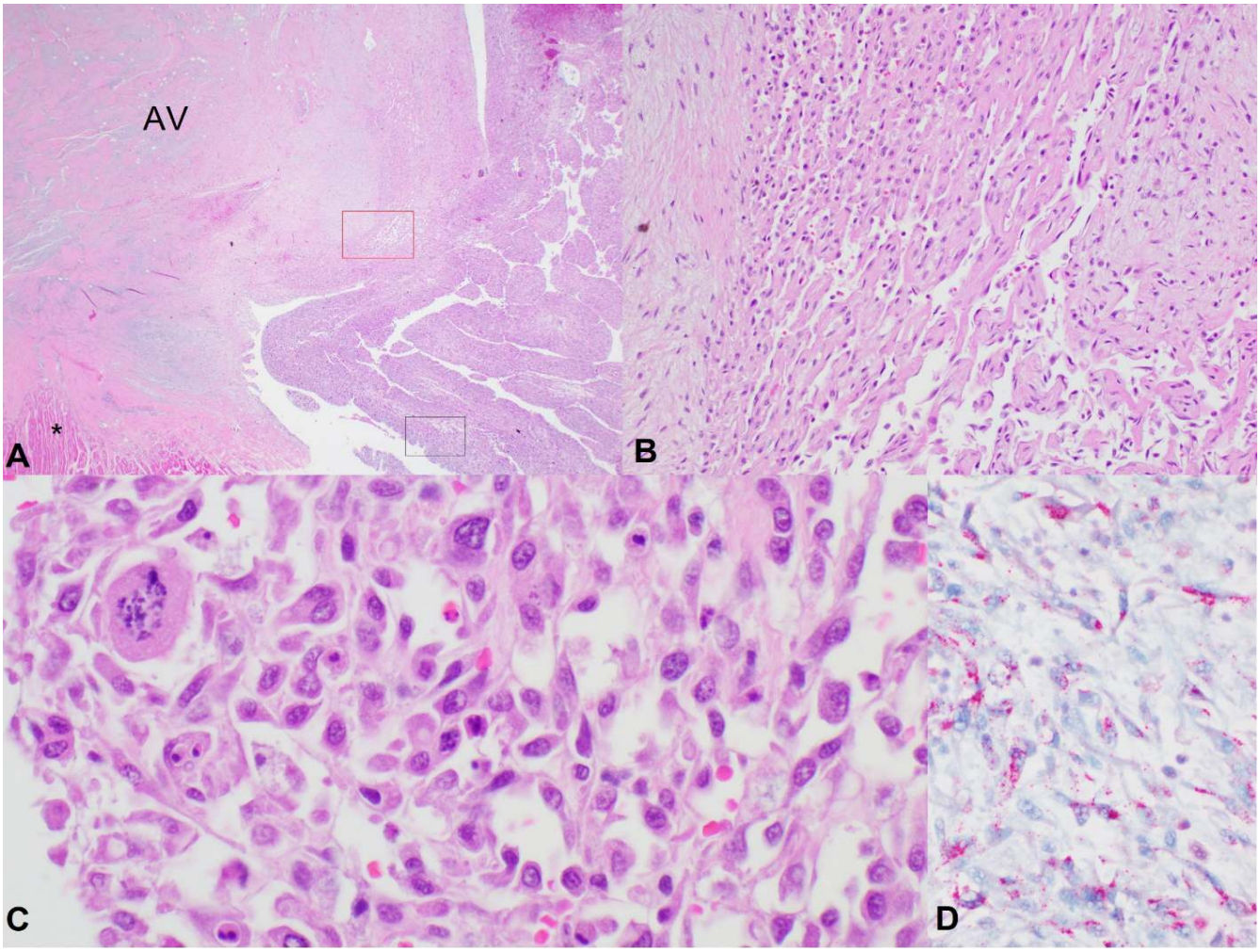

Figure 3. Histopathology of the mass located at the right atrioventricular valve. Figure A. Low magnification of the interventricular septum (*) and atrioventricular valve (AV), with moderate amounts of slightly basophilic extracellular material (myxomatous degeneration). Hematoxylin and eosin, 40X. **B.** Histopathology of the area included in the red rectangle on figure A. The mass is composed of bland elongated cells sustained in a fine stroma, lining slit-like spaces. Hematoxylin and eosin, 100X**. C.** Histopathology of the area included in the blue rectangle on figure A. The cells are elongated to polyhedral, with marked anisocytosis and anisokaryosis. One highly atypical mitotic figure is identified (upper left). Hematoxylin and eosin, 200X. **D.** Immunohistochemistry for factor VIII. Neoplastic cells have granular red stain in the cytoplasm. Chromo red (Ventana®) and Mayer's hematoxylin counterstain, 200X.

subcutaneous tissues, with the lungs and liver representing the most common sites of metastasis (2).

Histologically, hemangiosarcoma is characterized by the formation of irregular, tortuous, anastomosing blood-filled vascular channels lined by neoplastic endothelial cells (2, 6). The fragile nature of these vascular channels makes them highly susceptible to rupture, often leading to hemorrhage and secondary tissue necrosis (2). Many of the clinical signs associated with hemangiosarcoma, such as lethargy, weakness, pale mucous membranes, collapse, and cavitary effusion, are a direct result of this process (5, 8). A definitive diagnosis is established through histopathologic evaluation (8). Immunohistochemistry (IHC) is often used as a confirmatory diagnostic tool when the neoplasm is poorly differentiated or histologically ambiguous (9). In these cases, positive immunoreactivity for markers such as CD31, CD34, and von Willebrand factor (factor VIII-related antigen) supports a diagnosis of hemangiosarcoma (7).

Hemangiosarcoma (HSA) is the most common primary cardiac neoplasm in dogs, accounting for approximately 69% of all cardiac tumors with histologic diagnosis (10). Although hemangiosarcoma most commonly arises from the right atrium or right auricular appendage, involvement of the atrioventricular valve or right ventricle is exceptionally rare and has limited documentation in the veterinary literature (4, 8, 11). The present case represents an unusual example of primary right ventricular hemangiosarcoma arising at the septal aspect of the tricuspid valve in a female spayed Boxer mix dog. The diagnosis was supported by positive immunoreactivity for factor VIII on immunohistochemistry. Despite the relatively small primary mass, gross examination revealed an infiltrative meshwork of white and pink tissue strands extending from the cardiac tumor into the right ventricular outflow tract towards the pulmonary artery, resulting in a near-complete occlusion of the pulmonary artery.

The extensive meshwork initially raised suspicion for secondary thrombus formation within the right ventricular outflow tract. However, histopathologic evaluation revealed that the material was composed of dense mats of highly atypical neoplastic endothelial cells, identical to those comprising the primary mass. This finding confirmed extensive intraluminal projection of the neoplasm, rather than thrombus formation. The resulting right ventricular outflow obstruction likely contributed to the patient's progressive dyspnea and eventual acute collapse by severely impairing pulmonary perfusion. Despite marked right ventricular outflow obstruction, significant right ventricular or right atrial myocardial hypertrophy was not observed. This finding may suggest that intraluminal expansion of the hemangiosarcoma and subsequent occlusion may have occurred rapidly prior to any compensatory myocardial remodeling.

Hematogenous dissemination of the cardiac hemangiosarcoma was supported by the presence of multifocal to coalescing pulmonary nodules and widespread intravascular embolic foci distributed throughout the pulmonary tissue. Rupture of these metastatic lesions likely contributed to the hemothorax observed at necropsy. Centrilobular degeneration of the liver was attributed to systemic hypoxia and circulatory compromise resulting from the marked obstruction of pulmonary blood flow. The presence of numerous fibrin thrombi within the hepatic sinusoids raised concern for disseminated intravascular coagulation (DIC) as a component of the terminal systemic process. However, further diagnostics were not performed prior to the patient's death.

References:

1. Boes KM, Durham AC. Bone marrow, blood cells, and the lymphoid/lymphatic system. In: Zachary JF, editor. Pathologic Basis of Veterinary Disease. 7th ed. St. Louis (MO): Elsevier; 2022. p. 785-6.
2. Brown NO. Hemangiosarcomas. Vet Clin North Am Small Anim Pract. 1985;15(3):569-75.
3. Brown NO, Patnaik AK, MacEwen EG. Canine hemangiosarcoma: retrospective analysis of 104 cases. J Am Vet Med Assoc. 1985;186(1):56-8.
4. Franchini A, Menciotti G, Persons R, Diab S. Hemangiosarcoma involving the interventricular and interatrial septum, atrioventricular node, and right ventricle, causing atrioventricular block and ventricular arrhythmias in a dog. J Vet Cardiol. 2026;63:75-80.
5. Hammer AS. Hemangiosarcoma. In: Rosenthal RC, editor. Veterinary Oncology Secrets. Philadelphia (PA): Hanley & Belfus; 2001. p. 199-205.
6. Kleine LJ, Zook BC, Munson TO. Primary cardiac hemangiosarcomas in dogs. J Am Vet Med Assoc. 1970;157(3):326-37.
7. Meuten DJ. Tumors of the blood and lymphatic vessels. In: Meuten DJ, editor. Tumors in Domestic Animals. 5th ed. Ames (IA): Wiley Blackwell; 2017. p. 162-63.
8. Mullin C, Clifford CA. Hemangiosarcoma. In: Vail DM, Thamm DH, Liptak JM, editors. Withrow & MacEwen's Small Animal Clinical Oncology. 6th ed. St. Louis (MO): Elsevier; 2020. p. 773-8.
9. von Beust BR, Suter MM, Summers BA. Factor VIII-related antigen in canine endothelial neoplasms: an immunohistochemical study. Vet Pathol. 1988;25(4):251-5.
10. Ware WA, Hopper DL. Cardiac tumors in dogs: 1982-1995. J Vet Intern Med. 1999;13(2):95-103.
11. Yamamoto S, Hoshi K, Hirakawa A, Chimura S, Kobayashi M, Machida N. Epidemiological, clinical and pathological features of primary cardiac hemangiosarcoma in dogs: a review of 51 cases. J Vet Med Sci. 2013;75(11):1433-41