Braz J Vet Pathol, 2026, vol. 19, Suppl. 1, e019S109
DOI: https://doi.org/10.24070/bjvp.1983-0246.019S109

BJVP
Brazilian Journal of Veterinary Pathology
ISSN 1983-0246

Diagnostic Exercise
From the Latin Comparative Pathology Group and the Davis-Thompson Foundation

Cutaneous mast cell tumor in an Arabian gelding

Sahar Abdelrahman[1] and Ji-Hang Yin[2]
[1]Kansas Veterinary Diagnostic Laboratory, College of Veterinary Medicine/Diagnostic Medicine/[2]Pathobiology, Kansas State University

***Corresponding author:** jihangyin@ksu.edu

History: A cutaneous mass of unknown duration from the left upper lip of an Arabian gelding was submitted for histopathologic evaluation.

Gross findings: The submitted formalin-fixed haired skin mass measured 5.2 × 4.5 × 1.7 cm. On, the dermis was expanded by a pale tan nodule with multiple, variably sized, irregular, tan, measuring up to 0.25 × 0.1 cm, foci (Figure 1).

Gross and Histopathologic Images:

Histologic description:

Expanding and effacing the dermis and subcutis and infiltrating to the skeletal muscle is unencapsulated, poorly demarcated, moderately cellular neoplasm and multiple variably sized eosinophilic granulomas separated by variable thickness of fibrovascular stroma (Figure 2A B). The neoplasm is composed of round cells that are individualized or arranged in cords, nests, or sheets with distinct cell borders and moderate amounts of amphophilic cytoplasm that contains fine basophilic granules admixed with variable numbers of eosinophils (Figure 2C). Nuclei are centrally located, round to oval with finely to coarsely stippled chromatin and indistinct nucleoli. No overt mitotic figures in ten standardized 400x fields (2.37 mm2). Scattered throughout the neoplasm are moderate numbers of eosinophils. Eosinophilic granulomas are composed of



Figure 1. Photograph of the formalin-fixed haired skin mass from the left upper lip of an Arabian gelding. The dermis is focally expanding by a pale tan nodule with multiple, variably sized, irregular, tan, up to 0.25 × 0.1 cm, foci.

*The Diagnostic Exercises are an initiative of the Latin Comparative Pathology Group (LCPG), the Latin American subdivision of The Davis-Thompson Foundation (DTF). These exercises are contributed by members and non-members from any country of residence. Consider submitting an exercise! A final document containing this material with answers and a brief discussion will https://davisthompsonfoundation.org/diagnostic-exercise/

Editor-in-chief for this Diagnostic Exercise: *Claudio Barros*
Associate Editor for this Diagnostic Exercise: *Ji-Hang Yin*

Braz J Vet Pathol, 2026, vol. 19, Suppl. 1, e019S109
DOI: https://doi.org/10.24070/bjvp.1983-0246.019S109

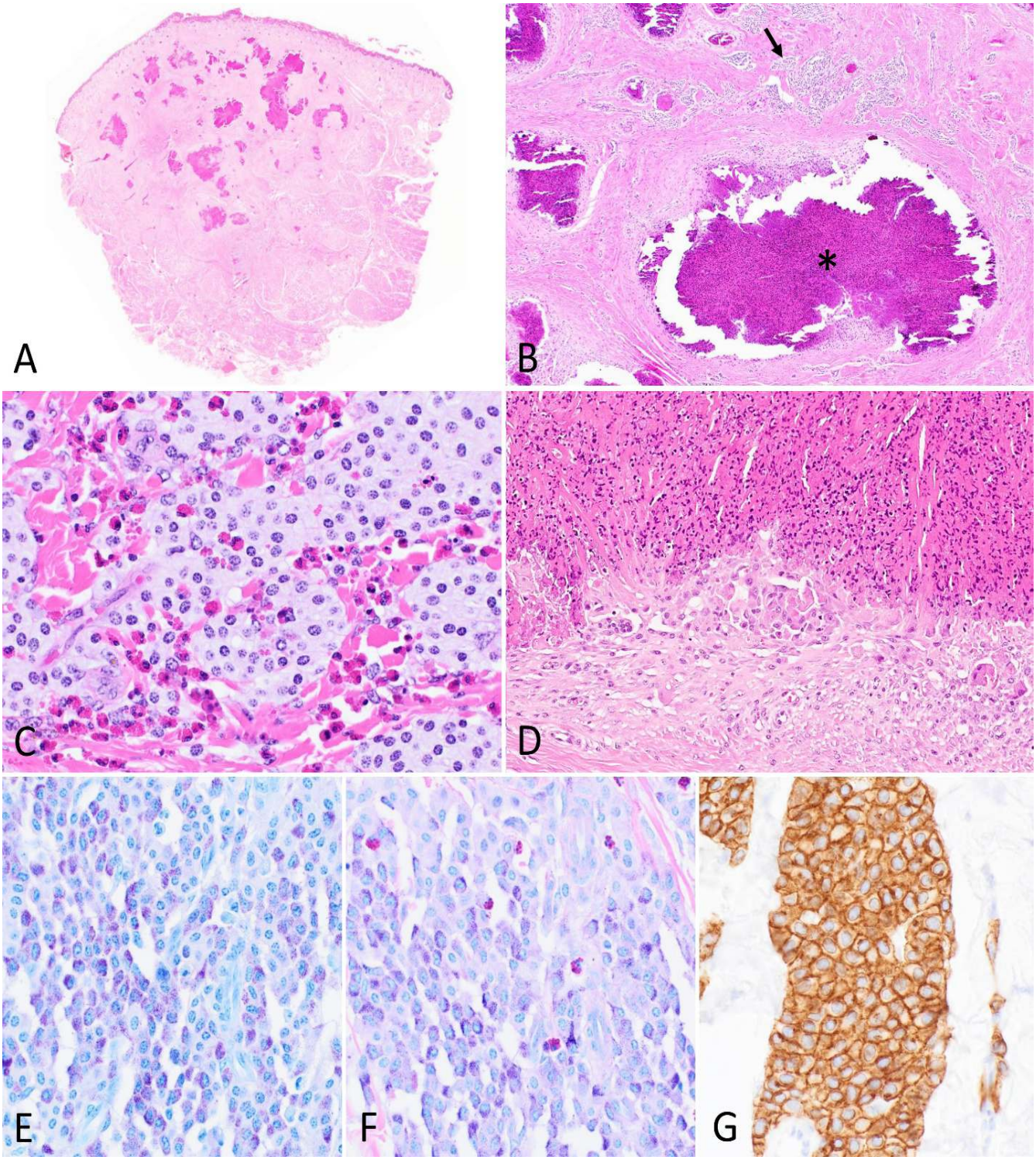

Figure 2. Photomicrographs of the haired skin mass from the left upper lip of an Arabian gelding. (A) Subgross image of the haired skin mass. (B) The dermal mass contains neoplasm (arrow) and multiple eosinophilic granulomas (asterisk) within a variably thickness of fibrovascular stroma. (C) The neoplasm is composed of round cells arranged in nests, or sheets with distinct cell borders and moderate amounts of amphophilic cytoplasm containing fine basophilic granules admixed with eosinophils. (D) Eosinophilic granulomas are composed of central core of degenerated eosinophils mixed with eosinophilic granular debris surrounded by large numbers of macrophages, multinucleated giant cells, and further rimmed by fibroblasts. (E-F) The neoplastic cells contain moderate to abundant amounts of Toluidine blue-(E) and Giemsa-highlighted metachromatic granules (F). The neoplastic cells are immunoreactive with CD117 (C-KIT) (G).

central core of degenerated eosinophils mixed with brightly eosinophilic granular debris surrounded by large numbers of macrophages, multinucleated giant cells, and fewer lymphocytes, plasma cells, and further rimmed by fibroblasts (Figure 2D). Occasionally central necrosis contains fine granular basophilic material (mineralization). The overlying epidermis is moderately thickened with epidermal hyperplasia and parakeratotic hyperkeratosis.

Special stains: In Toluidine blue (Figure 2E) and Giemsa (Figure 2F) stains, the neoplastic cells contain moderate to abundant amounts of metachromatic cytoplasmic granules. No overt bacteria, fungi, or parasites are observed in gram, GMS, PAS, or Acid-fast (Fite's) stains (images not shown).

Immunohistochemistry stains: Approximately 99% of the neoplastic cells have a diffuse strong membranous and weak cytoplasmic immunoreactivity for CD117 (C-KIT) antibody (Figure 2G)

Morphologic diagnosis:

Haired skin (left upper lip mass): Equine cutaneous mast cell tumor.

Comments:

Equine mast cell tumors (MCTs) are uncommon neoplasms, accounting for approximately 2-7% of cutaneous and mucocutaneous tumors in horses (1, 10). Arabian horses and males appear to be overrepresented (7). Equine mast cell tumors (MCTs) have been reported in horses ranging from 3 to 30 years of age, with a mean age of approximately 11 years (1).

Most equine MCTs exhibit benign biological behavior and typically present as slow-growing, solitary, well-demarcated masses confined to the dermis or subcutis (4, 10). They occur most frequently on the head (lips, nostrils, jaw, and periorbital region), limbs, and trunk (4). Although most tumors are cutaneous, MCTs have also been reported in the ocular tissues (conjunctiva, sclera, membrana nictitans, globe, and cornea), respiratory tracts (nasal cavity, nasopharynx, and trachea), tongue, synovium, and tendon (3, 5, 6, 8). Lesions involving the limbs are often firm, immobile, and located adjacent to joints, and chronic lesions may undergo dystrophic mineralization that is radiographically detectable (6, 7). Reported clinicopathologic abnormalities include peripheral eosinophilia and hyperfibrinogenemia (8). Most lesions are nonpainful and nonpruritic, although lameness has occasionally been reported (6).

The etiology of equine MCTs remains unknown. Proposed contributing factors include chronic inflammation, parasitic infections, or autoimmune reactions (4). Concurrent lesions, including sarcoids, eosinophilic granulomas, sebaceous adenomas, collagenolytic granulomas, melanomas, and squamous cell carcinomas, have been reported, and some horses develop multiple MCTs (1).

Histologically, equine MCTs are characterized by multifocal to coalescing aggregates of neoplastic mast cells admixed with variable numbers of eosinophils that efface the dermis and subcutis, with occasional extension into the underlying skeletal muscle (7, 9). Neoplastic mast cells are typically arranged in ribbons, nests, or sheets, and are round to polygonal with abundant eosinophilic to amphophilic cytoplasm containing fine metachromatic granules. Cellular atypia is generally minimal, and mitotic count is usually low (7, 9).

The histologic findings of equine MCTs appears to evolve with lesion chronicity. Early lesions are composed of dense aggregates of neoplastic mast cells, whereas chronic lesions exhibit progressive eosinophilic infiltration, flame figure (collagenolysis), necrosis, eosinophilic granulomatous inflammation, fibrosis, and dystrophic mineralization, with neoplastic mast cells scattered. It has been proposed that neoplastic mast cells release cytokines and proteolytic enzymes that recruit eosinophils (3). Subsequent eosinophil degranulation promotes collagen degeneration and cellular necrosis, triggering eosinophilic granulomas and fibrosis (2, 3). The marked fibroblastic response appears to occur more frequently in horses than in other species. In this present case, no overt bacteria, fungi, or parasites are observed in the gram, GMS, PAS, and Acid-fast (Fite's) stains.

Small biopsy specimens from chronic equine MCTs may contain predominantly fibrous tissue with only rare neoplastic mast cells, making histologic diagnosis challenging (2). Chronic fibrosing lesions may be misinterpreted as calcinosis circumscripta, while lesions with prominent eosinophilic granulomatous inflammatory responses may resemble eosinophilic granuloma, collagenolytic granuloma, pythiosis, onchocerciasis, parasitic eosinophilic granulomatous dermatitis (e.g., habronemiasis), multisystemic eosinophilic epitheliotropic diseases, or foreign body inflammation (2, 10). Although these conditions may share overlapping histologic features, they generally lack the characteristic aggregates or sheets of neoplastic mast cells that support a diagnosis of equine MCT (2, 10).

Special and/or immunohistochemical stains may aid in the identification of neoplastic mast cells. Metachromatic granules in mast cells can be highlighted by Toluidine blue and Giemsa stains. Immunohistochemical detection of the c-kit proto-oncogene (CD117, C-KIT) may also support identification of equine mast cells, as C-KIT protein has been reported to be consistently expressed in these cells (1, 9).

Although the vast majority of equine MCTs exhibit benign biological behavior, occasional cases demonstrate locally aggressive growth, recurrence, regional lymph node metastasis, or multicentric disease involving the skin, subcutis, liver, spleen, and lungs (2, 8). Unlike canine cutaneous MCTs, no validated histologic grading system currently exists to reliably predict biological behavior in equine MCTs. Histologic

features associated with more aggressive behavior include increased mitotic count, moderate to marked anisokaryosis, prominent nucleoli, and variable or increased nuclear-to-cytoplasmic ratios (3). Aberrant C-KIT immunolabeling patterns have also been inconsistently reported in poorly differentiated equine MCTs and the associated aggressive biological behavior (1, 9). Current studies suggest that additional large prospective investigations are required to further validate the prognostic significance of these features (4).

Treatment options for equine MCTs include surgical excision, laser ablation, cryotherapy, intralesional corticosteroid injection, and radiotherapy (4, 7). Surgical excision of cutaneous MCTs is typically curative, and even incomplete excision or biopsy has been reported to result in spontaneous regression in some cases. Although local recurrence is rare, development or progression of mast cell tumors at other sites had been documented in a small proportion of affected horses (7).

References:

1. Clarke L, Simon A, Ehrhart EJ, et al. Histologic characteristics and KIT staining patterns of equine cutaneous mast cell tumors. Vet Pathol. 2014;51(3):560-562.
2. Combarros D, Wilhelmi-Vilarrasa I, Lacroux C, Semin MO, Delverdier M, Grebert M, Trumel C, Cadiergues MC, Lallemand EA. Multinodular malignant cutaneous mast cell tumor in a horse with generalized pruritus and reactive fibrosis: A case report. J Equine Vet Sci. 2020;87:102921.
3. Flores AR, Azinhaga A, Pais E, Faria F, Nunes F, Gartner F, Amorim I. Equine ocular mast cell tumor: histopathological and immunohistochemical description. J Equine Sci. 2017;28(4):149-152.
4. Gordon DL, Schnelle AN, Vieson MD, Slaughter-Mehfoud KM, Martz AL. Pathology in Practice. J Am Vet Med Assoc. 2021 Dec 15;259(S2):1-4.
5. Halse S, Pizzirani S, Parry NM, Burgess KE. Mast cell tumor invading the cornea in a horse. Vet Ophthalmol. 2014;17(3):221-7.
6. Johnston, G.C.A. and Zedler, S.T. (2019), Treatment of an invasive equine mast cell tumour in the extensor carpi radialis by extensive tenomyectomy and local corticosteroid injections. Equine Vet Educ, 31: e34-e38.
7. Mair TS, Krudewig C. Mast cell tumors (mastocytosis) in the horse: a review of the literature and report of 11 cases. Equine Vet Educ. 2008;20(4):177-182.
8. Millward LM, Hamberg A, Mathews J, et al. Multicentric mast cell tumors in a horse. Vet Clin Pathol. 2010;39(3):365-370.
9. Ressel L, Ward S, Kipar A. Equine cutaneous mast cell tumours exhibit variable differentiation, proliferation activity and KIT expression. J Comp Pathol. 2015;153(4):236-243.
10. Scott DW, Miller WH. Equine Dermatology. 2nd ed. Maryland Heights, MO: