Braz J Vet Pathol, 2026, vol. 19, Suppl. 1, e019S111
DOI: https://doi.org/10.24070/bjvp.1983-0246.019S111

BJVP
Brazilian Journal of Veterinary Pathology
ISSN 1983-0246

Diagnostic Exercise
From the Latin Comparative Pathology Group and the Davis-Thompson Foundation

Pancreatic carcinoma and carcinomatosis in a hen

Krysta McMahan, Bianca Santana de Cecco
Pathobiology and Population Medicine, College of Veterinary Medicine, Mississippi State University.

***Corresponding author:** bs2489@msstate.edu

History: A 3-year-old Buff-Orpington hen was submitted to postmortem examination after the owner found the animal unable to walk, drink, or eat. The owner reported that the chicken had a crooked neck since it was adopted (over 2 years ago). He took the animal to a veterinary clinic where a parasitology test (fecal flotation) was performed, and it yielded negative results. The chicken died before the clinical examination was completed.

Necropsy findings: A 3-year-old chicken with a body condition score of 1/5 (emaciated) and severe autolysis was submitted for postmortem examination. There was a moderate amount of brown to yellow granular feces adhered to the cloaca and surrounding feathers. The coelomic cavity contained approximately 30 ml of green-tinged opaque fluid. The small and large intestines were firmly adhered to each other and could not be linearized (Fig. 1). The serosa of the intestines was expanded by multiple 0.2 to 0.6 cm firm, tan to white nodules. Multifocally, the intestinal lumen was diminished, and there were areas of almost complete obstruction (strictures). The pancreatic tissue could not be identified. No other significant abnormalities were observed in the remaining organs, including the cervical region, the oviduct, and the ovary. Samples of the nodules (Fig. 2) and small intestine (Fig. 3) were collected for histopathology.



Figure 1. Photograph of a 3-year-old hen with emaciation and ascites. The intestinal loops are adhered to each other, and there are occasionally raised, firm tan nodules in the serosa

Follow-up questions:

- *Morphologic diagnosis:*
- *Differential diagnosis*

Histologic description:

Pancreas (Fig. 2): Infiltrating and obliterating the pancreatic parenchyma was a poorly demarcated, non-encapsulated, highly invasive, and cellular neoplasm composed of

**The Diagnostic Exercises are an initiative of the Latin Comparative Pathology Group (LCPG), the Latin American subdivision of The Davis-Thompson Foundation (DTF). These exercises are contributed by members and non-members from any country of residence. Consider submitting an exercise! A final document containing this material with answers and a brief discussion will https://davisthompsonfoundation.org/diagnostic-exercise/*

Editor-in-chief for this Diagnostic Exercise: *Claudio Barros*
Associate Editor for this Diagnostic Exercise: *Andréia Vielmo*

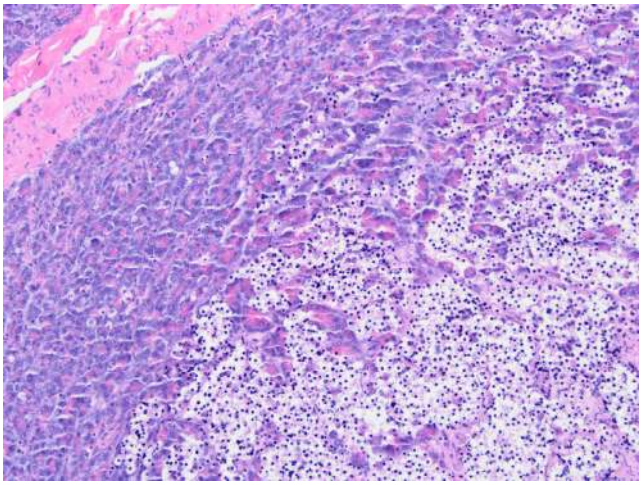

Figure 2. Photomicrograph of the pancreas. The pancreatic parenchyma was obliterated by a poorly demarcated, non-encapsulated, highly invasive, and cellular neoplasm composed of epithelial cells arranged in tubules and loosely packed aggregates, interspersed and surrounded by scirrhous stroma. H&E 50 µm

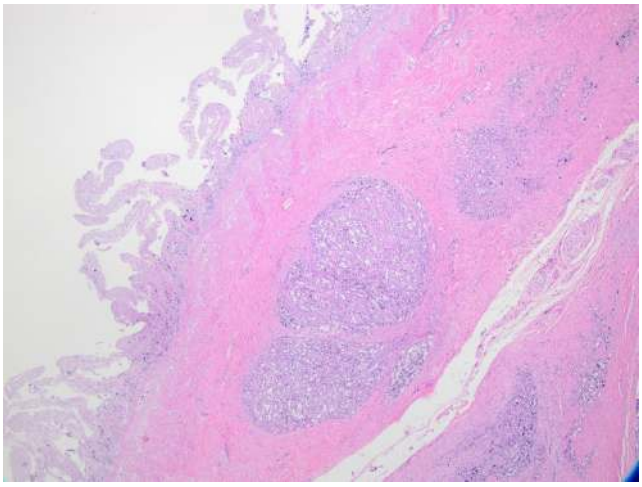

Figure 3. Photomicrograph of the small intestine. The neoplastic cells broadly invade the intestinal serosa (carcinomatosis). H&E 200 µm

epithelial cells arranged in tubules and loosely packed aggregates, interspersed and surrounded by scirrhous stroma. The neoplastic cells were cuboidal to polygonal with moderate, clear basophilic to vacuolated cytoplasm, a round nucleus with dense chromatin, and an inconspicuous nucleolus. Anisocytosis and anisokaryosis were moderate to marked, and there were rare mitotic figures. The neoplasm was multifocally disrupted by areas of necrosis and mineralization. Neoplastic cells were observed in occasional blood vessels.

Small intestine (Fig. 3): The muscular and serosal layers of the intestines were multifocally expanded by neoplastic cells similar to those described in the pancreatic parenchyma (consistent with carcinomatosis).

Morphologic diagnosis:

1. Pancreatic adenocarcinoma with carcinomatosis

Differential diagnosis:

- Oviduct/ovary adenocarcinoma
- Intestinal carcinoma

Comments:

Pancreatic tumors in chickens are rare, and in other species like dogs, cats, and humans, the neoplasm is associated with rapid progression, poor prognosis, and a high metastatic rate. Pancreatic carcinomas are usually infiltrative, with poorly defined edges, frequent loss of normal pancreas architecture, and invasion of adjacent organs. Adhesions connecting the intestines and other celomatic organs are commonly described. In our case, multiple masses were observed in the serosa of the intestines, while the pancreas could not be identified grossly. The observed areas of stricture were caused by the expansion of the tumor, restricted to the serosa of the intestines, which is consistent with carcinomatosis. Carcinomatosis is the seeding of the thoraco-coelomic cavity with neoplastic cells that subsequently proliferate, and was described in all cases of intestinal adenocarcinoma and oviductal carcinoma in avian species, in a case series.

Pancreatic carcinomas originate from ductal or acinar epithelium and are formed by poorly differentiated epithelial cells forming acini, nests, and trabeculae, which efface normal pancreatic tissue and frequently invade adjacent tissue. Few cases of pancreatic adenocarcinomas have been described in poultry. Metastatic carcinoma is uncommon in chickens and is typically associated with neoplasia of ovary or oviduct. In our case, we were able to differentiate the origin of the tumor based on histology, considering the absence of neoplastic cells in the ovary, oviduct, or mucosa of the intestine, making it unlikely to originate from the reproductive tract or intestinal epithelium.

Common clinical signs of pancreatic neoplasms include weight loss, anorexia, vomiting, lethargy, diarrhea, ascites, and palpable abdominal mass. In a case series, the authors describe coelomic distension and ascites as the primary signs of disease in the affected animals. In the case reported here, the chicken was emaciated, had ascites, and exhibited anorexia and difficulty walking before examination. We associate the difficulty of walking with weakness due to poor body condition and anorexia, since there were no other gross or microscopic lesions in the limbs. Although hypoglycemia could also be related to weakness, glucose was not assessed in this case. Together with literature, this case suggests that neoplastic processes,

including pancreatic adenocarcinomas, should be included as differentials when chickens present coelomic distention, with or without ascites. Also, clinicians must consider that non-specific clinical signs such as lethargy, inappetence, and weight loss can be frequently observed in neoplastic processes in birds.

References:

1. Abdul-Aziz TA. Poorly differentiated pancreatic adenocarcinoma in a chicken. Vet Rec 1995; 137(16): 408.
2. Aydogan A, Avcı H, Birincioğlu B, et al. Pancreatic exocrine carcinoma in a lohmann brown chicken. J Hell Vet Med Soc 2024;75: 8121–8124.
3. Schmidt RE, Struthers JD, Phalen DN. Pathology of pet and aviary birds. Oxford: Wiley-Blackwell; 2024.
4. Ritchie BW, Harrison GJ, Harrison LR. Avian medicine: principles and application. Zoological Education Network; 1994.
5. Sutherland M, Ploeg R, Sacks P, et al. Avian Lumps and Bumps: Clinical and Histological Findings Associated with Avian Tumours, a Preliminary Review. Avian Dis 2016:37–45.