Braz J Vet Pathol, 2026, vol. 19, Suppl. 1, e019S112
DOI: https://doi.org/10.24070/bjvp.1983-0246.019S112

BJVP
Brazilian Journal of Veterinary Pathology
ISSN 1983-0246

Diagnostic Exercise
From the Latin Comparative Pathology Group and the Davis-Thompson Foundation

Malignant ovarian granular cell tumor in a Doberman Pinscher dog

Sahar Abdelrahman and Ji-Hang Yin[1]

[1]Kansas Veterinary Diagnostic Laboratory, College of Veterinary Medicine / Diagnostic Medicine / Pathobiology, Kansas State University

***Corresponding author:** jihangyin@vet.k-state.edu (jihangyin@ksu.edu)

History: A 6-year-old spayed female Doberman Pinscher dog was presented for evaluation of an open pyometra that had been medically managed with amoxicillin/clavulanate and enrofloxacin (Baytril). The purulent discharge initially resolved with antibiotics treatment; however, several weeks later, recurrent purulent discharge with concurrent hemorrhagic vulvar drainage was noted. An ovariohysterectomy was performed and an enlarged right ovarian mass, weighing 226.7 g, was observed and submitted for histopathologic evaluation. The left ovary was reported grossly unremarkable.

Gross findings: The submitted formalin-fixed right ovarian mass measured approximately 15-cm× 10-cm × 8-cm, and was firm, tan to dark red, and multinodular (nodules ranging from 0.5 to 5-cm in diameter) with a smooth surface. On cut surface, the mass was multilobulated, with tan to yellow solid areas, multiple variably sized cystic cavities, and multifocal areas of hemorrhage and necrosis (Figure 1). The cystic cavities contained transparent colorless fluid.

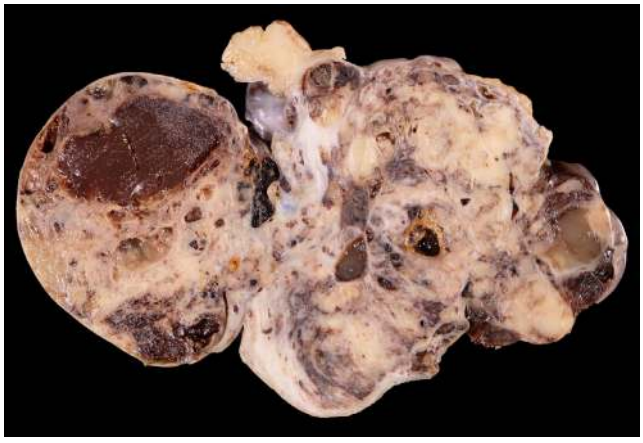

Figure 1. Photograph of the cut surface of the formalin-fixed right ovarian mass from a 6-year-old spayed female Doberman Pinscher dog. The ovarian mass was multinodular and multilobulated containing both solid areas and cystic cavities in addition to multifocal hemorrhagic and necrotic foci.

**The Diagnostic Exercises are an initiative of the Latin Comparative Pathology Group (LCPG), the Latin American subdivision of The Davis-Thompson Foundation (DTF). These exercises are contributed by members and non-members from any country of residence. Consider submitting an exercise! A final document containing this material with answers and a brief discussion will be posted on the DTF website.*
https://davisthompsonfoundation.org/diagnostic-exercise/

Editor-in-chief for this Diagnostic Exercise: *Claudio Barros*
Associate Editor for this Diagnostic Exercise: *Andréia Vielmo*

Braz J Vet Pathol, 2026, vol. 19, Suppl. 1, e019S112
DOI: https://doi.org/10.24070/bjvp.1983-0246.019S112

Histologic description:

Right ovarian mass: Markedly expanding and effacing the ovary, and compressing the remaining ovarian tissues to the periphery is an unencapsulated, well-demarcated, multilobulated, densely cellular neoplasm (Figure 2A), composed of polygonal cells arranged in solid sheets, islands, trabeculae, and micro/macrofollicular structures within a moderate amount of fibrovascular stroma and further separated by a thick fibrous connective tissue (Figure 2B-C). Frequently, the neoplastic cells palisade along the fibrovascular stroma (Figure 2C, arrow) or form rosette/gland-like structures that surround central eosinophilic proteinaceous material (Call-Exner bodies)(Figure 2C, inset). Neoplastic cells have variably

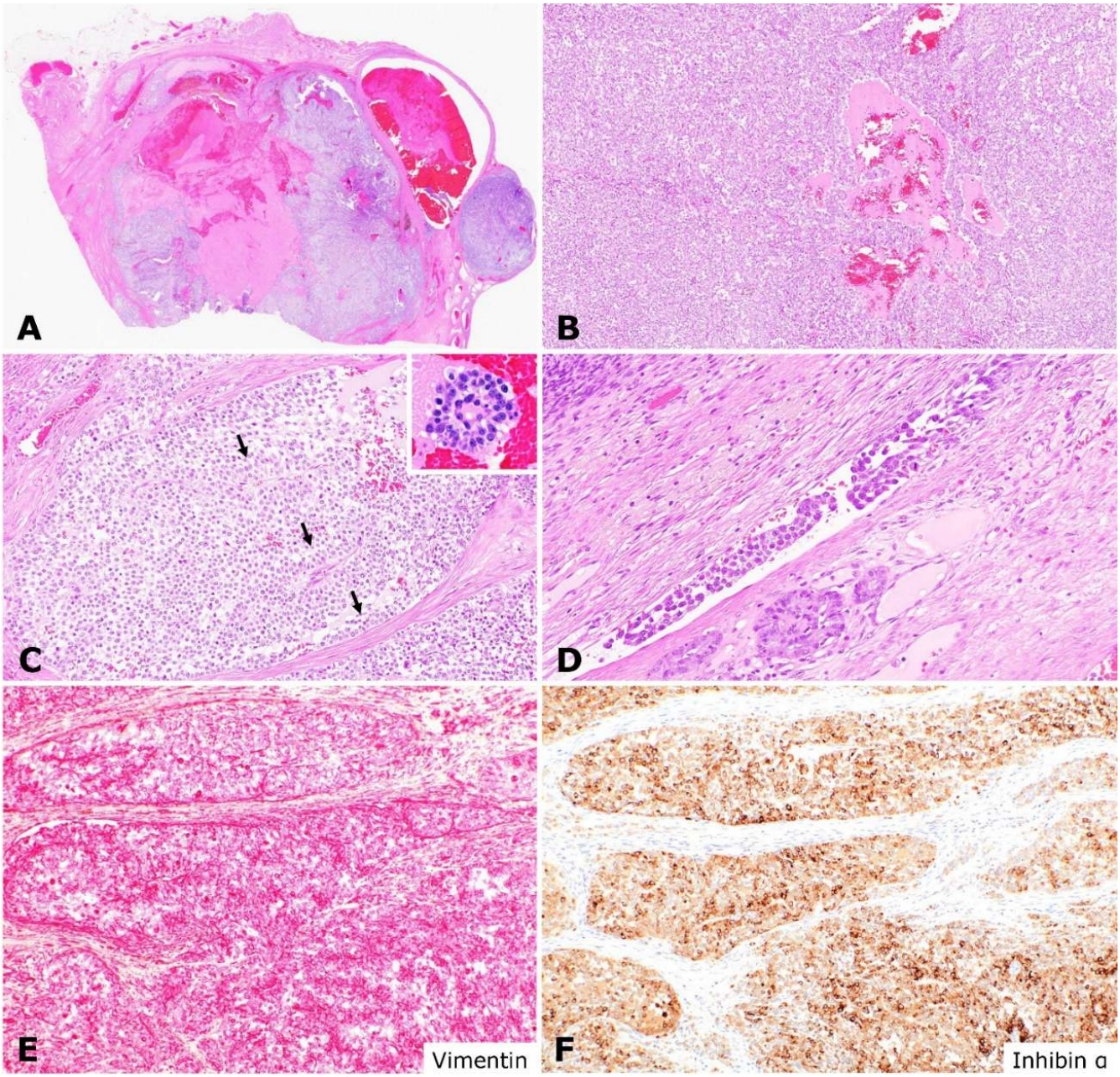

Figure 2. Photographs of the right ovarian mass. The right ovary is markedly expanded and effaced by an unencapsulated, well-demarcated, multilobulated, densely cellular neoplasm with multifocal hemorrhagic and necrotic foci (A). The neoplasm is composed of polygonal cells arranged in solid sheet, micro-and macrofollicular structures (B), or trabeculae (C). The neoplastic cells frequently palisade along the fibrovascular stroma (C, arrow), or form rosette/gland-like structures that surround central eosinophilic proteinaceous material (Call-Exner bodies)(C, inset). Neoplastic emboli are in few blood vessels (D). The neoplastic cells are immunoreactive with vimentin (E) and inhibin α (F) antibodies.

Braz J Vet Pathol, 2026, vol. 19, Suppl. 1, e019S112
DOI: https://doi.org/10.24070/bjvp.1983-0246.019S112

distinct cell borders, moderate to abundant amounts of pale eosinophilic to eosinophilic cytoplasm. Nuclei are round to oval with finely stippled chromatin and 1-2 small nucleoli. Anisocytosis and anisokaryosis are moderate. Thirty-two mitotic figures are in ten standardized 400x fields (2.37 mm^2). Few blood vessels contain neoplastic emboli (Figure 2D). Approximately 95% of the neoplastic cells have a diffuse strong cytoplasmic immunoreactivity for vimentin (Figure 2E) and inhibin α (Figure 2F) antibodies. The neoplasm contains multifocal areas of hemorrhage and necrosis. Within the stroma are aggregates of hemosiderin-laden macrophages and/or hematoidin.

Morphologic diagnosis:

Malignant ovarian granulosa cell tumor with lymphovascular invasion.

Comments:

Ovarian neoplasms are classified into three broad categories based on embryonic origin: tumors of the sex cords and gonadal stroma, tumors of the surface coelomic epithelium, and tumors of germ cells (1, 3). Sex cord–stromal tumors are among the most common ovarian neoplasms in domestic animals and are thought to arise from follicular granulosa cells, theca cells, or their luteinized derivatives. Within this group, granulosa cell tumor has been reported the most common sex cord–stromal tumor in animals (1, 3).

Granulosa cell tumors (GCTs) have been described in several animal species, including dogs, horses, cattle, and laboratory animals such as non-human primates, mice, and rats (1, 2, 3). In dogs, GCTs are most frequently observed in middle-aged with variable breeds documented (5).

Ovarian sex cord–stromal tumors are capable of producing a variable mixture of female and male sex hormones, which can profoundly influence the reproductive behavior of affected animals and induce effects in extra-ovarian tissues (1). For example, androgens may be converted to estrogens within follicular granulosa cells. In addition, granulosa cells produce the peptide hormone inhibin, which suppresses follicle-stimulating hormone (FSH) secretion (1). These hormonal alterations may result in contralateral ovarian atrophy, persistent estrus or proestrus, hyperestrogenism with associated dermatologic changes (alopecia), and hematopoietic system suppression with nonregenerative anemia, leukopenia, thrombocytopenia, and hemorrhagic diathesis (1, 7). Clinical presentation of canine GCTs is variable; in some cases, ovarian lesions are incidental findings without overt clinical signs such as abdominal distension, pain, lethargy, vomiting, polyuria, or polydipsia; whereas in other cases, signs of hyperestrogenism are evident and lead to abnormal reproductive and behavioral manifestations in addition to extra-ovarian changes, including prolonged or irregular estrous cycles, vulvar and mammary enlargement, vaginal discharge, cystic endometrial hyperplasia, pyometra, masculinization, alopecia, or bone marrow suppression (1, 3, 7).

Canine GCTs are commonly unilateral and variable in size, often presenting with a smooth surface and solid to cystic appearance on cut sections (3). Histologically, the most common pattern is solid, followed by mixed solid and cystic, with purely cystic forms being less frequent (1, 3). Histologically, neoplastic granulosa cells resemble their normal follicular counterparts and may be arranged in a variety of patterns, including solid sheets, cords, trabeculae, nests, and tubular, microfollicular, or macrofollicular structures (1, 3). Some tumors exhibit gland-like or rosette-like arrangements of abortive follicles, occasionally surrounding central eosinophilic proteinaceous material known as Call–Exner bodies (1, 3). Neoplastic cells may also demonstrate peripheral palisading along a fibrovascular stroma (1, 3). Granulosa–theca cell tumors can occur as a mixture of phenotypes in which granulosa cells and theca cells coexist within the same neoplasm (1).

Several immunohistochemical markers have been described in the literature for the diagnosis of canine GCTs, which have been reported to exhibit immunoreactivity for vimentin, inhibin-α, anti-Müllerian hormone, cytokeratin (AE1/AE3), or Melan-A antibodies (1, 6, 8, 9). In this present case, approximately 95% of the neoplastic granulosa cells have strong immunoreactivity for vimentin and inhibin-α. Approximately 50% of the neoplastic granulosa cells are weakly to moderately immunoreactive with cytokeratin (AE1/AE3), and Melan-A antibodies (data not shown). Anti-Müllerian hormone marker was not performed in this case. Vimentin is typically detected in granulosa cells of normal ovarian follicles and in GCTs, with expression generally remaining consistent throughout follicular development (8). Inhibin α, a glycoprotein expressed by granulosa cells, has been considered a sensitive and specific immunohistochemical marker for GCTs (1, 6, 8). Anti-Müllerian hormone, a homodimeric protein expressed by granulosa cells of preantral and small antral follicles in the postnatal ovary, has been reported a useful marker for canine GCTs (6). Cytokeratin AE1/AE3 expression is variable, strongly expressed in granulosa cells of primary and secondary follicles, whereas staining decreases in Graafian follicles (9). Melan-A has been used to detect steroid-producing cells (adrenal cortical cells, granulosa cells, and Leydig cells), and has shown inconsistent labeling in canine GCTs (1, 8).

GCTs are generally considered benign neoplasms that rarely metastasize (10). Feline and bovine GCTs are considered to have more malignant potential compared with those in dogs (1). Approximately 20% of canine GCTs are reported to have metastatic potential, with reported sites of metastasis including the sublumbar lymph nodes, liver, lungs, pancreas, broad ligament, and peritoneum, with peritoneal carcinomatosis also described (5, 10). Definitive treatment for benign

Braz J Vet Pathol, 2026, vol. 19, Suppl. 1, e019S112
DOI: https://doi.org/10.24070/bjvp.1983-0246.019S112

GCTs is ovariohysterectomy (7). One study demonstrated that the median survival time of dogs with GCTs without lymphovascular invasion was 1474 days, which appeared longer than in dogs with dysgerminoma and adenocarcinoma. However, little information is available on the prognosis of dogs with malignant ovarian tumors (4).

In the present case, we describe a 6-year-old spayed female Doberman Pinscher dog diagnosed with a malignant ovarian granulosa cell tumor that clinically presented with pyometra, purulent discharge, and hemorrhagic vulvar drainage, with a unilateral ovarian mass identified at ovariohysterectomy. Histopathology confirmed an ovarian granulosa cell tumor, with the neoplastic cells immunolabeled for vimentin and inhibin-α antibodies and evidence of lymphovascular invasion.

References:

1. Agnew DW, MacLachlan NJ. Tumors of the genital system. In: Meuten DJ, ed. Tumors in Domestic Animals. 5th ed. Ames, IA: John Wiley & Sons, Inc.; 2017:690-698.
2. Barthold SW, Griffey SM, Percy DH. Pathology of Laboratory Rodents and Rabbits. 4th ed. Ames, IA: Blackwell Publishing; 2016:115, 210, 251.
3. Foster RA Premanandan C. Female genital system. In: Maxie MG, ed. Jubb, Kennedy, and Palmer's Pathology of Domestic Animals. Vol 3. 7th ed. St. Louis: Elsevier; 2025:383-5.
4. Goto S, Iwasaki R, Sakai H, Mori T. A retrospective analysis on the outcome of 18 dogs with malignant ovarian tumours. Vet Comp Oncol 2021;19(3):442-450.
5. Matos ACHDS, Leite JDS, Consalter A, de Mello MFV, de Lourdes Gonçalves Ferreira M, Fosenca ABM, Ferreira AMR. Histopathological findings in the early diagnosis of granulosa cell tumour in bitches. Reprod Domest Anim 2019;54(6):828-834.
6. Nelissen S, Miller AD. Comparison of anti-Müllerian hormone and inhibin immunolabeling in canine and equine granulosa cell tumors. J Vet Diagn Invest 2022;34(6):1027-1031.
7. Pluhar GE, Memon MA, Wheaton LG. Granulosa cell tumor in an ovariohysterectomized dog. J Am Vet Med Assoc. 1995;207(8):1063-5.
8. Ramos-Vara JA, Beissenherz ME, Miller MA, Johnson GC, Kreeger JM, Pace LW, Turk JR, Turnquist SE, Watson GL, Yamini B. Immunoreactivity of A103, an antibody to Melan A, in canine steroid-producing tissues and their tumors. J Vet Diagn Invest 2001;13(4):328-32.
9. Riccardi E, Grieco V, Verganti S, Finazzi M. Immunohistochemical diagnosis of canine ovarian epithelial and granulosa cell tumors. J Vet Diagn Invest 2007;19(4):431-5.
10. Tanaka T, Tomihari M, Hasegawa T. Long-term outcome in a dog with a unilateral ovarian granulosa cell tumour with a concurrent non-neoplastic abdominal effusion following ovariohysterectomy. Vet Rec Case Rep 2026;14:e70252.