Braz J Vet Pathol, 2026, vol. 19, Suppl. 1, e019S113
DOI: https://doi.org/10.24070/bjvp.1983-0246.019S113

BJVP
Brazilian Journal of Veterinary Pathology
ISSN 1983-0246

Diagnostic Exercise
From the Latin Comparative Pathology Group and the Davis-Thompson Foundation

Senna obtusifolia poisoning in cattle

Luana Dias do Nascimento[1], João Paulo da Silva Cavasani[1], Larissa Sabino[1], Marcos de Almeida Souza[1], Caroline Argenta Pescador[1], Edson Moleta Colodel[1], Fernando Henrique Furlan*[1].

[1]Veterinary Pathology Laboratory, Veterinary Hospital, Federal University Of Mato Grosso, Brazil.

***Corresponding author:** fernando.furlan@ufmt.br

Texto History: One herd with 300 cattle was kept in a degraded pasture of *Brachiaria Brizantha* infested with weeds by 20 days until presenting with the early clinical signs. Close observation of the herd revealed some cattle with reluctance to move and muscular weakness and some which would go down when forced to move rapidly or for long distances. Fifty-two cattle were found recumbent and of these, 25 died. Recumbent cattle appeared alert and would eat and drink until late in the clinical course.

Necropsy findings: The skeletal muscles showed varying degrees of pale discoloration of a portion of a muscle (Figure 1), a whole muscle (Figure 2), or several muscles. Muscles of the hindlimbs and *L. dorsi* were most frequently affected.

Figure 3 and 4*Senna obtusifolia* poisoning in cattle, Skeletal muscular fibers showing swelling and sarcoplasm vacuolation, loss of striation, fragmentation and floccular degeneration.

Follow-up questions:

- *Microscopic description*
- *Morphologic diagnosis:*
- *Etiology:*
- *Differential diagnosis:*

Microscopic Description:

Skeletal muscle: Extensive areas of monophasic hyaline myodegeneration and coagulative necrosis characterized by sarcoplasm loss of cross-striation or fragmentation, swelling, and vacuolation. Additionally, there is floccular degeneration and loss of the sarcoplasm through ruptured sarcolemma membranes. Occasionally, macrophages and lymphocytes accumulated within and around degenerated fibers.

Morphologic Diagnosis:

Skeletal muscle: severe, multifocal, monophasic skeletal myodegeneration and myonecrosis.

Etiology: *Senna obtusifolia* poisoning

Discussion:

A large group of chemical and biological agents can cause skeletal muscle degeneration and necrosis in laboratory

*The Diagnostic Exercises are an initiative of the Latin Comparative Pathology Group (LCPG), the Latin American subdivision of The Davis-Thompson Foundation (DTF). These exercises are contributed by members and non-members from any country of residence. Consider submitting an exercise! A final document containing this material with answers and a brief discussion will https://davisthompsonfoundation.org/diagnostic-exercise/

Editor-in-chief for this Diagnostic Exercise: *Claudio Barros*
Associate Editor for this Diagnostic Exercise: *Andrea Vielmo*

animals and humans; however, in veterinary medicine, naturally occurring toxic myopathies are largely associated with the ingestion of ionophores and plant toxins. In cattle, the most frequent causes of toxic myopathy include the coffee senna plants (*Senna occidentalis* and *Senna obtusifolia*) and ionophores. Other toxic agents, such as gossypol, a toxic compound present in cottonseed, and plants such as *Ageratina altissima*, *Isocoma pluriflora*, *Laburnum anagyroides*, *Lupinus* spp., and *Thermopsis montana*, have also been implicated (1–6). In Brazil, *S. occidentalis* was historically considered the primary plant associated with toxic myopathy in cattle; however, outbreaks of poisoning caused by the ingestion of *S. obtusifolia* have also been reported (3–6).

Senna occidentalis and *S. obtusifolia* belong to the family Fabaceae, subfamily Caesalpinioideae. Both are shrubs native to the Americas with a pantropical distribution and are commonly found as invasive plants in pastures and crops, including soybean, maize, and sorghum (6). Experimental studies have demonstrated the toxicity of different plant parts of *S. occidentalis*, including leaves, stems, pods, and seeds (3–4,6). Similarly, leaves, stems, and green pods of *S. obtusifolia* have been shown to be toxic to cattle under experimental conditions (5–6). Some studies suggest that *S. occidentalis* may be more toxic than *S. obtusifolia*, although toxicity can vary according to the plant part, developmental stage, and amount ingested (2,4).

In field conditions, ingestion of *Senna* spp. may occur when good-quality forage is scarce and these plants are abundant in pastures. Such conditions have been reported in outbreaks of *S. obtusifolia* poisoning in cattle (5–6). Other circumstances that may favor ingestion include high stocking rates in paddocks heavily infested with *S. obtusifolia* and the inadvertent inclusion of the plant in green-chopped forage (2,5–6). Similar management and environmental conditions have also been associated with field outbreaks of *S. occidentalis* poisoning (2–4,6).

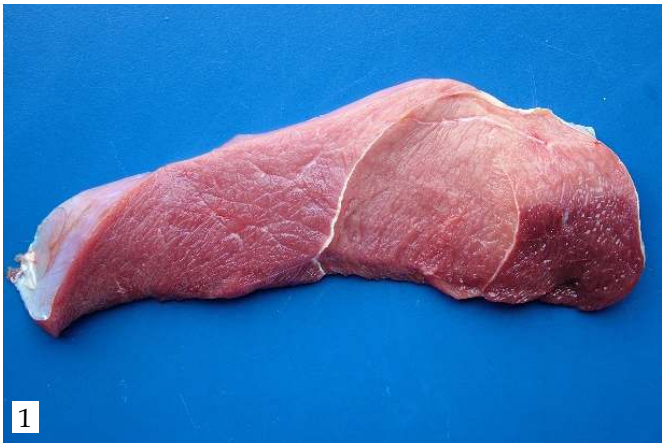



Figure 1 and 2.. *Senna obtusifolia* poisoning in cattle. Skeletal muscles sowing pale discoloration of a portion of a muscle (1) or a whole muscle (2).

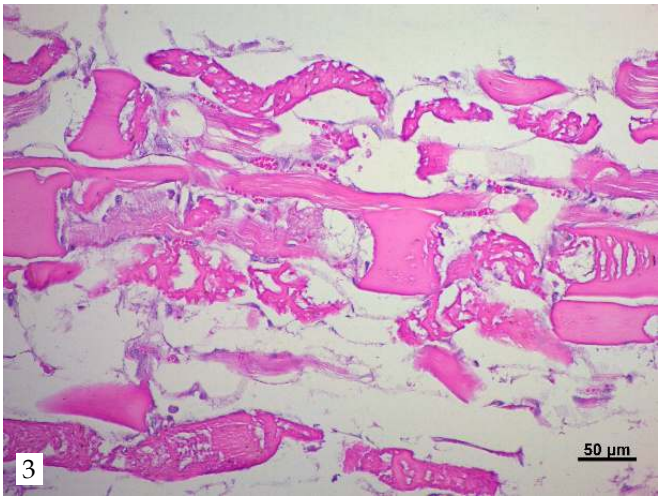

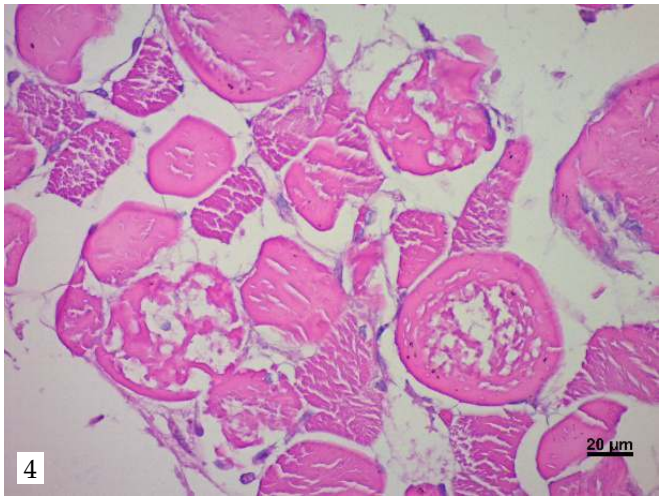

Figure 3 and 4. ***Senna obtusifolia*** poisoning in cattle, Skeletal muscular fibers showing swelling and sarcoplasm vacuolation, loss of striation, fragmentation and floccular degeneration. Note within and around degenerated fibers some macrophages and lymphocytes (asterisks).

Several studies have demonstrated the cathartic and myotoxic effects of these two species in livestock (3,5). Diarrhea is a common clinical sign during the early stages of poisoning by *S. obtusifolia* and *S. occidentalis* and has been attributed to the cathartic effects of anthraquinone glycosides present in these plants (2–6). Other characteristic clinical signs include muscle weakness, motor incoordination, and reluctance to move, which may progress to recumbency and death.

The primary lesions are observed in skeletal muscles and are characterized grossly by pale, discolored areas. Histologically, segmental coagulative necrosis of skeletal muscle fibers is observed, most frequently affecting the muscles of the hindquarters and the *longissimus dorsi* (2–6). These lesions may result from mitochondrial injury and impaired mitochondrial metabolism. The myotoxic compounds of *Senna* spp. are water-soluble, although their identity has not been fully established. Anthraquinones isolated from *Senna* spp. can impair mitochondrial metabolism and may contribute to the myotoxic effects of *S. obtusifolia* and *S. occidentalis*. This hypothesis is supported by evidence of mitochondrial damage and possible uncoupling of oxidative phosphorylation in experimental *S. occidentalis* intoxication (7–9).

Hepatic lesions have also been reported in cattle with *Senna* spp. poisoning, including hepatocellular vacuolation, individual hepatocellular necrosis, and centrilobular necrosis. Centrilobular hepatic necrosis has been associated with the ingestion of large amounts of the plant (5–6). The mechanism underlying hepatic injury may be related to the same mitochondrial dysfunction implicated in skeletal muscle injury, as affected hepatocytes exhibit mitochondrial alterations and impaired mitochondrial function similar to those described in skeletal muscle. These findings suggest that a common toxic principle may contribute to both hepatic and muscular injury, with the severity of lesions potentially depending on the amount of plant material ingested (9).

Dark or black discoloration of the urine may occur and is associated with myoglobin released from damaged skeletal muscle into the circulation and subsequently excreted by the kidneys. Myoglobinuria is frequently reported in *Senna* spp. poisoning, and some cases have also been associated with nephrosis. Renal lesions have been attributed to myoglobin released following skeletal muscle injury (3–6). Although hemoglobin and myoglobin are not considered primary nephrotoxins, both can contribute to renal injury through mechanisms including hypotension and direct tubular injury (10).

The differential diagnoses for *Senna* spp. poisoning in cattle should primarily include other myotoxic plant poisonings, ionophore toxicosis, and nutritional myopathy (white muscle disease) associated with vitamin E and selenium deficiency. Because of the similarity in clinical and pathological findings, the diagnosis of myotoxic plant poisoning should be supported by identification of the suspected plant in the pasture or other sources of feed. In ionophore toxicosis, despite similarities in skeletal muscle lesions, clinical disease is often characterized by cardiac involvement and congestive heart failure. Nutritional myopathy primarily affects young animals and may be associated with mineralization of skeletal muscle fibers. In addition, *Senna* spp. poisoning generally causes less severe cardiac injury than ionophore toxicosis (1–6).

References:

1 Cooper BJ, Valentine BA. Muscle and tendon. In: Maxie MG, ed. *Jubb, Kennedy & Palmer's Pathology of Domestic Animals: Volume 1*. 6th ed. St. Louis, MO: Elsevier; 2025:164-249
2 Burrows GE, Tyrl RJ. *Toxic plants of North America*. 2. Ed. Ames:Wiley Blackwell; 2013:1383p.
3 Barros CSL, Pilati C, Andujar MB. Et al. Intoxicação por *Cassia occidentalis* (Leg. Caesalpinoideae) em bovinos. *Pesq Vet Bras.* 1990;10(3/4):47-58.
4 Carmo PMS, Irigoyen LF, Lucena RB, et al. Spontaneous coffee *Senna* poisoning in cattle: Report on 16 outbreaks. *Pesq Vet Bras.* 1990;31(2):139-146.
5 Furlan FH, Zanata C, Damasceno ED, et al. Toxic Myopathy and acute hepatic necrosis in cattle caused by ingestion of Senna obtusifolia (sicklepod; coffesenna) in Brazil. *Toxicon*. 2014;92:24-30.
6 Tokarnia CH, Brito MF, Barbosa JD et al. *Plantas tóxicas do Brasil para animais de produção*, 2 ed. Rio de Janeiro, RJ:Editora Heliantus; 2012:586p.
7 Lewis DC, Shibamoto T. Effects of *Cassia obtusifolia* (sicklepod) extracts and anthraquinones on muscle mitochondrial function. *Toxicon.* 1989;27(5):519529.
8 Calore EE, Cavaliere MJ, Haraguchi M. et al. Experimental mitochondrial myopathy induced by chronic intoxication by *Senna occidentalis* seeds. *J. Neurol. Sci.* 1997;146(1):1-6.
9 Graziano MJ, Flory W, Seger, CL, Herbert CD. Effects of a *Cassia occidentalis* extract in the domestic chicken (*Gallus domesticus*). *Am J Vet Res.* 1983;44:1238–1244.
10 Cianciolo RE, Mohr FC. Urinary System. In: Maxie MG, ed. *Jubb, Kennedy & Palmer's Pathology of Domestic Animals: Volume 1*. 6th ed. St. Louis, MO: Elsevier; 2016:377-464.