Braz J Vet Pathol, 2026, vol. 19, Suppl. 1, e019S114
DOI: https://doi.org/10.24070/bjvp.1983-0246.019S114

BJVP
Brazilian Journal of Veterinary Pathology
ISSN 1983-0246

Diagnostic Exercise
From the Latin Comparative Pathology Group and the Davis-Thompson Foundation

Perinephric pseudocyst

Cecilia Degiovanni[1]
[1]Utah Veterinary Diagnostic Laboratory, College of Veterinary Medicine, Utah State University.

Corresponding author: cecilia.degiovanni@usu.edu

History: An 8-year-old female domestic shorthair cat was referred to a veterinary clinic due to a history of lethargy and anorexia. An abdominal ultrasound revealed a cyst in the left kidney. Approximately 50 mL of pink, turbid fluid was removed from the cyst. The following day, 50 mL of the same fluid was removed. Nephrectomy was performed, and the kidney with the cyst was submitted for histopathology.

Gross findings: The kidney was small and firm, with a focal cortical indentation. A cyst containing gelatinous material and blood was attached to the kidney (Figure 1).



Figure 1. The kidney is small and firm, with a focal cortical indentation. A cyst containing gelatinous material and blood is attached to the kidney.

Microscopic findings:

Kidney: Clusters of densely packed erythrocytes, multiple aggregates of fibrin, and proteinaceous fluid severely distend the space between the renal capsule and the visceral peritoneum (Figure 2). The capsular surface is uneven, dipping inward at the site of multiple chronic infarcts (Figure 3). At sites of infarction, tubules are severely reduced

Exercises are an initiative of the Latin Comparative Pathology Group (LCPG). Members and non-members from any country of residence contribute these exercises. Consider submitting an exercise! A final document containing this material, with answers and a brief discussion, will be submitted.
https://davisthompsonfoundation.org/diagnostic-exercise/

Editor-in-chief for this Diagnostic Exercise: *Claudio Barros*
Associate Editor for this Diagnostic Exercise: *Andréia Vielmo.*

Braz J Vet Pathol, 2026, vol. 19, Suppl. 1, e019S114
DOI: https://doi.org/10.24070/bjvp.1983-0246.019S114

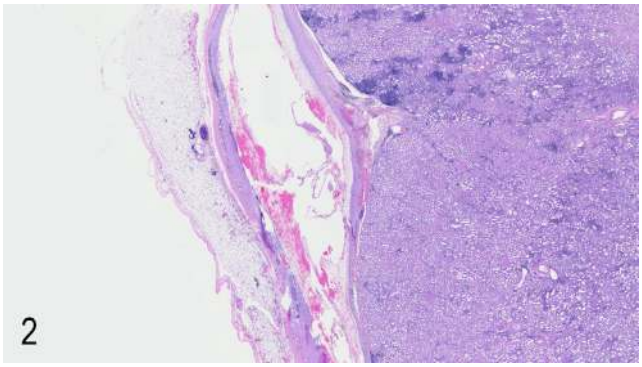

Figure 2. Clusters of densely packed erythrocytes, multiple fibrin aggregates, and proteinaceous fluid severely distend the space between the renal capsule and the visceral peritoneum.

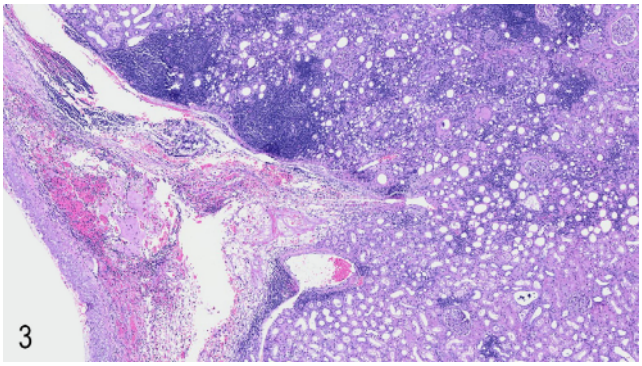

Figure 3. The capsular surface is uneven, dipping inward at the site of multiple chronic infarcts.

in number while glomeruli are increased in number per unit area. Abundant collagen surrounds the glomeruli and rare remaining tubules. Similarly, collagen severely thickens Bowman's capsules surrounding multiple glomeruli. Numerous large lymphoid aggregates multifocally infiltrate the fibrotic interstitium and extend into the interstitium of the bordering cortex (Figure 4).

Follow-up questions:

- *Gross findings:*
- *Microscopic findings:*
- *Morphologic diagnosis:*

Microscopic findings:

Kidney: Clusters of densely packed erythrocytes, multiple aggregates of fibrin, and proteinaceous fluid severely distend the space between the renal capsule and the visceral peritoneum (Figure 2). The capsular surface is uneven, dipping inward at the site of multiple chronic

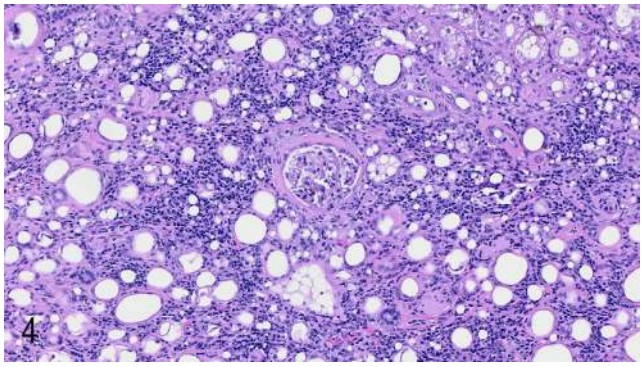

Figure 4. At sites of infarction, tubules are severely reduced in number, while glomeruli are increased per unit area. Abundant collagen surrounds the glomeruli and rare remaining tubules. Similarly, collagen severely thickens Bowman's capsules surrounding multiple glomeruli. Numerous large lymphoid aggregates multifocally infiltrate the fibrotic interstitium and extend into the interstitium of the bordering cortex

infarcts (Figure 3). At sites of infarction, tubules are severely reduced in number while glomeruli are increased in number per unit area. Abundant collagen surrounds the glomeruli and rare remaining tubules. Similarly, collagen severely thickens Bowman's capsules surrounding multiple glomeruli. Numerous large lymphoid aggregates multifocally infiltrate the fibrotic interstitium and extend into the interstitium of the bordering cortex (Figure 4).

Morphologic diagnosis:

Kidney:
1. Perinephric pseudocyst
2. Nephritis, interstitial, lymphocytic and fibrosing, multifocal, moderate, chronic
3. Infarcts, multifocal, severe, chronic

Comments:

Perinephric pseudocysts are accumulations of fluid in a space between the renal capsule and the renal reflection of the peritoneum (2). The accumulated fluid can be urine, lymph, transudate, or, as observed in this case, blood (2). They are termed pseudocysts because the space where the fluid accumulates is not lined by epithelium. Perinephric pseudocysts can result from trauma, lymphatic or ureteral obstruction, hypertension, or can be idiopathic (2). In cats, they are often found with chronic kidney disease; the cause is unknown (3). Clinical signs are those caused by chronic kidney disease (polyuria/polydipsia, anorexia, lethargy, and weight loss) and by the presence of the cyst (abdominal distension) (3, 5). Antemortem diagnosis relies on abdominal ultrasound (3, 5).

Braz J Vet Pathol, 2026, vol. 19, Suppl. 1, e019S114
DOI: https://doi.org/10.24070/bjvp.1983-0246.019S114

Chronic kidney disease is common in older cats and can be caused by chronic pyelonephritis, chronic glomerulonephritis, amyloidosis, and neoplasia (4). However, an apparent cause is absent in most cases (1, 4). Common histologic findings include interstitial inflammation and fibrosis and tubular atrophy (1). In addition, multiple infarcts were observed, suggesting a thromboembolic process which can be secondary to hyperthyroidism, neoplasia, or hypertrophic cardiomyopathy.

References:

1. Brown CA, Elliott J, Schmiedt CW, Brown SA. Chronic kidney disease in aged cats: clinical features, morphology, and proposed pathogeneses: clinical features, morphology, and proposed pathogeneses. Vet Path 2016;53: 309-326.
2. Cianciolo R, McLeland S. Urinary System: Renal cysts. In: Maxie MG, editor. Jubb, Kennedy & Palmer's Pathology of domestic animals. 7th ed., Vol. 2. Philadelphia: Elsevier; 2026. p.397.
3. DiBartola SP, Westropp J. Urinary Tract Disorders: Renomegaly. In: Nelson RW, Couto CG. Small animal internal medicine. 6th ed. St. Louis: Elsevier; 2019. p. 656-657
4. DiBartola SP, Westropp J. Urinary Tract Disorders: Chronic kidney disease. In: Nelson RW, Couto CG. Small animal internal medicine. 6th ed. St. Louis: Elsevier; 2019. p. 692-693.
5. Ochoa VB, DiBartola SP, Chew DJ, Westropp J, Carothers M, Biller D. Perinephric pseudocysts in the cat: a retrospective study and review of the literature. J Vet Diagn Invest 1999;13: 47-55.