Braz J Vet Pathol, 2026, vol. 19, Suppl. 1, e019S115
DOI: https://doi.org/10.24070/bjvp.1983-0246.019S115

BJVP
Brazilian Journal of Veterinary Pathology
ISSN 1983-0246

Diagnostic Exercise
From the Latin Comparative Pathology Group and the Davis-Thompson Foundation

Visceral gout in a chameleon

Víctor Rodríguez[1], Javier Asín2, Nicolás Streitenberger[2], Francisco A Uzal[2]*

[1]Laboratorio Regional Noroeste DILAVE "Miguel C. Rubino", MGAP. Paysandú, Uruguay
[2]California Animal Health and Food Safety Laboratory System, San Bernardino branch, School of Veterinary Medicine, University of California-Davis, USA

***Corresponding author:** fauzal@ucdavis.edu

History: A euthanized 5-year-old, Chameleon with a 2-week history of swelling of rear limbs, lethargy, and decreased appetite.

Necropsy findings: Both rear legs were diffusely swollen (Fig. 1). The kidneys were enlarged and pale, and had an irregular surface and multifocal to coalescing off-white, gritty foci (Fig. 2). There were several nematodes (2 mm in diameter and 4-5 cm in length) in the stomach (Fig. 1)

Histologic description:

Multifocally, expanding and replacing tubules and extending into the adjacent cortical interstitium, there are colorless to basophilic radiating, sharp, acicular, crystalline deposits up to 150 microns in diameter which are often surrounded by macrophages, viable and degenerate heterophils, and small amounts of eosinophilic cellular and karyorrhectic debris, hemorrhage and fibrin (urate tophi) (Figs. 3-5). The tubules exhibit one or more of the following changes: mild ectasia with attenuated epithelium, swollen epithelial cells with indistinct cell borders and microvacuolated cytoplasm, hypereosinophilic epithelial cytoplasm and pyknotic nuclei, and hypertrophic, crowded epithelial cells with prominent nuclei that have coarse chromatin and rare mitotic figures. Multifocally, the tubular lumina contain sloughed necrotic epithelial cells admixed with heterophils and cellular debris or homogeneous acidophilic material. The affected tubules often have disruption of the basement membrane. The glomeruli have thickened Bowman's capsule and are hypercellular. There is diffuse interstitial fibrosis and, multifocally, the interstitium is infiltrated by few heterophils and macrophages.

Ancillary test results: *Ascaris* spp. eggs were observed in the feces.

Morphologic diagnosis:

Nephropathy, with multifocal urate tophi, tubular degeneration, necrosis and regeneration, mild interstitial lymphoplasmacytic and heterophilic nephritis and fibrosis

The Diagnostic Exercises are an initiative of the Latin Comparative Pathology Group (LCPG), the Latin American subdivision of The Davis-Thompson Foundation (DTF). These exercises are contributed by members and non-members from any country of residence. Consider submitting an exercise! A final document containing this material with answers and a brief discussion will https://davisthompsonfoundation.org/diagnostic-exercise/

Editor-in-chief for this Diagnostic Exercise: *Claudio Barros*
Associate Editor for this Diagnostic Exercise: *Francisco A Uzal*

Braz J Vet Pathol, 2026, vol. 19, Suppl. 1, e019S115
DOI: https://doi.org/10.24070/bjvp.1983-0246.019S115



Figure 1. The right rear leg is diffusely swollen. The stomach had several round worms (arrow). **Figure 2.** The left kidney is enlarged and has multiple and coalescing off-white tan foci.

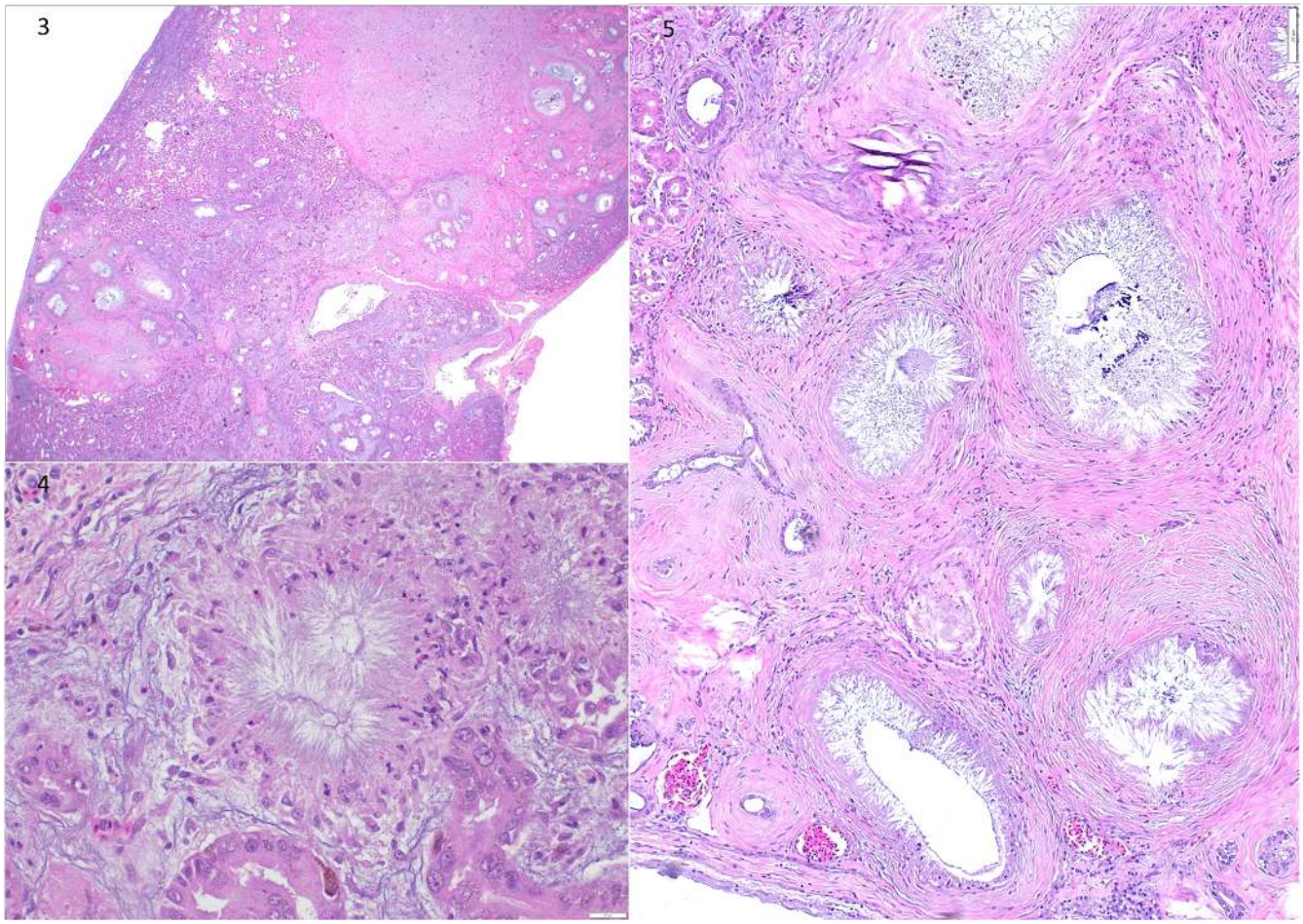

Figures 3–5. Microscopic findings in the kidneys of a 5-year-old chameleon with visceral gout. H-E.
Figure 3. Kidney. Multifocal to coalescing areas replacing the normal renal architecture, composed of eosinophilic material with an amorphous to radiating appearance (urate tophi). **Figure 4.** Higher magnification of the urate tophi, characterized by nodules or aggregates of radiating crystals associated with granulomatous inflammation.
Figure 5. Tubular dilation and epithelial cell degeneration associated with a mixed interstitial inflammatory infiltrate, composed predominantly of macrophages and, to a lesser extent, heterophils, with variable areas of fibrosis.

Etiology: Undetermined. Among possible etiologies, the most frequently reported include severe and prolonged dehydration, starvation, renal disease, excessive purine intake (dietary imbalance), hypovitaminosis A, and the use of diuretic drugs and nephrotoxic antibiotics (sulfonamides and aminoglycosides).

Name the disease:

Visceral gout

Comments:

Gout is a disease characterized by abnormal uric acid metabolism and excretion, leading to abnormal intracellular and extracellular deposition of uric acid in tissues. This disease is very rarely described in domestic mammals (7); it occurs most commonly in reptiles, birds, and humans (1,2). Reptiles excrete nitrogen waste as uric acid, which is removed from the circulating blood by the kidneys. When an animal has gout, it does not eliminate uric acid effectively and it builds up in the bloodstream (3,4)

Any reptile can develop gout; however, certain groups exhibit markedly higher incidences due to their physiology and the diets they receive in captivity, including lizards, tortoises and snakes. Gout shows no sex predilection. It affects animals of various ages, although it is more common in older individuals (1,3,4).

Common causes include any condition that interferes with uric acid metabolism, leading to increased production or decreased excretion. Primary causes include chronic dehydration, dietary errors (such as excessive protein intake [e.g., feeding dog or cat food]), chronic kidney disease, renal neoplasms, hypovitaminosis A, and therapeutic management (such as the use of nephrotoxic drugs, including aminoglycosides) (1,4,6).

According to the affected tissues, gout is classified as visceral gout or articular gout. These urate deposits cause tissue damage and trigger an inflammatory response (1,4). In both forms, grossly, there are fine white to whitish stippling or striations within the visceral parenchyma, an opaque coating on serosal surfaces, or large nodular accumulations of pasty material within joints or periarticular tissues (4,5,7).

Histologically, pale, radiating, faintly basophilic, or fibrillar material disrupts the normal tissue architecture. The classic lesion is arranged as nodules or starburst-shaped aggregates of monosodium urate crystals (tophi), surrounded by granulomatous inflammation composed of heterophils, macrophages, and multinucleated giant cells (4,5,6).

Differential diagnoses of gout include infectious and non-infectious granulomas such as mycobacteriosis (Mycobacterium spp.), systemic mycoses (Aspergillus spp., blastomycosis), and pseudogout (calcium deposits).

The diagnosis in this case was based on clinical signs and macroscopic and histopathological findings, including characteristic urate tophi. Finally, the nematodes identified in the stomach were considered incidental.

References:

1 Divers SJ, Innis CJ. Urology. In: Divers SJ, Stahl SJ, editors. Mader's Reptile and Amphibian Medicine and Surgery. 3rd ed. St. Louis: Elsevier; 2019. p. 624-648.
2 Maxie MG, editor. Jubb, Kennedy, and Palmer's Pathology of Domestic Animals. 6th ed. Vol. 1. St. Louis (MO): Elsevier; 2016. Chapter 2, p. 157.
3 Soare T, Iordache AM, Nicolae G, Iordache SM, Baciu C, Marinescu S, et al. Identification of uric acid crystals accumulation in human and animal tissues using combined morphological and Raman spectroscopy analysis. Diagnostics (Basel). 2022;12(11):2762.
4 Garner MM, Jacobson ER, editors. Noninfectious Diseases and Pathology of Reptiles: Color Atlas and Text. Vol. 2. Boca Raton: CRC Press; 2020. p. 107-110.
5 Zwart P. Renal pathology in reptiles. Vet Clin Exot Anim Pract. 2006;9(1):129-159. p. 140-141.
6 Johnson JG III, Watson MK. Diseases of the reptile renal system. Vet Clin North Am Exot Anim Pract. p. 123-124.
7 Kim HS, Hwang HJ, Kim HJ, Do SH. Case report: articular gout in four dogs and one cat. Front Vet Sci. 2022 Apr 26;9:752774.