



Original Full Paper

Lectin-histochemistry in the Diagnosis of Lysosomal Storage Disease Induced by Consumption of *Sida carpinifolia* in Cattle in Brazil

Pedro M. O. Pedroso¹, Fernando H. F. Gouvêa², Nadia A. B. Antoniassi¹, Aldo Gava³, David Driemeier¹

¹Department of Pathology, Federal University of Rio Grande do Sul (UFRGS), Porto Alegre, Brazil

²Animal Pathology Laboratory, Federal University of Mato Grosso (UFMT), Sinop, Brazil

³Clinical Pathology Laboratory, Santa Catarina State University (UDESC), Lages, Brazil

Corresponding author: David Driemeier

E-mail: davetpat@ufrgs.br

Submitted January 3rd 2011, Accepted February 24th 2011

Abstract

Sida carpinifolia is a plant native to Brazil and when it is ingested by animals for a prolonged period it causes α -mannosidosis. The technique of lectin-histochemistry was applied to samples of the central nervous system (CNS) of eleven cattle naturally and experimentally intoxicated by *S. carpinifolia* in Brazil. The results revealed that the animals showed labeling, mainly in cerebellum sections, with the lectins *Concanavalia ensiformis* and *Triticum vulgare* and in a lesser degree with *Succinyl Triticum vulgare*. Labeling was verified within the vacuolized cytoplasm of the cerebellar Purkinje neurons, cells of the molecular layer, cells of the granular layer and astrocytes of the white matter. There was no labeling observed for the lectins *Glycine max*, *Dolichos biflorus*, *Ulex europaeus-I*, *Arachis hypogaea* and *Ricinus communis-I*. Intoxication by *S. carpinifolia* in bovine species is characterized by lectin-histochemistry as α -mannosidosis, this being an important tool aiding to the diagnosis of lysosomal storage disease.

Key Words: Storage disease, *Sida carpinifolia*, cattle, lectin-histochemistry, Brazil

Introduction

Alpha-mannosidosis is characterized by intracellular storage and urinary excretion of oligosaccharides containing mannose, caused by a deficiency in the activity of the enzyme alpha-mannosidase (15). Acquired alpha-mannosidosis occurs following the ingestion of plants which contain the indolizidine alkaloid called swainsonine, such as *Astragalus* spp., *Oxytropis* spp., *Swainsona* spp., *Sida carpinifolia*, *Ipomoea carnea* and *Turbina cordata* (1, 2, 5, 6, 7, 8, 9, 23, 25).

Sida carpinifolia L.f. is a plant native to Brazil, which occurs in almost all of the national territory (16). The clinical changes consist of ataxia with hypermetria (6, 12, 24), dysmetria, tremors of the head and neck (6, 22, 24), motor incoordination (12, 24), nystagm, frequent falling, and difficulty in remaining stationary (6). The main histological changes observed in animals

are found in the central nervous system and are characterized by distension and vacuolization of the perikaryon of neurons, most evident in Purkinje neurons of the cerebellum, neurons of the cerebral cortex, thalamus, mesencephalon, pons and ventral horns of the spinal cord (10, 12, 24).

Lectins are proteins and glycoproteins which bind selectively to non covalent carbohydrate residues. Thus, they are of interest to and used in histochemistry, since they can specifically locate monosaccharides and oligosaccharides (4). They are found in many organisms, including viruses, bacteria and animal and plant cells (14). Lectins bound in a reversible manner and with high specificity to monosaccharides and oligosaccharides, do not show catalytic activity and, unlike antibodies, they are not produced by an immune response (4). This study reports the lectin-histochemical results for cattle affected by a lysosomal storage disease

induced by the consumption of *Sida carpinifolia* in Brazil.

Materials and Methods

The lectin-histochemical study was carried out using material from cattle naturally and experimentally intoxicated by the plant *S. carpinifolia*. For the lectin-histochemical technique cattle samples of one natural case of intoxication identified by the Veterinary Pathology Sector (UFRGS) together with ten natural and experimental cases diagnosed by the Animal Pathology Laboratory (LPA-UDESC) (11, 12) were used. The experiment was approved by the Ethical Committee of Santa Catarina State University (Protocol 1.08.05).

The lectins used were from *Concanavalia ensiformis* (α -D-mannose and α -D-glucose), *Glycine max* (α -D-N-acetyl-galactosamine, β -D-N-acetyl-galactosamine, α and β -galactose), *Dolichos biflorus* (α -D-N-acetyl-galactosamine), *Ulex europaeus-I* (α -L-fucose), *Triticum vulgare* (β -D-N-acetyl-glucosamine and N-acetyl-neuraminic acid), *succinylated Triticum vulgare* [β -(1-4)-D-N-acetyl-glucosamine], *Arachis hypogaea* [β -D-galactose (1-3)-N-acetyl-glucosamine], and *Ricinus communis-I* [β -D-galactose > α -D-galactose) (Vector Laboratories, Burlingame, CA, USA).

The slides were deparaffinized in xylol and hydrated in decreasing concentrations of alcohol. The inactivation of endogenous peroxidase was carried out with 3% hydrogen peroxide in distilled water for 30 minutes and the recovery with heat using a buffer solution of 10 mM citrate (pH 6.0) in a bain-marie (100°C) for 15 minutes. To reduce the unspecific bonds (background), the sections were treated with 5% skimmed milk (Molico®) diluted with distilled water for 30 minutes. Immediately after the lectins were applied in a dilution of 5 μ g/ml in PBS (phosphate buffered saline) pH 7.4, with the exception of Con-A which was applied in a dilution of 1 μ g/ml. The slides were then incubated in a humid chamber at 4°C for 12-14 hours overnight. After this period each slide and its respective lectin were washed individually with distilled water and PBS. Streptavidin (DAKO LSAB 2 kit, DAKO Corp., Carpinteria, CA, USA) was then applied for 20 min in a humid chamber. The development of the sections was carried out with diaminobenzidine (DAB) chromogen (DAKO) for 5 min or until the section became brown. The sections were then counterstained with Harris hematoxylin for 30 seconds and mounted in Entellan (Merck, Darmstadt, Germany Sigma Chemical Co., Saint Louis, USA) and observed under an optical microscope.

The degree of labeling intensity was attributed to each lectin using the following categories: absent (0), slight (+), moderate (++) and intense (+++). All of the cases analyzed were submitted to the technique of immune-histochemistry for rabies detection (21), since this disease has neurological manifestations, and negative results were obtained.

Results and Discussion

For the eleven cattle samples of this study labeling was mainly obtained from brain sections with the lectins *Concanavalia ensiformis* (Con-A) (Figure 1) and *Triticum vulgare* (WGA) (Figure 2) and to a lesser extent with *Succinyl WGA* (sWGA). Labeling was verified within the vacuolized cytoplasm of the cerebellar Purkinje neurons, cells of the molecular layer, cells of the granular layer and astrocytes of the white matter. There was no labeling observed for the lectins *Glycine max* (SBA), *Dolichos biflorus* (DBA), *Ulex europaeus-I* (UEA-I), *Arachis hypogaea* (PNA) and *Ricinus communis-I* (RCA-I) or for the negative controls. The labeling data for the eight lectins used are shown in Table 1.

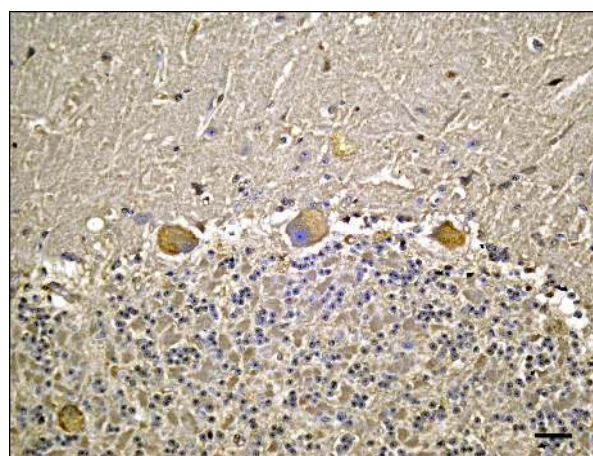


Figure 1. Bovine sample 9. Intense labeling for *Concanavalia ensiformis* (Con-A) in the cytoplasm of Purkinje neurons of the cerebellum. Lectin-histochemistry (Bar, 80 μ m).

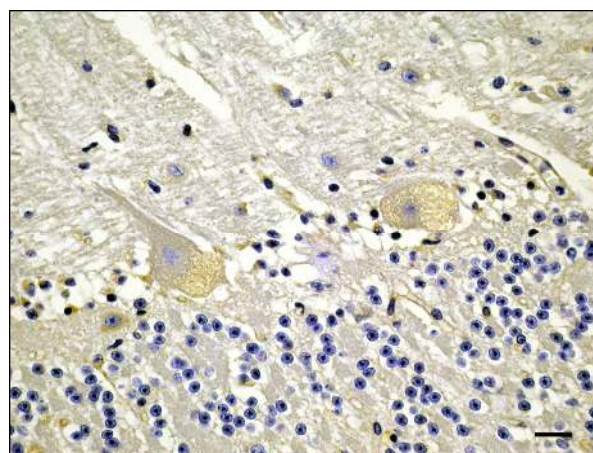


Figure 2. Bovine sample 1. Moderate labeling for *Triticum vulgare* (WGA) in the cytoplasm of Purkinje neurons of the cerebellum. Lectin-histochemistry (Bar, 40 μ m).

The diagnosis of intoxication by *Sida carpinifolia* in cattle under investigation in this study was based on the presence of the plant in the areas where the animals were confined, through the administration of the plant for the experimental animals and from the observation of clinical and pathological

changes (11, 12). These data were similar to those observed for other species after ingestion of this plant (6, 17, 22, 24).

Table 1: Lectin labeling intensity of CNS sections of cattle intoxicated by *Sida carpinifolia*

BOVINE	sWGA	WGA	UEA-I	PNA	RCA-I	SBA	DBA	Con-A
1	+	++	0	0	0	0	0	++
2	0	+	0	0	0	0	0	+
3	0	+	0	0	0	0	0	+
4	+	+	0	0	0	0	0	++
5	++	+	0	0	0	0	0	++
6	0	+	0	0	0	0	0	0
7	+	+++	0	0	0	0	0	+++
8	+	+++	0	0	0	0	0	+++
9	+	0	0	0	0	0	0	+++
10	+	+	0	0	0	0	0	+++
11	++	0	0	0	0	0	0	+++

sWGA: *Succinyl-WGA*, WGA: *Triticum vulgaris*, *Ulex europaeus-I* (UEA-I), *Arachis hypogaea* (PNA), *Ricinus communis-I* (RCA-I), *Glycine max* (SBA), *Dolichos biflorus* (DBA), Con-A: *Concanavalia ensiformis*, +: slight labeling, ++: moderate labeling, +++: intense labeling, 0: no labeling.

The lectin-histochemical technique enables the diagnosis of alpha-mannosidosis induced by *Sida carpinifolia*. In cases of alpha-mannosidosis, there is the accumulation of oligosaccharides containing mainly α -mannose and β -N-acetyl-glycosamine residues (3). Histological sections of the central nervous system, mainly the cerebellum, have been shown to be the best locations for the application of this technique due to the greater amounts of cells with vacuolized cytoplasm at these locations. The results obtained in this study are similar to those found for goats (6), sheep (24), ponies (17) and deer (22) intoxicated by *S. carpinifolia*.

The cases analyzed reacted mainly to the lectin *Concanavalia ensiformis* (Con-A), followed by *Triticum vulgaris* (WGA) and to a lesser extent labeling by the lectin *Succinyl Triticum vulgaris* (sWGA). The lectin Con-A demonstrate specificity for α -D-mannose and α -D-glucose, while the lectins WGA and sWGA express specificity for acetyl-neuraminic acid and β -D-N-acetyl-glucosaminase, respectively (13, 19).

In Southern Brazil, one plant of interest in livestock farming which should be considered in the differential diagnosis of intoxication by *S. carpinifolia*, due to the clinical neurological consequences, is *Solanum fastigiatum* (Solanaceae), known in Brazil as “*jurubeba*”. This plant leads to clinical brain signals characterized by periodic epileptiform crises, with the duration varying between a few seconds and one minute, with fine cellular vacuolization limited to the Purkinje neurons of the cerebellum (18). However, with the lectin-histochemical technique this can be differentiated, since intoxication by *Sida carpinifolia* is characterized by alpha-mannosidosis (10, 24) whereas in cases of intoxication by *Solanum fastigiatum* there is glycolipid storage disease (20). In this latter disease, there is a reaction to the lectins *Concanavalia ensiformis* (Con-A), *Triticum vulgaris* (WGA), *Succinyl*

Triticum vulgaris (sWGA) and *Ricinus communis-I* (RCA-I) (20).

Lectin-histochemistry has been shown to be an important tool in the diagnosis of lysosomal storage diseases, including those induced by toxic plants. Lysosomal storage disease induced by *S. carpinifolia* in cattle is characterized by lectin-histochemistry as alpha-mannosidosis.

Acknowledgements

This study was funded by The Conselho Nacional de Desenvolvimento Científico e Tecnológico (CNPq), Brazil.

References

1. ARMIÉN AG., TOKARNIA CH., PEIXOTO PV., FRESE K. Spontaneous and experimental glycoprotein storage disease of goats induced by *Ipomoea carnea* subsp *fistulosa* (Convolvulaceae). Vet. Pathol., 2007, 44, 170-184.
2. BALOGH KIM., DIMANDE AP., VAN der LUGT JJ., MOLYNEUX RJ., NAUDÉ TW., WELMAN WG. A lysosomal storage disease induced by *Ipomoea carnea* in goats in Mozambique. J. Vet. Diagn. Invest., 1999, 11, 266-273.
3. BEAUDET AL. Disorders of glycoprotein degradation: mannosidosis, fucosidosis, sialidosis ad aspartylglycosaminuria. In: The Metabolic Basis of Inherited Diseases, ed. STANBURY JB., WYNGAARDEN JB., FREDRICKSON DAS., GOLDSTEIN JL., BROWN MS., McGraw-Hill, New York, 1983: 788-802.
4. BROOKS SA., LEATHEM AJC., SCHUMACHER U. Lectin Histochemistry. 5th ed. Bios Scientific Publishers, Oxford, 1997.

5. COLEGATE SM., DORLING PR., HUXTABLE CR. A spectroscopic investigation of swainsonina: an alfa-mannosidase inhibitor isolated from *Swainsona canescens*. Aust. J. Chem., 1979, 32, 2257-2264.
6. COLODEL EM., DRIEMEIER D., LORETTI AP., GIMENO EJ., TRAVERSO SD., SEITZ AL., ZLOTOWSKI P. Aspectos clínicos e patológicos da intoxicação por *Sida carpinifolia* (Malvaceae) em caprinos no Rio Grande do Sul. Pesq. Vet. Bras., 2002, 22, 51-57.
7. DAMIR HA., ADAM S., TARTOUR G. The effects of *Ipomoea carnea* on goats and sheep. Vet. Hum. Toxicol., 1987, 29, 316-319.
8. DANTAS AFM., RIET-CORREA F., GARDNER DR., MEDEIROS RMT., BARROS SS., ANJOS BL., LUCENA RB. Swainsonine-induced lysosomal storage disease in goats caused by the ingestion of *Turbina cordata* in Northeastern Brazil. Toxicon., 2007, 49, 111-116.
9. DORLING PR., HUXTABLE CR., COLEGATE SM. Inhibition of lysosomal alpha-mannosidase by swainsonine, an indolizidine alkaloid isolated from *Swainsona canescens*. Biochem. J., 1980, 191, 649-651.
10. DRIEMEIER D., COLODEL EM., GIMENO EJ., BARROS SS. Lysosomal storage disease caused by *Sida carpinifolia* in goats. Vet. Pathol., 2000, 37, 153-159.
11. FURLAN FH., LUCIOLI J., VERONEZI LO., TRAVERSO SD., GAVA A. Intoxicação experimental por *Sida carpinifolia* (Malvaceae) em bovinos. Pesq. Vet. Bras., 2008, 28, 57-62.
12. FURLAN FH., LUCIOLI J., VERONEZI LO., MEDEIROS A., BARROS SS., TRAVERSO SD., GAVA A. Spontaneous lysosomal storage disease caused by *Sida carpinifolia* (Malvaceae) poisoning in cattle. Vet. Pathol., 2009, 46, 343-347.
13. GOLDSTEIN IJ., HAYES CE. The lectins: carbohydrate-binding proteins of plants and animals. Adv. Carbohydr. Chem. Biochem., 1978, 35, 127-340.
14. HARTMUT F. Advances in Lectin Research, Springer-Veriang, Berlin, 1991.
15. JOLLY RD., DODDS WJ., RUTH GR., TRAUNER DB. Screening for genetic diseases: principles and practice. Adv. Vet. Sci. Comp. Med., 1981, 25, 245-276.
16. KISSMANN KG., GROTH DG. Plantas Infestantes e Nocivas, BASF S.A., São Bernardo do Campo, 2000.
17. LORETTI ALP., COLODEL EM., GIMENO EJ., DRIEMEIER D. Lysosomal storage disease in *Sida carpinifolia* toxicosis: an induced mannosidosis in horses. Equine. Vet. J., 2003, 35, 434-438.
18. MÉNDEZ MC., RIET-CORREA F. Plantas Tóxicas e Micotóxicoses, Editora e Gráfica Universitária, Pelotas, 2008.
19. MONSIGNY M., ROCHE AC., SENE C., MARGET-DOMMA R., DELMOTTE F. Sugar-lectin interations: how dos wheat-germ agglutinin bind sialoglycoconjugates?. Eur. J. Biochem., 1980, 104, 147.
20. PAULOVICH FB., PORTIANSKY EL., GIMENO EJ., SCHILD AL., MÉNDEZ MC., RIET-CORREA F. Lectin histochemical study of lipopigments present in the cerebellum of *Solanum fastigiatum* var. *fastigiatum* intoxicated cattle. J. Vet. Med. A., 2002, 49, 473-477.
21. PEDROSO PMO., PESCADOR CA., BANDARRA PM., RAYMUNDO DL., BORBA MR., WOUTERS F., BEZERRA JÚNIOR PS., DRIEMEIER D. Padronização da técnica de imuno-histoquímica para raiva em amostras de sistema nervoso central de bovinos fixados em formol e emblocados em parafina. Pesq. Vet. Bras., 2008, 28, 627-632.
22. PEDROSO PMO., VON HOHENDORF R., OLIVEIRA LGS., SCHMITZ M., CRUZ CEF., DRIEMEIER D. *Sida carpinifolia* (Malvaceae) poisoning in fallow deer (*Dama dama*). J. Zoo. Wildl. Med., 2009, 40, 583-585.
23. PFISTER JA., STEGELMEIER BL., GARDNER DR., JAMES LF. Grazing of spotted locoweed (*Astragalus lentiginosus*) by cattle and horses in Arizona. J. Anim. Sci., 2003, 81, 2285-2293.
24. SEITZ AL., COLODEL EM., SCHMITZ M., GIMENO EJ., DRIEMEIER D. Use de lectin histochemistry to diagnose *Sida carpinifolia* (Malvaceae) poisoning in sheep. Vet. Rec., 2005, 156, 386-388.
25. STEGELMEIER BL., MOLYNEUX RJ., ELBEIN AD., JAMES LF. The lesions of locoweed (*Astragalus mollissimus*), swainsonine, and castanospermine in rats. Vet. Pathol., 1995, 32, 289-298.