



Original Full Paper

Histopathological Aspects and Etiology of Pneumonias in Stranded Marine Mammals from Lima, Peru

Omar Gonzales-Viera¹, Alfonso Chavera², Carlos Yaipén-Llanos³, Rosa Perales-Camacho²

¹Laboratório de Patologia Comparada de Animais Silvestres, Pós-graduação em Patologia Experimental e Comparada, Departamento de Patologia, Faculdade de Medicina Veterinária e Zootecnia, Universidade de São Paulo, SP, Brasil.

²Laboratório de Histologia, Embriologia y Patología Veterinaria, Facultad de Medicina Veterinaria, Universidad Nacional Mayor de San Marcos, Lima, Peru.

³Organización Científica para Conservación de Animales Acuáticos, Lima, Peru.

Corresponding author: Omar Gonzales-Viera, Departamento de Patologia (VPT), FMVZ-USP, Rua Prof Dr Orlando Marques de Paiva 87, 05009-000, São Paulo, SP, Brazil. E-mail: omaragv1@usp.br

Submitted November 21st 2010, Accepted February 16th 2011

Abstract

This study presents the histopathologic features of pneumonia in stranded marine mammals on the coast of Lima, Peru during the period of May 2003 to December 2008. Lung samples of 24 South American sea lions (*Otaria flavescens*), four bottlenose dolphins (*Tursiops truncatus*), one dusky dolphin (*Lagenorhynchus obscurus*), one Burmeister's porpoise (*Phocoena spinipinnis*) and one marine otter (*Lontra felina*) were fixed in 10% formalin and then processed and stained with haematoxylin and eosin, periodic acid-Schiff (PAS) and trichromic of Masson. From the 31 samples collected only 29 were suitable for microscopic evaluation. The results show a rate of 29/29 pneumonias (100%), five of which were associated to parasites (17%), six of bacteria (21%), four of mixed (parasites and bacteria) (14%) and 14 were of nonspecific cause (48%). The present research indicates that those marine mammals from Lima, Peru are exposed to lungworms, flukes and bacteria that alone or mixed may cause pneumonias, which could be contributed or to be the primary cause of the stranding in these animals.

Key Words: Histopathology, pneumonias, *Otaria flavescens*, *Tursiops truncatus*, *Lagenorhynchus obscurus*, *Phocoena spinipinnis*, *Lontra felina*, Lima, Peru

Introduction

Pneumonia is an important cause of morbidity and mortality in marine mammals and may have a variety of causes. Parasites have caused the principal health problems in these species (6). Marine mammals tend to be very exposed to parasitic infections, because of the infective larvae are within fishes and other marine invertebrates, which are part of their diet (16). In cetaceans, flukes of the genera *Hunterotrema* and *Nasitrema* can affect the respiratory system, air sinus and brain (6). Lungworms of the family Pseudalidae, genera *Halocercus*, *Pseudalius* and *Stenurus* are the most common parasites found in cetaceans (24). Dailey and Stroud, 1978 (5) described that the primary cause of death of two stranded harbour porpoises (*Phocoena phocoena*) on the coast of Oregon was a parasitic

pneumonia due to *Pharurus convolutus*, *Stenurus minor* and *Halocercus invaginatus*. In Peru, *Pseudalius inflexus* and *Halocercus spp* were found in a Burmeister's porpoise (*Phocoena spinipinnis*) and a common dolphin (*Delphinus delphi*), respectively (31). In seals and sea lions, two species of nematodes, *Otostrongylus circumlitus* and *Filaroides (Parafilaroides) spp.*, can infect their respiratory system (6, 24). In this sense, Onderka, 1989 (26) described pulmonary lesions with different degrees of severity in 382 ringed seals (*Phoca hispida*) caused mostly by *O. circumlitus* and *Parafilaroides hispidus*.

In the respiratory system of marine mammals pathogenic bacteria can often be cultured more frequently than in other tissues and organs (10). Bacterial pneumonia is a very common disease that can lead to the stranding and death of pinnipeds and

cetaceans (17). Furthermore, bacterial respiratory infections often result from a heavy parasitism (10, 13, 30).

Mycotic pneumonia caused by *Aspergillus spp.* is in fact the most problematic pulmonary mycosis in marine mammals (28). Pulmonary aspergillosis has been identified in different species of odontocetes (14, 18, 19) and pinnipeds (14, 28). In sea otters (*Enhydra lutris*), *Cryptococcus neoformans* was identified by culture and histopathology of lungs (28).

Several epizootics have been reported in pinnipeds and cetaceans associated with members belonging to the genus Morbillivirus such as Phocine Distemper Virus (PDV) (21) and Cetacean Morbillivirus (CeMV) (3), of the latter two strains have been recognized as Porpoise Morbilliviruses (PMV) and Dolphin Morbilliviruses (DMV) (1). Additionally, pneumonias can be also seen in the absence of an obvious pathogen (15).

This paper aims to describe histopathological aspects of pneumonias found in stranded marine mammals on the coast of Lima, Peru and associate them to possible causes found microscopically. Moreover, we described the main gross lesions observed in the lungs of these species.

Materials and Methods

From May 2003 to December 2008, the Organización Científica para Conservación de Animales Acuáticos recorded proximately 160 stranded marine mammals, along the coast of Lima. The condition of the carcasses ranged from freshly dead to the start of decomposition (12), necropsies were performed following standard protocols for marine mammals (7). Lung samples of 31 marine mammals were collected from pneumonic areas and they were fixed in 10 % formalin and then, taken to the Laboratorio de Histología, Embriología y Patología Veterinaria, Facultad de Medicina Veterinaria - Universidad Nacional Mayor de San Marcos. After fixation the samples were embedded in paraffin, sectioned in 4-5 μm and stained with haematoxylin and eosin, trichrome of Masson and periodic acid-Schiff (PAS). Two of these samples were not suitable for histological evaluation because one of them was mixed with sand and unsuitable for processing and the other was autolytic. Therefore, 29 lung samples were of 22 South-American sea lions (*Otaria flavescens*) (12 males, 10 females), four bottlenose dolphins (*Tursiops truncatus*) (three males, one female), one dusky dolphin (*Lagenorhynchus obscurus*) (female), one Burmeister's porpoise (*Phocoena spinipinnis*) (female) and one marine otter (*Lontra felina*) (male) were studied. The approximate age was determined by macroscopic observation of gonadal maturation, distinctive external features or was inferred from the standard body size and 10 calves, 13 immature and 6 mature animals were recorded.

According to Bochsler and Slauson, 2002 (2), the classification of inflammatory lesions were classified for severity as mild, moderate and severe; and the duration as acute, sub acute and chronic.

Results

In all the animals, the main gross lesion found was moderate to severe lobar pneumonia; however, pulmonary congestion, alveolar emphysema and frothy fluid in trachea and bronchi were also seen associated to pneumonias. Filariform structures belonging to nematodes genera mixed with inflammatory exudate were seen within the bronchial tree of three South American sea lions diagnosed of verminous pneumonia. Moreover, two of the three animals had whitish pleural meshed exudate diagnosed as fibrinous pleuropneumonia.

Histopathological details and their associated noxogenic agents are presented in Table 1. These results, describe the presence of nematodes found in seven South American sea lions and in the only marine otter studied; these parasites varied in size, however, they shared similar features such as round to oval, external smooth and sinuous cuticle, fine coelomyarian muscles, accessory hypodermal and lateral chords (Fig 1) and in few cases larvae developed within females were observed (Fig 2). In three of these seven South American sea lions and in the marine otter, the parasites found were associated to pneumonia, bronchopneumonia or pleurobronchopneumonia. On the other hand, one bottlenose dolphin was diagnosed with fluke infection surrounded by severe granulomatous eosinophilic bronchopneumonia with dystrophic calcification (Fig 3). These parasites had different characteristics than those found in the previous animals, they were flat and twisted upon themselves with external teguments containing spines. In despite of some degree of autolysis, the parenchyma of the parasite could be recognized and some eggs were seen within it (Fig. 4). Degenerated eggs varying from oval to triangular shape-shelled and yellowish to brownish color were infiltrated by multinucleated giant cells and all of them were surrounded by eosinophilic granulomatous reaction (Fig. 4).

Six animals had pneumonias associated to bacteria (five South American sea lions and one bottlenose dolphin); cluster of bacteria were found within the alveolar or bronchial lumen and these were basophilic coccobacilli usually surrounded by mild to severe mixed inflammatory exudate composed of degenerated neutrophils, serous fluid and erythrocytes (Fig. 5). Furthermore, four of these six cases had mainly suppurative exudate within the alveolar and bronchial lumen that surrounds similar bacteria organism.

In four South American sea lions, the nematodes found were accompanied by mostly basophilic coccobacilli bacteria causing a severe "mixed" pneumonia.

Table 1: Details of the histopathological diagnosis of pneumonias and their associated noxogenic agents in the marine mammals studied

Species	N*	Parasitic	N	Bacterial	N	Mixed (parasitic and bacterial)	N	Nonspecific	N
<i>Otaria flavescens</i>	22	Fibrinosuppurative catarrhal pleurobronchopneumonia + dystrophic calcification	1	Mucosuppurative bronchopneumonia	1	Necrotic suppurative bronchopneumonia	1	Suppurative catarrhal bronchopneumonia	3
		Necrotic nonsuppurative bronchopneumonia + dystrophic calcification	1	Suppurative interstitial pneumonia	1	Mucocatarrrhal nonsuppurative interstitial bronchopneumonia	1	Nonsuppurative pneumonia	1
		Suppurative pneumonia	1	Haemorrhagic catarrhal interstitial bronchopneumonia	1	Fibrinosuppurative catarrhal pleurobronchopneumonia	1	Mucocatarrrhal suppurative bronchopneumonia	2
				Suppurative bronchopneumonia	1	Suppurative catarrhal interstitial bronchopneumonia	1	Nonsuppurative interstitial pneumonia	1
				Haemorrhagic nonsuppurative pneumonia	1			Suppurative bronchopneumonia	1
						Haemorrhagic suppurative interstitial bronchopneumonia	1		
						Haemorrhagic catarrhal bronchopneumonia	1		
<i>Tursiops truncatus</i>	4	Granulomatous eosinophylic bronchopneumonia + dystrophic calcification	1	Suppurative bronchopneumonia	1			Suppurative bronchopneumonia	1
								Suppurative pneumonia	1
<i>Lagenorhynchus obscurus</i>	1							Suppurative pneumonia	1
<i>Phocoena spinipinnis</i>	1							Suppurative bronchopneumonia	1
<i>Lontra felina</i>	1	Catarrhal nonsuppurative interstitial bronchopneumonia	1						
TOTAL	29		5		6		4		14

*Number

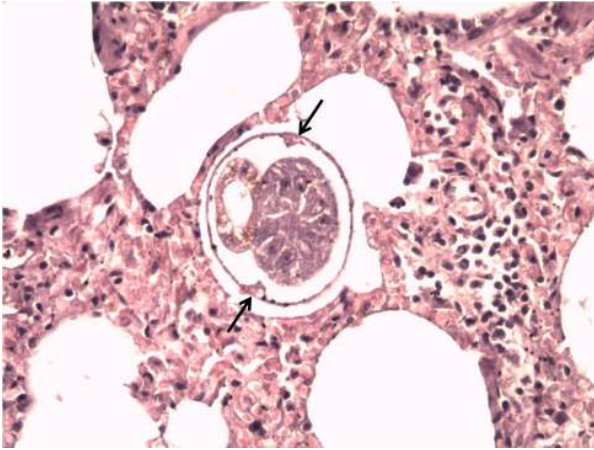


Figure 1: Metastrongyles within the alveolar lumen of a marine otter. Note the lateral chords (arrow) and the interstitial inflammatory reaction. Haematoxylin and eosin. 200X.

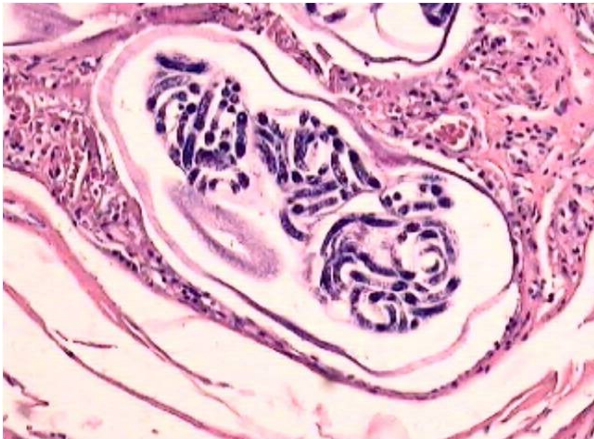


Figure 2: Cross section of female Metastrongyles within the alveolar lumen of a South American sea lion. Note the developing larvae within it. Haematoxylin and eosin. 100X.

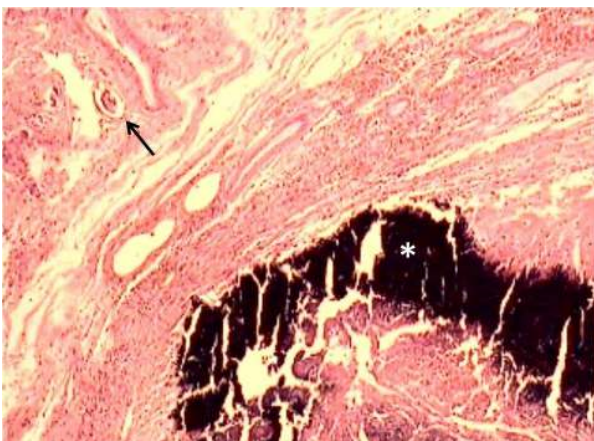


Figure 3: Severe dystrophic calcification (asterisk) surrounded by vascularized connective tissue in a bottlenose dolphin. Note an egg in the periphery (arrow). Haematoxylin and eosin. 40X.

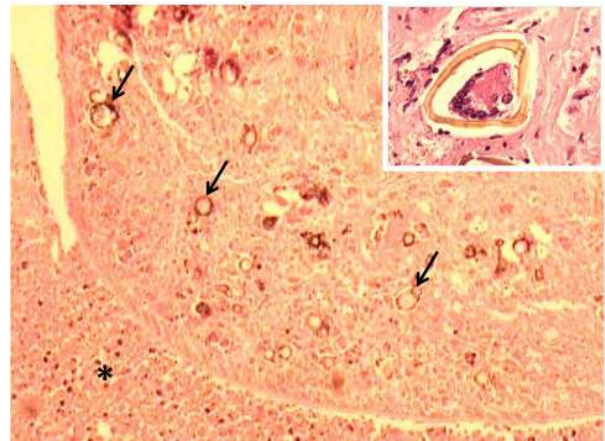


Figure 4: Edge of fluke compatible with *Nasitrema* sp. Note eggs peripherally located (arrow) and the cellular inflammatory reaction around the parasite (asterisk). Haematoxylin and eosin. 40X. Inset: Egg compatible with *Nasitrema* sp and a Langhans' giant cell within it. Haematoxylin and eosin. 400X.

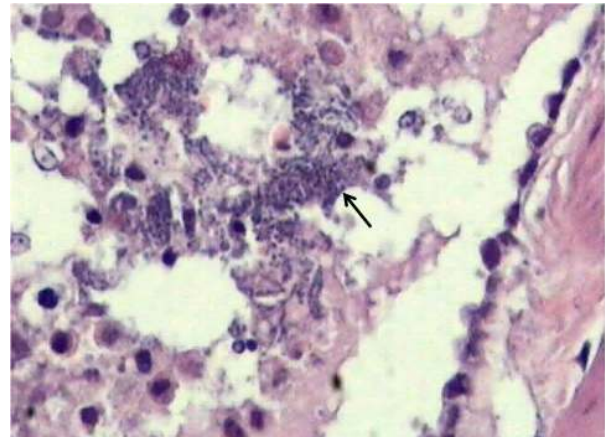


Figure 5: Basophilic coccobacilli bacteria within the bronchus (arrow) in a South American sea lion. Note degenerating inflammatory cells and serous fluid surrounding them. Haematoxylin and eosin. 400X.

Nonspecific causes of pneumonias in 10 South American sea lions, two bottlenose dolphins, one dusky dolphin and one Burmeister's porpoise were observed. These cases did not have parasitic or bacterial structures associated to the pneumonic process and 11 of these 14 cases had suppurative exudate as the principal finding accompanied in some cases of catarrhal, mucocatarrhal or hemorrhagic exudate; the other 3 cases, two were non suppurative and one hemorrhagic catarrhal exudate.

Of pneumonias associated to parasites four were of chronic stage, one was acute and all were mainly severe. The cases associated to bacteria were all acute and mainly severe. All mixed pneumonias were chronic and severe. Finally, 10 of the 14 nonspecific pneumonias were acute, while the remaining four were chronic and the severity ranged from moderate to severe.

Discussion

Grossly, the parasites found in lungs of three South American sea lions were of nematodes genera; two of these cases were diagnosed as fibrinous pleuropneumonia, which was confirmed microscopically.

According to the guidelines of Gardiner and Poynton, 1999 (11), parasites found in histological sections of seven South American sea lions and the marine otter studied were consistent with Metastrongylidae family, that includes two lungworms: *Otostrongylus circumlitus* and *Filaroides (Parafilaroides) spp.*, which affect the lungs of pinnipeds (6, 24). Four of these seven South American sea lions with parasitic pneumonias were accompanied by bacteria organism ("mixed" pneumonias); it has been described that in wild and stranded marine mammals, bacterial respiratory pneumonia is often a sequel to heavy parasitic infections (13, 10, 30). The characteristics of severity degree and exudative inflammation of parasitic pneumonia in South American sea lions were different in each case. Even though the pathogenesis of lungworms in pinnipeds has not been completely studied, the severity of the lesions depends on intensity of infections, adaptation of parasite to its host, age and immunosuppressive factors as high accumulation of contaminants, stress prior to stranding and other infectious diseases (24, 26). In addition, in two of the cases above studied lung parenchymal dystrophic calcification surrounded by severe inflammatory reaction was seen, which can appear after the necrosis caused by parasite migration (4). Larvae of the lungworm *Angyostrongylus vasorum* have been identified in the European otter (*Lutra lutra*) (23); comparatively, in Peru there are no reports of lungworms in marine otters yet 'M. Tantaleán, personal communication'. Consequently, we do not have any reference to compare the verminous pneumonia caused by Metastrongylidae family found in Peruvian marine otter. The morphological microscopic characteristics of the parasite and eggs found in the lungs of a bottlenose dolphin were consistent with trematodes (11); in this sense, *Nasitrema sp.* is usually found in the nasal cavity of several odontocetes (25). Although, *Nasitrema sp.* was not completely identified in the bottlenose dolphin, this fluke and its eggs were closely resembled to those observed by O'Shea and cols, 1991 (27). In the present study, the adult flukes and their eggs caused a granulomatous eosinophilic bronchopneumonia with dystrophic calcification, which contradicts what was proposed by Kumar and cols, 1975 (22), who argued that the adult flukes do not contribute to the pathology of the lung tissue, since they also found them in the posterior nasal passage, localization that was not evaluated in this study.

Five South American sea lions and one bottlenose dolphin were diagnosed as infection pneumonia or bronchopneumonia associated to bacteria. Generally, bacterial pneumonia is common in marine mammals and the agents involved are similar between cetaceans and pinnipeds (14, 17). In most of

these cases were found a suppurative exudate and similar results were found in bacterial pneumonia of pinnipeds (17) and harbour porpoises (18).

Fibrinosuppurative catarrhal pleurobronchopneumonia was diagnosed in two South American sea lions, which were of parasitic and mixed origin; according to Dungworth, 1990 (9), in domestic animals, the pleural inflammatory reaction is usually the result of a persistent pneumonia. Pleuropneumonia is a lesion seen in California sea lions (*Zalophus californianus*) infected by *P. decorus* (24) and also in New Zealand sea lions (*Phocarctos hookeri*) after infection with *Klebsiella pneumoniae* (32). Interstitial pneumonias and bronchopneumonias were found in seven animals, which had a parasitic, bacterial, mixed and nonspecific origin; in this sense the alveolar septal damage is caused by a blood-borne insult in most instances (9). In marine mammals, interstitial pneumonia has been associated with verminous pneumonias (13) and septicemias (18) in Northern elephant seals (*Mirounga angustirostris*) and harbor porpoises respectively. In addition, Morbillivirus cause interstitial pneumonia in pinnipeds (20) and cetaceans (8) with characteristic intracytoplasmic inclusion bodies associated to a severe lymphocytic interstitial reaction, lesions of this virus infection that were not found in this study.

Ten South American sea lions, two bottlenose dolphins, one dusky dolphin and one Burmeister's porpoise were diagnosed as having a nonspecific inflammatory process of the lung tissue. In this sense, the pneumonias and bronchopneumonias in marine mammals could be diagnosed in absence of an obvious pathogen (15). Furthermore, the majority of the nonspecific inflammatory process observed in this study had a bronchopneumonic pattern, which is usually related to infectious diseases (29).

In conclusion, using the histopathological method, this study suggests that marine mammals from Lima, Peru had pneumonias caused by one or more of the following agents: parasites (such as lungworms and flukes), bacteria and mixed infections. However, most of the cases have a nonspecific cause. In that aspect any of these causes could contribute to the development of secondary diseases or be the primary cause of the stranding in these animals.

Acknowledgements

The authors would like to thank the members and volunteers of the Organización Científica para Conservación de Animales Acuáticos, the technicians of the Laboratorio de Histología, Embriología y Patología Veterinaria, Facultad de Medicina Veterinaria, Universidad Nacional Mayor de San Marcos and our families whose support was really important in the completion of this research. Besides, we thank A. Gozalo and C. Michaud for the revision of the draft, and J. L. Catão-Dias for his positive suggestions.

References

1. BARRETT T., VISSER IKG., MAMAEV LV., GOATLEY L., VAN BRESSEM MF., OSTERHAUS ADME. Dolphin and porpoise morbilliviruses are genetically distinct from phocine distemper virus. *Virology*, 1993, 193, 1010-12.
2. BOCHSLER PN., SLAUSON DO. Inflammation and repair of tissue. SLAUSON D., COOPER B. Eds. *Mechanisms of Disease. A Textbook of Comparative General Pathology*. Missouri: Mosby Inc, 2002: 140-245.
3. BOLT G., BLIXENKRONE-MØLLER M., GOTTSCHALCK E., WISHAUP RG., WELSH MJ., EARLE JA., RIMA BK. Nucleotide and deduced amino acid sequences of the matrix (M) and fusion (F) protein genes of cetacean morbillivirus isolated from a porpoise and dolphin. *Virus Res.*, 1994, 34, 291-304.
4. CESPEDES R. Patología general de las parasitosis. ATIAS A., NEGhme A. Eds. *Parasitología Clínica*. Buenos Aires: Inter-médica, 1984: 43-8.
5. DAILEY M., STROUD R. Parasites and associated pathology observed in cetaceans stranded along the Oregon coast. *J. Wildl. Dis.*, 1978, 14, 503-11.
6. DAILEY MD. Parasitic diseases. DIERAUF LA., GULLAND FMD. Eds. *Handbook of Marine Mammal Medicine*. Florida: CRC Press, 2001: 357-79.
7. DIERAUF LA. Disposition of marine mammal. DIERAUF LA. Ed. *Handbook of Marine Mammal Medicine: Health, Disease and Rehabilitation*. Florida: CRC Press, 1990: 267-86.
8. DUIGNAN PJ., GERACI JR., RAGA JA., CALZADA N. Pathology of morbillivirus infection in Striped dolphins (*Stenella coeruleoalba*) from Valencia and Murcia, Spain. *Can. J. Vet. Res.*, 1992, 56, 242-48.
9. DUNGWORTH DL. El sistema respiratorio. JUBB KVF., KENNEDY PC., PALMER N. Eds. *Patología de los Animales Domésticos*. Montevideo: Agropecuaria hemisferio sur, 1990: 471-629.
10. DUNN JL., BUCK JD., ROBECK TR. Bacterial diseases of cetaceans and pinnipeds. DIERAUF LA., GULLAND FMD. Eds. *Handbook of Marine Mammal Medicine*. Florida: CRC Press, 2001: 309-35.
11. GARDINER CH., POYNTON SL. An atlas of metazoan parasites in animal tissues. 1.ed. Washington DC: Armed Forces Institute of Pathology, 1999.
12. GERACI JR., LOUNSBURY VJ. Specimen and data collection. GERACI JR., LOUNSBURY VJ. Eds. *Marine Mammals Ashore: A Field Guide for Strandings*. Baltimore: Texas A & M Sea Grant Publication, 2005: 167-228.
13. GULLAND FMD., WERNER L., O'NEILL S., LOWENSTINE LJ., TRUPKIEWITZ J., SMITH D., ROYAL B., STRUBEL I. Baseline coagulation assay values for northern elephant seals (*Mirounga angustirostris*), and disseminated intravascular coagulation in this species. *J. Wildl. Dis.*, 1996, 32, 536-40.
14. HIGGINS R. Bacterial and fungi of marine mammals: A review. *Can. Vet. J.*, 2000, 41, 105-16.
15. HOWARD EB. Miscellaneous diseases. HOWARD EB. Ed. *Pathobiology of Marine Mammal Diseases*. Florida: CRC Press, 1983: 163-225.
16. HOWARD EB., BRITT JO., MATSUMOTO GK. Parasitic diseases. HOWARD EB. Ed. *Pathobiology of Marine Mammal Diseases*. Florida: CRC Press, 1983: 119-232.
17. HOWARD EB., BRITT JO., MATSUMOTO GK., ITAHARA R., NAGANO CN. Bacterial diseases. HOWARD EB. Ed. *Pathobiology of Marine Mammal Diseases*. Florida: CRC Press, 1983: 69-118.
18. JEPSON PD., BAKER JR., KUIKEN T., SIMPSON VR., KENNEDY S., BENNETT PM. Pulmonary pathology of harbor porpoises (*Phocoena phocoena*) stranded in England and Wales between 1990 and 1996. *Vet. Rec.*, 2000, 146, 721-28.
19. JOSEPH BE., CARNELL LH., SIMPSON JG., MIGAKI G., GRINER L. Pulmonary aspergillosis in three species of dolphin. *Zoo Biol.*, 1986, 5, 301-8.
20. KENNEDY S., KUIKEN T., JEPSON PD., DEAVILLE R., FORSYTH M., BARRETT T., VAN DER BILDT MWG., OSTERHAUS ADME., EYBATOV T., DUCK C., KYDYRMANOV A., MITROFANOV I., WILSON S. Mass die-off of Caspian seals caused by canine distemper virus. *Emerg. Infect. Dis.*, 2000, 6, 637-39.
21. KENNEDY-STOSKOPF S. Viral diseases. DIERAUF LA., GULLAND FMD. Eds. *Handbook of Marine Mammal Medicine*. Florida: CRC Press, 2001: 285-307.
22. KUMAR V., VERCRUYSSSE P., KAGERUKA P., MORTELMANS J. *Nasitrema attenuata* (Trematoda) infection of *Tursiops truncatus* and its potentialities as an aetiological agent of chronic pulmonary lesions. *J. Helminth.*, 1975, 49, 289-92.
23. MADSEN AB., DIETZ HH., HENRIKSEN P., CLAUSEN B. Survey of Danish free living otters *Lutra lutra* - a consecutive collection and necropsy of dead bodies. *IUCN Otter Spec. Group Bull.*, 1999, 16, 65-76.
24. MEASURES LN. Lungworms of marine mammals. SAMUEL WM., PYBUS MJ., KOCAN AA. Eds.

- Parasitic Diseases of Wild Mammals. Iowa: Iowa State University Press, 2001: 279-300.
25. NEILAND K.A., RICE DW., HOLDEN BL. Helminths of marine mammals, I. The genus *Nasitrema*, air sinus flukes of delphinid cetacean. J. Parasitol., 1970, 56, 305-16.
 26. ONDERKA DK. Prevalence and pathology of nematode infections in the lungs of ringed seals (*Phoca hispida*) of the Western Arctic of Canada. J. Wildl. Dis., 1989, 25, 218-24.
 27. O'SHEA TJ., HOMER BL., GREINER EC., LAYTON AW. *Nasitrema* sp.- associated encephalitis in a striped dolphin (*Stenella coeruleoalba*) stranded in the gulf of Mexico. J. Wildl. Dis. 1991, 27, 706-9.
 28. REIDARSON TH., Mc BAIN JF., DALTON LM., RINALDI MG. Mycotic diseases. DIERAUF LA., GULLAND FMD. Eds. Handbook of Marine Mammal Medicine. Florida: CRC Press, 2001: 337-55.
 29. SCHUMACHER U., HORMY HP., HEIDEMANN G., SCHULTZ W., WELSH U. Histopathological findings in harbor seals (*Phoca vitulina*) found dead on the German North Sea coast. J. Comp. Path. 1990, 109, 299-309.
 30. SWEENEY JC., GILMARTIN WG. Survey of diseases in free-living California sea lions. J. Wildl. Dis. 1974, 10, 370-76.
 31. TANTALEÁN M. Algunos helmintos de mamíferos marinos del Perú y su importancia médica. Rev. Peru. Med. Trop. 1993, 7, 67-71.
 32. WILKINSON IS., DUIGMAN PJ., CASTINEL A., GRINBERG A., CHILVERS BL., ROBERTSON BC. 2004 *Klebsiella pneumoniae* epidemics: Possible impact on New Zealand sea lion recruitment. In Proceedings of an International Symposium: Sea Lions of the World: Conservation and Research in the 21st Century. Alaska, USA, 2004.