BJVP
Brazilian Journal of Veterinary Pathology

Original Full Paper

Involvement of Organic Systems in Golden Retriever X-linked Muscular Dystrophy

Ligia G. Miyazato[1], Daniel C. Beretta[1] , Jair R. Engracia-Filho[2], Flavio R. Moraes[1], Julieta R.E. Moraes[1]

[1] Departamento de Patologia Veterinária, Unesp - São Paulo State University, Jaboticabal, São Paulo, Brazil.
[2] Centro Universitário Barão de Mauá, Ribeirão Preto, São Paulo, Brazil.
Corresponding author: Dr. Julieta R.E. Moraes - Department of Veterinary Pathology, Unesp - São Paulo State University. Via Paulo Donato Castelanne s/n 14884-900, Jaboticabal, São Paulo, Brazil. Tel: +55 16 3209-2662. Fax: +55 16 3202-4275.
E- mail: julietaengracia@gmail.com

Submitted December 12th 2010, Accepted March 31st 2011

Abstract

Duchenne muscular dystrophy is a lethal genetic disease characterized by progressive muscle degeneration that usually had been used the Golden Retriever as a model for studying the disease (GRMD - Golden Retriever Muscular Dystrophy). A total of 16 male dystrophic Golden Retrievers dogs between 5 to 51 months of age were examined in the present study. The animals were classified as dystrophic according to two simultaneous complementary criteria: genotypic analysis and serum creatine kinase levels. The macroscopic abnormalities of the different organs and tissues and histopathological features were described using hematoxylin-eosin. The lesions in the skeletal muscles associated with the digestive problems resulted in cachexia with different intensities in all the dystrophic dogs. Cardiac muscle involvement was found in 87,5% of the GRMD dogs resulting, however, in cardiac failure in only 18,8% of the animals. The musculature of the diaphragm was hypertrophic in all affected animals resulting in progressive respiratory muscle weakness and at later stages in respiratory failure (81,25%). The liver abnormalities found in dystrophic dogs were originated mainly from heart disease and developed progressively. Hyperemia of mucosa and granular material indicated changes in the functioning and emptying of bladder. The germinative lineage cells presented moderate to severe degeneration probably due to degeneration of the scrotum and cremaster muscle which prevented the proper thermo-regulation of the testicle. Our results highlight the fact that there is significant impairment of the cardiac, respiratory and skeletal muscle systems in GRMD dogs since the age of five months. In addition, significant alterations of the gastrointestinal tract, urinary and reproductive systems are indicating the presence of degenerative lesions in the smooth musculature.

Key Words: Golden Retriever, muscular dystrophy, gross morphology, histological features

Introduction

Duchenne muscular dystrophy (DMD) is a lethal genetic disease characterized by progressive muscle degeneration. It is an X-linked disorder and is caused by mutations in the dystrophin gene responsible for production of this membrane protein (28). The absence of dystrophin is accompanied by alteration of the dystrophin-glycoprotein complex (DGC) and results in progressive degeneration of the heart, skeletal and smooth muscle with subsequent replacement of tissue by fibrosis and fatty infiltration (11, 15). The onset of disease occurs between 2 and 5 years of age and many patients die from cardiac or respiratory failure (20, 34). Cardiac involvement, which commonly occurs in DMD patients, has now become a major cause of death due to clinical progress in the treatment of respiratory symptoms (14, 35).

In search of DMD, the canine model is the most appropriate in the study of the disease due to the large clinical and morphological similarity in relation to man. The Golden Retriever (GR) presents the most common form of dystrophy in dogs and is called Golden Retriever Muscular Dystrophy (GRMD) (6, 43).

 All rights reserved 2007.

The hypertrophy of the calf muscles is mentioned as a strong feature of the disease in humans (13, 21). Similarly, dystrophic adult Golden Retrievers show hypertrophy of the thoracic limbs, tongue, diaphragm, esophagus and sartorius muscle and atrophy of the others. (29, 30, 45). In GRMD, in addition to muscle hypertrophy, there are other clinical signs that include muscle weakness, dysphagia, tremors, exercise intolerance, displacement and deformity of the limbs and elevated serum creatine kinase activity (6, 30, 43, 46, 50). Additionally, dogs DMGR also show electrocardiographic findings and progressive cardiomyopathy comparable to cardiac involvement in DMD patients (33, 48, 49). As the leading cause of death are pointed to heart and respiratory failure. (18, 46). Mortality rates are higher in the first two weeks of life and from 7 to 9 months old (24, 46, 47).

Given the above, we established a line of dogs with GRMD in Brazil and we examined the involvement of systems with the support of pathological examinations of the same.

Materials and Methods

Animals

A total of 16 male dystrophic Golden Retrievers dogs between 5 and 51 months of age were examined in the present study. They were coming from the Brazilian GRMD colony at the University of São Paulo (USP), in the State of São Paulo, Brazil. The animals were classified as dystrophic according to two simultaneous complementary criteria: genotypic analysis and serum creatine kinase (CK) levels.

Serum creatine kinase (CK) concentration

Serum samples were obtained by means of venipuncture, starting just after the dogs' birth and continuing monthly until their death. The CK analysis was determined by means of an enzymatic kit (Sigma Diagnostics, St. Louis, MO, USA).

Analysis of genomic DNA

The genomic DNA was analyzed at the Human Genome Study Center at USP. To perform the analyses, DNA was extracted from blood samples collected from young pups, using a commercial kit (GFX Genomic Blood DNA Purification Kit – Amershan Pharmacia). The genotypes of the dystrophic and non-dystrophic dogs were determined using the primers GF2 and GR1 (23, 42).

Gross morphology

The dystrophic animals used in the present work died naturally. Firstly, an external evaluation was performed to record data relating to the animal's health and also any skin or mucosa abnormalities that were present. Next, the thoracic and abdominal cavities were examined, followed by analysis of the different organic systems (digestive, cardiovascular, respiratory, genitourinary and nervous systems).

The macroscopic abnormalities of the different organs and tissues were described using the following evaluation parameters: changes in coloring, shape, volume and content.

Finally, a diagnosis was established for the cause of death, by taking into consideration the organ or set of organs most affected in each system.

Histological features

The sections of the different organs and tissues were mounted on histological slides and stained using hematoxylin-eosin (H&E) to analyze the microscopic alterations present.

Results

Creatine kinase levels

The results from the CK evaluation and death cause of dystrophic dogs are detailed in Table 1.

Table 1. Age, values of CK and death cause of the dystrophic dogs.

Animal	Age	CK (U/L)*	Death Cause
1	51 months	27064.0	Heart failure
2	21 months	12100.0	Respiratory failure
3	20 months	12862.0	Respiratory failure
4	17 months	17770.0	Respiratory failure
5	15 months	19800.0	Respiratory failure
6	15 months	17970.0	Respiratory failure
7	13 months	9072.0	Respiratory failure
8	12 months	8290.0	Respiratory failure
9	11 months	7200.0	Respiratory failure
10	11 months	8250.0	Respiratory failure
11	10 months	2431.0	Respiratory failure
12	9 months	1147.0	Respiratory failure
13	8 months	8548.0	Respiratory failure
14	8 months	3481.0	Heart failure
15	7 months	1654.0	Heart failure
16	5 months	1210.0	Respiratory failure

*CK = creatine kinase (values of reference to dogs: 40 – 254 U/L) (Mayer and Harvey, 1998)

Gross morphology

All the dystrophic dogs presented cachexia with different intensities, pallid mucosa and preputial secretion (Fig. 1A). The skeletal muscles were pale and atrophied and increased with the age. In our previous studies, we studied the influence on disease phenotype from crossing the base GR breed with Yellow Labrador Retrievers. We found that the histopathological changes were more severe in the GR dogs than in Golden Labrador Retrievers (GLR), suggesting that cross breeding could lessen the disease phenotype (33). Interestingly, it was previously reported two GRMD dogs (Ringo and Suflair) with an unusually mild disease course. In these dogs the dystrophin was absent, and utrophin was overexpressed in a pattern similar to that observed in severely affected dogs. In addition, fiber-type distribution, histopathologic and immunohistochemical findings from biopsies of biceps femoris in these dogs were similar to those seen in GRMD dogs with a more severe clinical phenotype (2, 52).

 All rights reserved 2007.

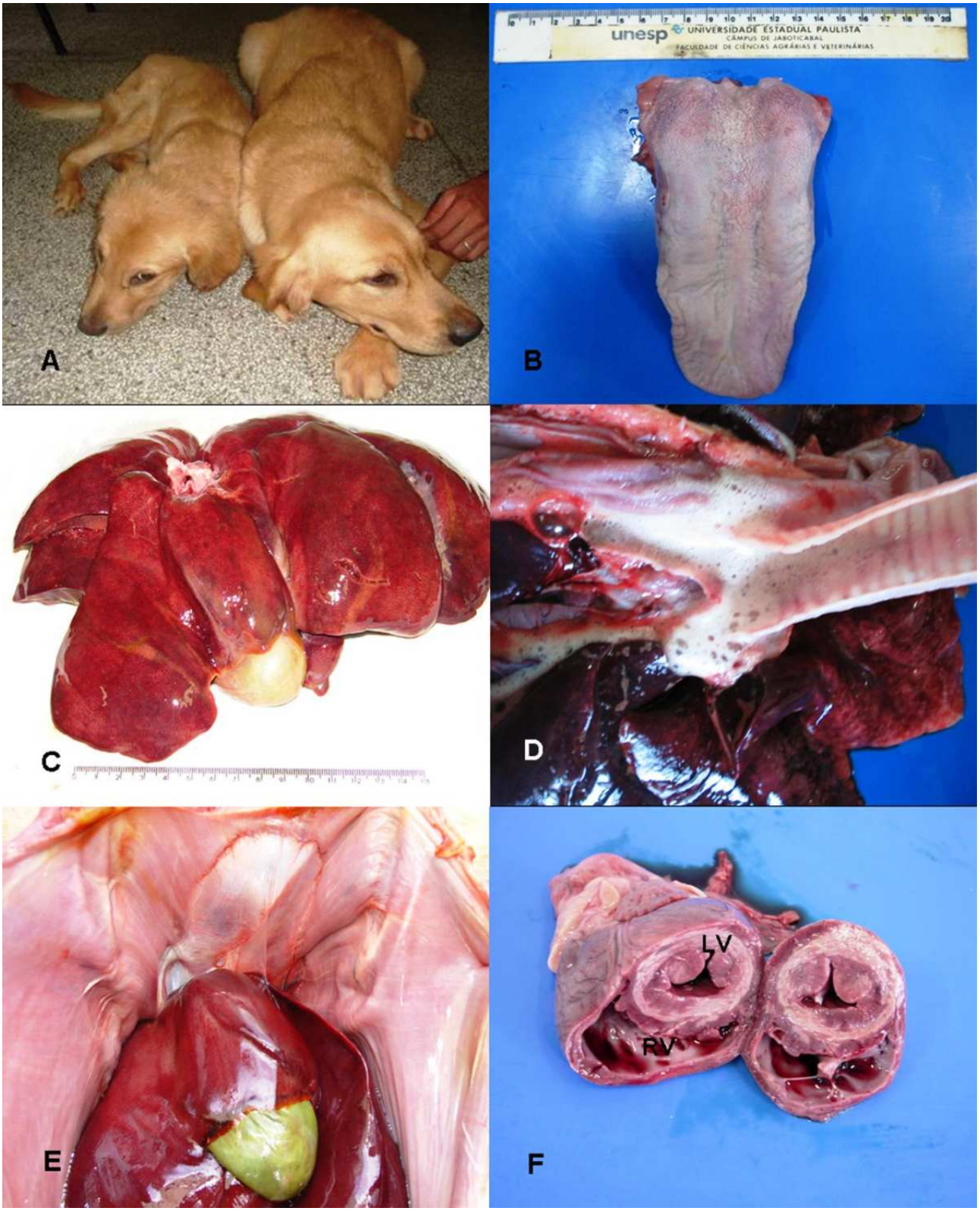

Figure 1. Gross morphology in Golden retriever dogs with muscular dystrophy. (A) Dogs with seven months of age that belong to the same breed. In the left an animal with muscular dystrophy and in the opposite side (right) a healthy animal. The affected animal exhibit markedly atrophied muscles. (B) Tongue with increased volume in animal with Muscular dystrophy. Note the base tongue with 11 cm of length. (C) Liver with increased volume, rounding of the margins, diffuse areas with yellowish coloring and congestion. The gallbladder is very dilated. (D) Presence of foam in the trachea. Lungs with increased volume and congested parenchyma. (E) Thickening of the diaphragm in the region of the pillars and thinning close to the tendon center. (F) Heart with increased volume, rounded and left concentric hypertrophy (LV). The right ventricle is dilated and thinned (RV).

 All rights reserved 2007.

There were collections of liquid (between 100 and 300 mL) in the thoracic and abdominal cavity in the animal after 7 months of age. These alterations indicated changes in the hemodynamic balance within the vascular compartment. Evaluation of the spleen demonstrated mild increased of volume after 8 months of age. No macroscopic alterations to the epiploon were identified in the dystrophic animals.

Analysis of the digestive system identified macroglossia, with protrusion of the tongue outside of the oral cavity after 8 months of age (Fig. 1B). In these same animals, the esophageal wall was two to three times more thickness. The stomach presented pallid mucosa, loss of stomach creases, petechial hemorrhages, ecchymosis and ulceration of the mucosa. The intestinal loops were hyperemic, dilated and full of pasty feces over their whole length, thus indicating decreased intestinal transit. No lesions were identified in these animals' pancreas. Evaluation of the liver detected increased volume, rounding of the edges, diffuse areas with yellowish coloring and congestion (Fig. 1C). The gallbladder was very dilated and filled with granular material in all the animals evaluated.

In the respiratory system, the presence of foam was detected in the trachea and bronchial tree of thirteen of the sixteen animals necropsied (Fig. 1D). The lungs of these same animals presented increased volume and firm consistency. The pulmonary parenchyma was congested, with liquid flowing when cut, and with the presence of areas of crepitation. The musculature of the diaphragm was hypertrophic in all affected animals. The thickening of the diaphragm occurred mainly in the region of the pillars. Close to the tendon center, the diaphragm became thinned, thus providing the conditions for diaphragmatic hernia to occur in three animals (19%) and its rupture in one animal (6%) (Fig. 1E).

Evaluation of the cardiac system identified significant abnormalities in fourteen (87.5%) of the sixteen animals. Increased volume and rounded shape were seen in these animals' hearts, and also left concentric hypertrophy (Fig. 1F). Its thickness was two to three times greater than that of the normal heart wall. The right ventricle was dilated and its wall was flaccid and thinned. Analysis of the genitourinary system showed congestion of the renal parenchyma, hyperemia of the vesicular and preputial mucosa in all the animals.

Histological features

Histopathological alterations were identified in the muscles from dystrophic dogs. We found hyalinized (dark) and necrotic fibers distributed throughout the endomysium as well inflammatory cells, particularly mononuclear (Fig. 2A). These alterations were present isolated or grouped. There were fiber size variation and regeneration fibers with small diameter, basophilic cytoplasm and large vesicular nuclei. Some myofibers had undergone dystrophic calcification. Interfascicular fatty infiltration was observed in some muscles, especially in the tongue.

Analysis of the digestive system showed inflammation of the mucosa, degeneration of stomach glands, hyperplasia of caliciform cells and waxy degeneration of smooth muscle (Fig. 2B). Necrosis was detected at the extremities of the villi of the intestinal loops in the dystrophic animals, and also hypertrophy of caliciform cells and Payer's plaques (Fig. 2C). Mononuclear inflammatory cells were seen in the mucosa and submucosa of intestines. Inflammatory cells associated with degenerating hepatic cells were distributed throughout the interstitium in the livers of all dystrophic dogs (Fig. 2D). Also, were found moderate to pronounced connective tissue and smooth muscle degeneration in the liver.

The respiratory system showed vascular congestion, edema and emphysema of pulmonary alveoli, and areas of hemorrhage. Inflammatory cells were present with different intensities and distribution, which characterized pneumonia (Fig. 2E). Thickening and necrosis of alveolar septa and presence of fibrin were also observed.

Analysis of the cardiac muscle tissue of the dystrophic animals revealed moderate to pronounced connective tissue, inflammatory cells, particularly mononuclear, degeneration, necrosis and some myofibers undergoing dystrophic calcification (Fig. 2F).

Evaluation of the splenic parenchyma demonstrated hyperplasia of follicles in ten animals (62.5%). The genitourinary system showed congestion, mononuclear inflammatory cells and moderate to severe degeneration of the nephrons. Mild inflammation and interstitial edema were seen in the bladder mucosa. The testicular interstice presented moderate to severe degeneration of the germinative lineage cells.

Discussion

In dystrophic dogs, the skeletal muscles were pale and atrophied due the histopathological alterations identified such as hyalinized (dark) and necrosed fibers, fiber size variation and, particularly, increased of connective tissue. These changes associated with the digestive problems resulted in cachexia with different intensities in all the dystrophic dogs.

Cardiac muscle involvement was found in 87,5% of the GRMD dogs resulting, however, in cardiac failure in only 18,8% of the animals. In human beings, progressive involvement of the left ventricle leads to abnormal wall movement and result in dilated cardiomyopathy in only 10-20% of patients. This phenomenon was verified in an animal (6,2%) with 51 months of age, because most of the animals died before reaching this age with pulmonary respiratory failure (16, 17, 19, 27, 37, 38, 39, 41). Interestingly, cardiac problems were not observed in the group with mild phenotype where the animals tolerated exercise better than others (3). In our GRMD dogs, the cardiac disease was responsible for collections of liquid (between 100 and 300 mL) in the thoracic and abdominal cavity in the animal after 7 months of age. As histological characteristics in cardiac tissue, we found the same changes that occur in human cardiac tissue (27).

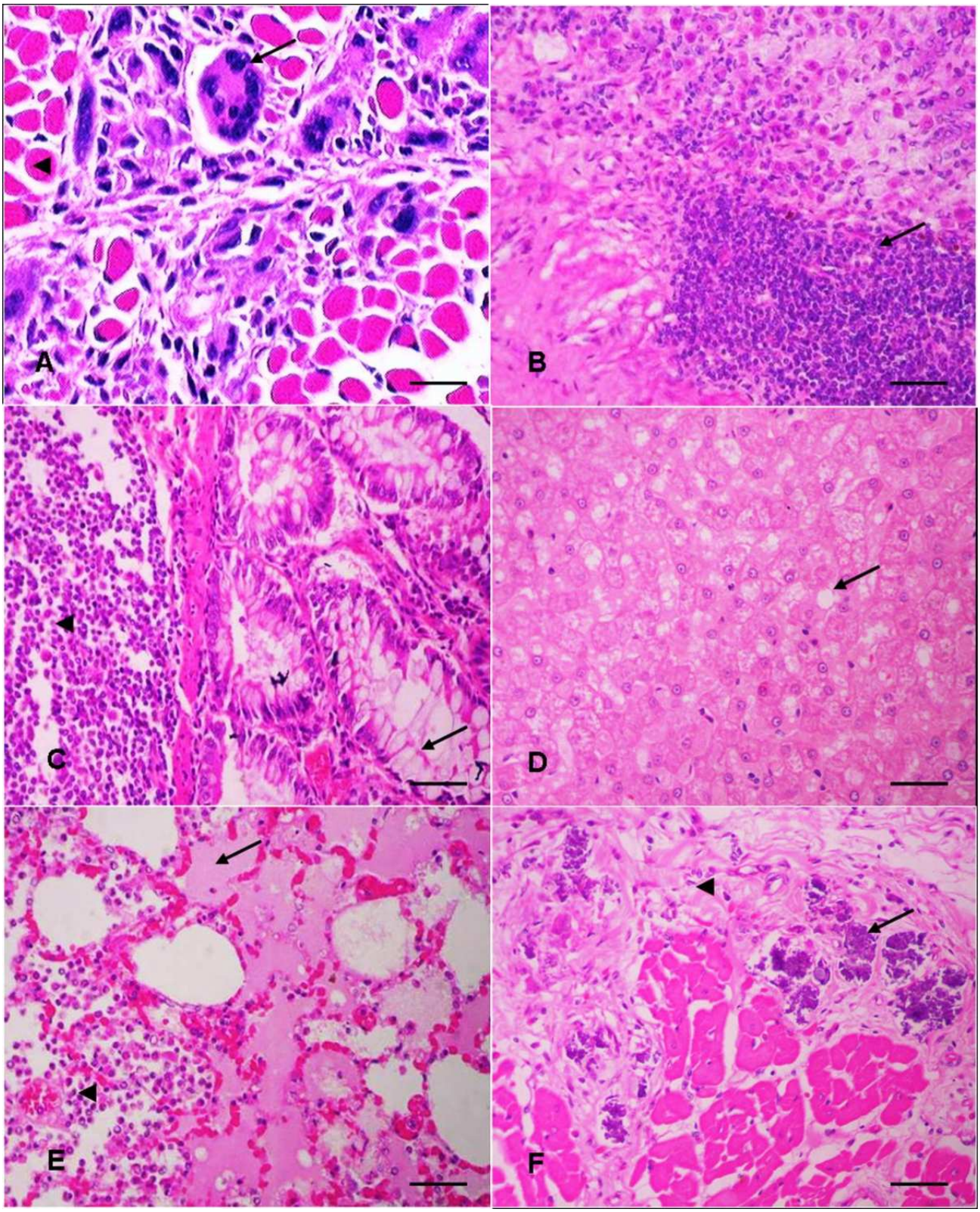

Figure 2. Histological features in Golden retriever dogs with muscular dystrophy. HE; Bar = 20 µm. (A) Diaphragmatic muscle: inflammatory cells, particularly giant cells (arrow), hyalinization (arrowhead) and hyperplasia of the perimysial and endomysial connective tissue can be observed. (B) Stomach: hyperplasia of lymphatic system in the submucosa (arrow) and presence of mononuclear cells in the mucosa. (C) Intestine: hypertrophy of caliciform cells (arrow) and Payer's plaques (arrowhead) can be observed at the intestinal loops. (D) Liver: degeneration moderate of the hepatic cells. Note the increased volume and presence of steatosis (arrow) in these cells. (E) Lung: vascular congestion, areas of edema (arrow) and intense inflammatory infiltrate (arrowhead) were present characterized pneumonia. (F) Heart: proliferation of connective tissue (arrowhead) and myofibers presenting calcification (arrow) can be observed in the areas with lesions.

The pulmonary abnormalities suggested pneumonia by aspiration of food. The dysphagia developed by the dystrophic dogs and demonstrated by macroglosia, thickening of the esophageal wall and reduction of muscles' movements was responsible for the inflammation of pulmonary parenchyma. The pneumonia is observed in 33% DMD patients (8). The musculature of the diaphragm was hypertrophic in all affected animals resulting in progressive respiratory muscle weakness and at later stages in respiratory failure (81,25%). The same phenomena are observed in humans with muscular dystrophy and are the commonest cause of death in Duchenne muscular dystrophy (8, 26, 36, 44).

In our study, the smooth muscle in the gastrointestinal tract of GRMD dogs (100%) showed affected agreeing with the findings described in human beings (12). In human beings (21% DMD patients), autopsy studies demonstrated the involvement of the gastrointestinal tract in muscular dystrophies that result in atrophy and thinning of the bowel wall (7, 25). These changes can lead to severe functional disturbances of the gastrointestinal tract with gastroparesis, acute gastric dilatation and intestinal pseudo-obstruction (4, 5, 9, 10, 31). In study were described microscopic alterations in the layer of smooth muscle of gastrointestinal tract of GRMD dogs. This layer lost their typical organization and revealed increased of connective tissue, being the damage to the smooth muscle of the stomach more severe than the intestine (20).

The liver abnormalities found in dystrophic dogs were originated mainly from heart disease and developed progressively. These findings were reinforced by others studies that mentioned the cardiac disease, increased of the age and congestion of hepatic venom system as responsible for the alterations in the liver (23, 41). In previous studies, evaluation of the liver detected increased volume in dystrophic dogs indicating that this change is a common finding (1, 23). Also, in our dogs the gallbladder was much dilated and full due to smooth muscle degeneration associated with replacement by connective tissue (23).

Regarding the urinary system, we observed GRMD dogs, similar to DMD patients, with full bladder, hyperemia of mucosa and granular material indicated changes in the functioning and emptying of that (8). In the reproductive system, the germinative lineage cells presented moderate to severe degeneration probably due to degeneration of the scrotum and cremaster muscle which prevented the proper thermo-regulation of the testicle.

Thus, our results reinforce the fact that there is significant impairment of the cardiac, respiratory and skeletal muscle systems in GRMD dogs from the age of five months. In addition, significant alterations of the gastrointestinal tract, urinary and reproductive systems are indicating the presence of degenerative lesions in the smooth musculature. Most studies so far have focused on the morphological aspects of the disease in Golden Retrievers with different ages in which this disease has been manifested. In the literature consulted there are few reports of systematic morphological studies that characterize muscle lesions during the evolution of the disease and its clinical manifestations through until adult age. For these reason, this study could give support in others studies and fill the gaps of knowledge about the disease.

Acknowledgments

The authors thank The State of São Paulo Research Foundation (FAPESP) for the financial support; The Veterinary Surgery Department, University of São Paulo (USP), Brazil; The School of Medicine, University of North Carolina (UNC), USA; Dr. Joe N. Kornegay, Mr. José Alexandre M. Pigatto, Mrs. Maria Ines Y. de Campos and Mrs. Francisca A. Ardison for technical assistance.

References

1. ALVES FR., FEITOSA MLT., GATTI A., FADEL L., UNRUH SM., AMBRÓSIO CE., STERMAN FA., PINTO ACBCF., MIGLINO M.A. Imagem radiográfica da cavidade torácica de cães Golden Retriever acometidos pela Distrofia Muscular. Pesq. Vet. Bras., 2009, 29, 99-104.
2. AMBRÓSIO CE., VALADARES MC., ZUCCONI E., CABRAL R., PEARSON PL., GAIAD TP., CANOVAS M., VAINZOF M., MIGLINO MA., ZATZ M. Ringo, a Golden Retriever muscular dystrophy (GRMD) dog with absent dystrophin but normal strength. Neuromuscul. Disord., 2008, 18, 892–3.
3. AMBRÓSIO CE., FADEL L., GAIAD TP., MARTINS DS., ARAÚJO KPC., ZUCCONI E., BROLIO MP., GIGLIO RF, MORINI A.C., SANTOS TC., JAZEDJE, T., FROES T.R., FEITOSA MLT, VALADARES M., BELTRÃO-BRAGA PCB, MEIRELLES FV, MIGLINO MA. Identification of three distinguishable phenotypes in golden retriever muscular dystrophy (GRMD). Genet. Mol. Res., 2009, 8, 389-96.
4. BAROHN RJ., LEVINE EJ., OLSON JO., MENDELL JR. Gastric hypomotility in Duchenne's muscular dystrophy. N. Engl. J. Med., 1988, 319, 15–8.
5. BENSEN ES., JAFFE KM., TARR PI. Acute gastric dilatation in Duchenne muscular dystrophy: a case report and review of the literature. Arch. Phys. Med. Rehabil., 1996, 77, 512–14.
6. BERGMAN RL., INZANA KD., MONROE WE., SHELL LG., LIU LA., ENGVALL E., SHELTON GD. Dystrophin-deficient muscular dystrophy in a Labrador retriever. J. Am. Anim. Hosp. Assoc., 2002, 38, 255-61.
7. BEVANS M. Changes in the musculature of the gastrointestinal tract and in the myocardium in

 All rights reserved 2007.

progressive muscular dystrophy. Arch. Pathol., 1945, 40, 225–38.
8. BOLAND BJ, SILBERT, PL., GROOVER RV., WOUAN PC., SILVERSTEIN MD. Skeletal, Cardiac, and Smooth Muscle Failure in Duchenne Muscular Dystrophy. Pediatr. Neurol., 1996, 14, 7-12.
9. CHUNG BC., PARK HJ., YOON SB., LEE HW., KIM KW., LEE SI., PARK IS. Acute gastroparesis in Duchenne's muscular dystrophy. Yonsei Med. J., 1998, 39, 175–79.
10. CROWE GG. Acute dilatation of stomach as a complication of muscular dystrophy. Br. Med. J., 1961, 5236, 1371.
11. CULLEN MJ., MASTAGLIA FL. Morphological changes in dystrophic muscle. Br. Med. Bull., 1980, 36, 145-52.
12. DINAN D., LEVINE M.S., GORDON A.R., RUBESIN S.E., ROMBEAU J.L. Gastric Wall Weakening Resulting in Separate Perforations in a Patient with Duchenne's Muscular Dystrophy. AJR, 2003, 181, 807-808.
13. DUCHENNE GBA. Recherches sur la paralysie musculaire pseudo-hypertrophique ou paralysie myo-sclérosique. Archives Générales de Médecine, 1868, 11, 5-25, 179-209, 305-321, 421-443, 552-588.
14. EAGLE M., BAUDOUIN SV., CHANDLER C., GIDDINGS DR., BULLOCK R., BUSHBY K. Survival in Duchenne muscular dystrophy: improvements in life expectancy since 1967 and the impact of home nocturnal ventilation. Neuromuscul. Disord., 2002, 12, 926-29.
15. ERVASTI JM., OHLENDIECK K., KAHL SD., GAVER MG., CAMPBELL KP. Deficiency of a glycoprotein component of the dystrophin complex in dystrophic muscle. Nature, 1990, 345, 315-319.
16. FARAH MG, EVANS EB, VIGNOS PJJR. Echocardiographic evaluation of left ventricular function in Duchenne's muscular dystrophy. Am. J. Med., 1980, 69, 248-54.
17. FINSTERER J., STÖLLBERGER C. The heart in human dystrophinopathies. Cardiology, 2003, 99, 1-19.
18. FLETCHER S., CARVILLE KS., HOWELL JM., MANN CJ., WILTON SD. Evaluation of a short interspersed nucleotide element in the 3' untranslated region of the defective dystrophin gene of dogs with muscular dystrophy. Am. J. Vet. Res., 2001, 62, 1964-68.
19. FRANKEL KA., ROSSER RJ. The pathology of the heart in progressive muscular dystrophy: epimyocardial fibrosis. Hum. Pathol., 1976, 7, 375-86.
20. GERGER AAC., SOUZA CC., MARTINS DS., GAIAD T., BRÓLIO MP. LUPPI MR., AMBRÓSIO CE., MIGLINO MA. Changes of the digestive tract of Golden Retriever dogs affected by muscular dystrophy. Pesq. Vet. Bras., 2010, 30, 1064-70.
21. GILROY J., CAHALAN JL., BERMAN R., NEWMAN M. Cardiac and pulmonary complications in Duchenne's progressive muscular dystrophy. Circulation, 1986, 27, 484-93.
22. GOWERS WR. Clinical lectures on pseudo-hypertrophic muscular paralysis. Lancet, 1879, 2, 1-2, 37-39, 73-75, 113-116.
23. GRANDO AP., MARIANA ANB., MIGLINO MA., STERMAN FA., ZATZ M., KANAYAMA LM., FEITOSA MLT., MARTINS DS., MORINI AC., PASSOS J., FADEL L., AMBRÓSIO CE. Ultra-sonografia abdominal e pélvica em cães da raça golden retriever sadios, portadores e afetados pela distrofia muscular progressiva. Ciência Rural, 2009, 39, 123-8.
24. HONEYMAN K., CARVILLE KS., HOWELL JM., FLETCHER S., WILTON SD. Development of a snapback method of single-strand conformation polymorphism analysis for genotyping Golden Retrievers for the X-linked muscular dystrophy allele. Am. J. Vet. Res., 1999, 60, 734-37.
25. HOWELL JM., KAKULAS BA., PASS DA., GENOVESE L., JOHNSEN R., LLOYD F., HOBLEY W.E. The fulminating neonatal form of expression in the golden retriever dog model of Duchenne muscular dystrophy. VIII International Congress on Neuromuscular Diseases, New York, The American Association of Electrodiagnostic Medicine, 1994, Supplement 1, S182.
26. HUVOS AG., PRUZANSKI W. Smooth muscle involvement in primary muscle disease. II. Progressive muscular dystrophy. Arch. Pathol., 1967, v.83, 234-40.
27. INKLEY CR., OLDENBURG FC., VIGNOS PL. Pulmonary function in Duchenne muscular dystrophy related to stage of disease. Am. J. Med. 1974, 56, 297–306.
28. JAMES TN. Observation on the cardiovascular involvement, including the cardiac conduction system, in progressive muscular dystrophy. Am. Heart J. 1962, 63, 48-56.
29. KOENIG M., HOFFMAN E.P., BERTELSON C.J., MONACO AP., FEENER C., KUNKEL L.M. Complete cloning of the Duchenne muscular dystrophy (DMD) cDNA and preliminary genomic organization of the DMD gene in normal and affected individuals. Cell, 1987, 50, 509–17.
30. KORNEGAY JN., CUNDIFF DD., BOGAN DJ., BOGAN JR., OKAMURA CS. The cranial sartorius muscle undergoes true hypertrophy in dogs with golden retriever muscular dystrophy. Neuromuscul. Disord., 2003, 13, 493-500.
31. KORNEGAY JN., TULER SM., MILLER DM., LEVESQUE DC. Muscular dystrophy in a litter of golden retriever dogs. Muscle Nerve, 1988, 11, 1056-64.
32. LEON SH., SCHUFFLER MD., KETTLER M., ROHRMANN C. Chronic intestinal pseudoobstruction as a complication of Duchenne's muscular dystrophy. Gastroenterology, 1986, 90, 455–59.
33. MIYAZATO LG., MORAES JR., BERETTA DC., KORNEGAY JN. Muscular Dystrophy in Dogs: Does the Crossing of Breeds Influence Disease

Phenotype? Vet Pathol., 2011, January 13. Accessed on March 06, 2011. Online: http://vet.sagepub.com/content/early/recent#content-block

34. MOISE NS., VALENTINE BA., BROWN CA., ERB HN., BECK KA., COOPER BJ., GILMOUR RF. Duchenne's cardiomyopathy in a canine model: electrocardiographic and echocardiographic studies. J. Am. Coll. Cardiol., 1991, 17, 812-20.
35. MOSER H. Duchenne muscular dystrophy: pathogenetic aspects and genetic prevention. Hum. Genet., 1984, 66, 17-40.
36. MUKOYAMA M., KONDO K., HIZAWA K., NISHITANI H. Life spans of Duchenne muscular dystrophy patients in the hospital care program in Japan. J. Neurol. Sci., 1987, 81, 155-158.
37. NEWSOM-DAVIS J. The respiratory system in muscular dystrophy. Br. Med. Bull., 1980, 36, 135–8.
38. NIGRO G., COMI LI., POLITANO L., BAIN RJI. The incidence and evolution of cardiomyopathy in Duchenne muscular dystrophy. Int. J. Cardiol. 1990, 26, 271-7.
39. PERLOFF JK., DE LEON ACJR., O'DOHERTY D. The cardiomyopathy of progressive muscular dystrophy. Circulation, 1966, 33, 625-48.
40. PERLOFF JK., ROBERTS WC., DE LEON ACJR., O'DOHERTY D. The distinct electrocardiogram of Duchenne's progressive muscular dystrophy. An electrocardiographic-pathologic correlative study. Am. J. Med., 1967, 42, 179-88.
41. SAMIEL HV. Genetic surgery for muscular dystrophy in golden retrievers. Genome News Network, June, 2000. Accessed on 2003. Online: http://www.genomenewsnetwork.org/articles/06_00/muscular_dystrophy.shtml.
42. SANYAL SK., JOHNSON WW., THAPAR MK., PITNER SE. An ultrastructural basis for electrocardiographic alterations associated with Duchenne's progressive muscular dystrophy. Circulation, 1978, 57, 1122-1129.
43. SHARP NJH., KORNEGAY JN., VAN CAMP SD., HERBSTREITH MH., SECORE SL., KETTLE S., HUNG WY., CONSTANTINOU CD., DYKSTRA MJ., ROSES AD., BARTLETT RJ. An error in dystrophin mRNA processing in golden retriever muscular dystrophy, an animal homologue of Duchenne muscular dystrophy. Genomics, 13, 115-121, 1992.
44. SHELTON GD., LIU LA., GUO LT., SMITH GK., CHRISTIANSEN JS., THOMAS WB., SMITH MO., KLINE KL., MARCH PA., FLEGEL T., ENGVALL E. Muscular dystrophy in female dogs. J. Vet. Intern. Med., 2001, 15, 240-44.
45. SMITH PEM., CALVERLEY PMA., EDWARDS RHT., EVANS GA., CAMPBELL EJM. Practical problems in the respiratory care of patients with muscular dystrophy. N. Engl. J. Med., 1987, 316, 1205–10.
46. VALENTINE BA., COOPER BJ., CUMMINGS JF., DE LAHUNTA A. Canine X-Linked muscular dystrophy: morphologic Lesions. J. Neurol. Sci., 1990, 97, 1-23.
47. VALENTINE BA., COOPER BJ., DE LAHUNTA A., O'QUINN R., BLUE JT. Canine X-linked muscular dystrophy. An animal model of Duchenne muscular dystrophy: clinical studies. J. Neurol. Sci., 1988, 88, 69-81.
48. VALENTINE BA., COOPER BJ. Canine X-linked muscular dystrophy: selective involvement of muscles in neonatal dogs. Neuromuscul. Disord., 1991, 1, 31-8.
49. VALENTINE BA., CUMMINGS JF., COOPER BJ. Development of Duchenne-type cardiomyopathy. Morphologic studies in a canine model. Am. J. Pathol. 1989, 135, 671-8.
50. VALENTINE BA., WINAND NJ., PRADHAN D., MOISE NS., DE LAHUNTA A., KORNEGAY JN., COOPER BJ. Canine X-linked muscular dystrophy as an animal model of Duchenne muscular dystrophy: a review. Am. J. Med. Genet., 1992, 42, 352-6.
51. VALENTINE BA., COOPER BJ., CUMMINGS JF., DELAHUNTA A. Progressive muscular dystrophy in a golden Retriever dog: light microscope and ultrastructural features at 4 and 8 months. Acta Neuropathol., 1986, 71, 301-10.
52. ZUCCONI E., VALADARES MC., VIEIRA NM., BUENO JRCR., SECCO M., JAZEDJE T., SILVA HCA., VAINZOF M., ZATZ M. Ringo: discordance between the molecular and clinical manifestation in a Golden Retriever muscular dystrophy dog. Neuromuscul. Disord., 2010, 20, 64–70.