BJVP
Brazilian Journal of Veterinary Pathology

Original Full Paper

Evaluation of Intracellular Calcium in Golden Retriever Muscular Dystrophy

Ligia G. Miyazato[1], Daniel C. Beretta[1], Jair R. Engracia-Filho[2], Flavio R. Moraes[1], Julieta R. E. Moraes[1]

[1]Departamento de Patologia Veterinária, Unesp - São Paulo State University, Jaboticabal, São Paulo, Brazil.
[2]Centro Universitário Barão de Mauá, Ribeirão Preto, São Paulo, Brazil.
Corresponding author: Dr. Julieta R.E. Moraes - Department of Veterinary Pathology, Unesp - São Paulo State University. Via Paulo Donato Castelanne s/n 14884-900, Jaboticabal, São Paulo, Brazil. Tel: +55 16 3209-2662. Fax: +55 16 3202-4275.
E- mail: julietaengracia@gmail.com

Submitted December 13th 2010, Accepted March 31st 2011

Abstract

The present study had the objective of evaluating calcium accumulations in muscle fibers and their correlation with the canine muscular dystrophy. After the deaths of the animals (13 dystrophic and 3 non-dystrophic), samples of the skeletal muscles were collected. The material was stained with hematoxylin-eosin, Gomori's modified trichrome and alizarin red S technique (pH 4.3). The histopathological changes were analyzed and the proportions of calcium-positive (CPF) and negative muscle fibers were evaluated. Histopathological changes such as muscle fiber diameter changes, necrosis, hyalinization, presence of inflammatory infiltrate and fatty atrophy were identified in all the dystrophic muscles. Statistically significant differences in numbers of CPF between dystrophic muscles and non-dystrophics were observed for the masseter (6%), brachial biceps (5%) and triceps, sartorius and femoral biceps (4%) muscles. The identifying calcium is of interest as a parameter for helping in diagnostic screening.

Key Words: canine muscular dystrophy, intracellular calcium, Duchenne muscular dystrophy

Introduction

Muscular dystrophy in Golden Retrievers is a hereditary degenerative disease with muscle alterations similar to those described for Duchenne muscular dystrophy in humans. It consists of disorders linked to the X chromosome that result from mutations in the gene for dystrophin, which is a structural membrane protein (4, 9, 15). The stress caused by muscle contraction/tension induces rupturing of the plasmatic membrane, which has become fragile because of the absence of dystrophin, thus resulting in release of muscle enzymes, influx of extracellular fluid and increases in intracellular calcium concentration. This process activates endogenous proteases, which starts the process of muscle fiber degeneration. Furthermore, calcium may also accumulate inside the mitochondria, which causes a severe energy deficit inside the muscle fibers and, in some cases, muscle fiber death (5).

It is known that calcium accumulation precedes degeneration and necrosis of muscle fibers, while the proportion of this ion is very variable. However, high calcium concentrations can be noted before clinical manifestations of the disease (7).

Measurements of total calcium concentration in the musculature of dystrophic mice of different ages have shown that total calcium becomes acutely elevated during the necrosis period (21-28 days of age) and returns to normal during the subsequent regenerative phase (40 days of age) (19). According to these authors, loss of homeostasis of muscular calcium in MDX mice is a secondary consequence of degeneration of skeletal muscles, and the organelles responsible for pathological buffering of cytoplasmic calcium are the mitochondria (19).

In cases of muscular dystrophy in Golden Retrievers, the calcium concentration is increased, particularly in the subsarcolemmal region. The

 All rights reserved 2007.

ultrastructural findings include dilatation of the sarcoplasmic reticulum, hypercontraction of the Z band and degeneration of subsarcolemmal areas (24). Small foci of completely mineralized muscle fiber lesions, and also endomysial and perimysial fibrosis and marked muscle fiber atrophy, are also observed (5, 15).

The hyper contraction induced by increases in intracellular calcium may result in large dark fibers (hyalinized fibers) that can be seen under an optical microscope, thus indicating that calcium has a primary role in inducing fiber necrosis (23).

Intracellular calcium is identified by means of 2 staining methods: Von Kossa and alizarin red S (ARS). Von Kossa demonstrates the bonds between the anion (carbonate or phosphate) and the cation (calcium). ARS marks calcium directly: in frozen tissue sections, ARS staining at pH 4.2 marks calcium ions (1).

The use of routine staining such as hematoxylin-eosin does not allow identification of calcium accumulations in degenerative processes in the musculature. The qualitative analysis of the lesion is insufficient for identifying prior alterations in the skeletal musculature resulting from breakdown of calcium homeostasis.

Cytochemical analysis using special staining techniques such as ARS help in diagnosing and morphologically characterizing the lesions. Positive calcium findings can therefore be utilized as a marker for acute muscle injury, especially those mediated by damage to the plasmatic membrane (23).

The objectives of this study were to morphologically characterize the presence of calcium in Golden Retrievers with muscular dystrophy and correlate this with lesions in normal and degenerated skeletal muscles.

Materials and Methods

Experimental design

Thirteen male Golden Retrievers affected by muscular dystrophy and 3 healthy animals that were negative for muscular dystrophy were used, with ages ranging from 1 to 51 months. The presence of this disease was confirmed by DNA analysis on leukocyte broth, which was performed at the Human Genome Study Center in São Paulo and at the AADM Gene Therapy Center in Ribeirão Preto, and by determination of the serum activity level of the enzyme creatine kinase (CK) (11).

The animals were classified as non-dystrophic or dystrophic, based on 2 simultaneous complementary criteria: genotypic analysis and serum CK levels.

Serum creatine kinase concentration

Serum samples were obtained from all the animals by means of venous puncture, just after their birth and monthly until they died. For the present study, the last analysis before their death was used. For the non-dystrophic dogs, the samples were collected just before death.

The CK catalysis was determined by means of an enzymatic kit. The reaction consisted of CK catalysis that transferred the phosphate group of creatine phosphate to adenosine diphosphate, thus resulting in adenosine triphosphate. This adenosine triphosphate concentration was then determined by using two associated reactions: catalysis using hexokinase and glucose-6-phosphate dehydrogenase, to produce nicotinamide adenine dinucleotide (NADH) (13, 18).

Analysis of genomic DNA

The genomic DNA was analyzed at the Human Genome Study Center. To perform the analyses, DNA was extracted from blood samples collected from the recently born Golden Retrievers and Labrador Retrievers, using a commercial kit. The genotypes of the dystrophic and non-dystrophic dogs were determined using the primers GF2 and GR1 (10, 21). The primer GF2 (5'- CTT AAG GAA TGA TGG GCA TGG G – 3') corresponded to the base pairs 135-114 of the canine dystrophin gene, while the primer GR1 (5'- TGC ATG TTC CAG TCG TTG TGT GGC – 3') corresponded to the base pairs 805-782. The PCR product containing Sau 961 (the position created by gene mutation in the dystrophin gene) was digested, subjected to electrophoresis and viewed on 1.2% agarose gel with ethidium bromide.

To characterize the defect in GRMD, a single filament of dystrophin cDNA was amplified after extraction from the skeletal muscles of the non-dystrophic and dystrophic dogs. Specific oligonucleotides were used in separate reactions to provide reverse transcription of the complete canine RNA. All the primers used in the PCR reaction were based on the cDNA sequence of human dystrophin and had been adequately proven for amplification of all the segments of the mRNA of canine dystrophin. After purification, the resultant cDNA was subjected to amplification by means of PCR, using the original reverse oligonucleotide sequence paired with 1 of the forward oligonucleotide sequences (F1 or F2) (20). The PCR amplification products were viewed in 1.2% agarose gel with ethidium bromide and subsequent hybridization using dystrophin cDNA from human skeletal muscles (12).

Collection and processing of muscle samples

The dystrophic muscles were collected no more than 12 hours after the deaths of these animals. Eight muscles were evaluated: masseter, costal portion of the diaphragmatic muscle, brachial biceps, long head of the brachial triceps, cranial belly of the sartorius, semitendinosus, semimembranosus and superficial head of the femoral biceps. The samples of the muscles from the non-dystrophic animals were collected immediately after they were sacrificed using endovenous thiopental anesthetic and potassium chloride.

The fragments were collected from the medial portion of the muscles. Some of the material was fixed in 10% buffered formol solution. This was then processed by means of the usual techniques for embedding in paraffin, and sections of thickness 3 μm

were cut. At least 2 sections were mounted on histological slides and stained using hematoxylin-eosin (HE) and Gomori's modified trichrome (GMT).

The remainder of the fragments were immersed in N-hexane, frozen in liquid nitrogen and stored in a freezer at –80°C. Subsequently, the fragments were cut into serial transverse sections of thickness 8µm using a cryostat at –20°C and were mounted on glass slides using 10% polylysine. Following this, the sections were stained using the ARS technique at pH 4.3 (modified McGee-Russell).

Fragments that contained artifacts from freezing or processing were discarded so as not to compromise the analysis of the muscle fibers or make it impossible.

Qualitative analysis

To characterize the histopathological changes, a qualitative analysis method taking into consideration the percentage of altered muscle fibers in relation to the muscle band was used (15).

Four lesion grades were defined, according to the extent of muscle fiber damage presented on the sections stained with HE and GMT:
Grade 0: muscle presenting the same histological characteristics as seen in muscles without the presence of abnormalities;
Grade 1: mild lesions: isolated damaged muscle fibers presenting random distribution;
Grade 2: moderate lesions: damaged muscle fibers in groups, presenting multifocal distribution and affecting 10-50% of the fibers in each muscle band;
Grade 3: severe lesions: coalescing or diffuse damaged muscle fibers affecting more than 50% of the fibers in each muscle band.

Evaluation of intracellular calcium

Alizarin Red S (ARS) is particularly used in histological sections for staining accumulations of intracellular calcium in degenerative processes in the musculature. The intracellular calcium is stained in orangish-red (1). By using the ARS staining (pH 4.3), the relative proportions of calcium-positive muscle fibers (staining orangish-red) and calcium-negative fibers (remaining unstained) in the 8 muscles of the 2 groups (dystrophic and non-dystrophic) were evaluated.

A total of 200 muscle fibers were evaluated at random from each muscle sample: 117 samples were analyzed, and therefore 23,400 fibers were evaluated. Qualitative analysis was performed with the aid of an image analysis system (KS 100 version 3.0 – Kontron – Carl Zeiss). The images were obtained using a video camera (Color Video Camera TK-1070U-JVC) connected to a binocular microscope (Jenaval - Carl Zeiss) that was coupled to a microcomputer.

Statistical evaluation

Firstly, descriptive analysis of the variable was performed in relation to the relative proportions of calcium-positive and negative fibers, and means and standard deviations were calculated for the dystrophic and non-dystrophic groups.

Subsequently, the counts of calcium-positive and negative fibers were subjected to the Kolmogorov-Smirnov test of goodness of fit to the normal distribution curve (2). Differences in the observed measurements were inferred by means of the Mann-Whitney U test, using a significance level of 5% for the dystrophic and non-dystrophic groups.

The calculations and analyses were carried out using the SPSS statistical package (Statistical Package for Social Sciences – version12.0 – LEAD Technologies, Inc. – 2003).

Results

Qualitative analysis

The muscles of the non-dystrophic dogs presented normal histological characteristics: uniformly distributed fibers in polyhedral format interspersed with connective tissue.

Histopathological alterations were identified in all the muscles evaluated in the dystrophic animals of different ages. HE staining showed changes in muscle fiber diameters, to varying degrees (Fig. 1a). Necrosis was seen as separated occurrences or grouped (Fig. 1c). Hyalinization (Fig. 1e) and phagocytosis were present (Fig. 1c). Inflammatory cells, particularly of mononuclear type, were seen to be distributed throughout the interstices (Fig. 1c). Dystrophic calcification was observed as focal lesions (Fig. 1d), and an abundance of adipose tissue was seen in some muscles (Fig. 1b).

The GMT staining showed exuberant perimysial and endomysial connective tissue (Fig. 1f). The fibers showed up with bluish staining ad, at the most marked lesion grade (grade 3), they were reddish-blue. The staining was located at cell borders or diffusely throughout the sarcoplasm, thus showing a necrosis process.

All the muscles evaluated, except for the masseter, presented greatest frequency of lesion grade 3 (Table 1). Therefore, we could see that the lesions in the dystrophic musculature were very severe and were distributed diffusely in the muscle bundles. The brachial biceps and semitendinosus muscles were the ones most affected among all the muscles evaluated.

Characterization of the calcium-positive muscle fibers in the dystrophic dogs

Using the ARS technique, the staining pattern for calcium-positive fibers was a deep red color distributed homogeneously throughout the sarcoplasm (Fig. 2d) or concentrated at the cell borders (Fig. 2b-c).

Calcium-positive fibers were occasionally identified using the ARS technique in the muscles of the non-dystrophic animals. In the dystrophic animals, calcium-positive fibers were markedly present in all the muscles evaluated, independently of age or lesion grade. The calcium-positive fibers presented grouping within the muscle bundles, with strong staining and in numbers ranging from 2 to 20 fibers (Fig. 2a).

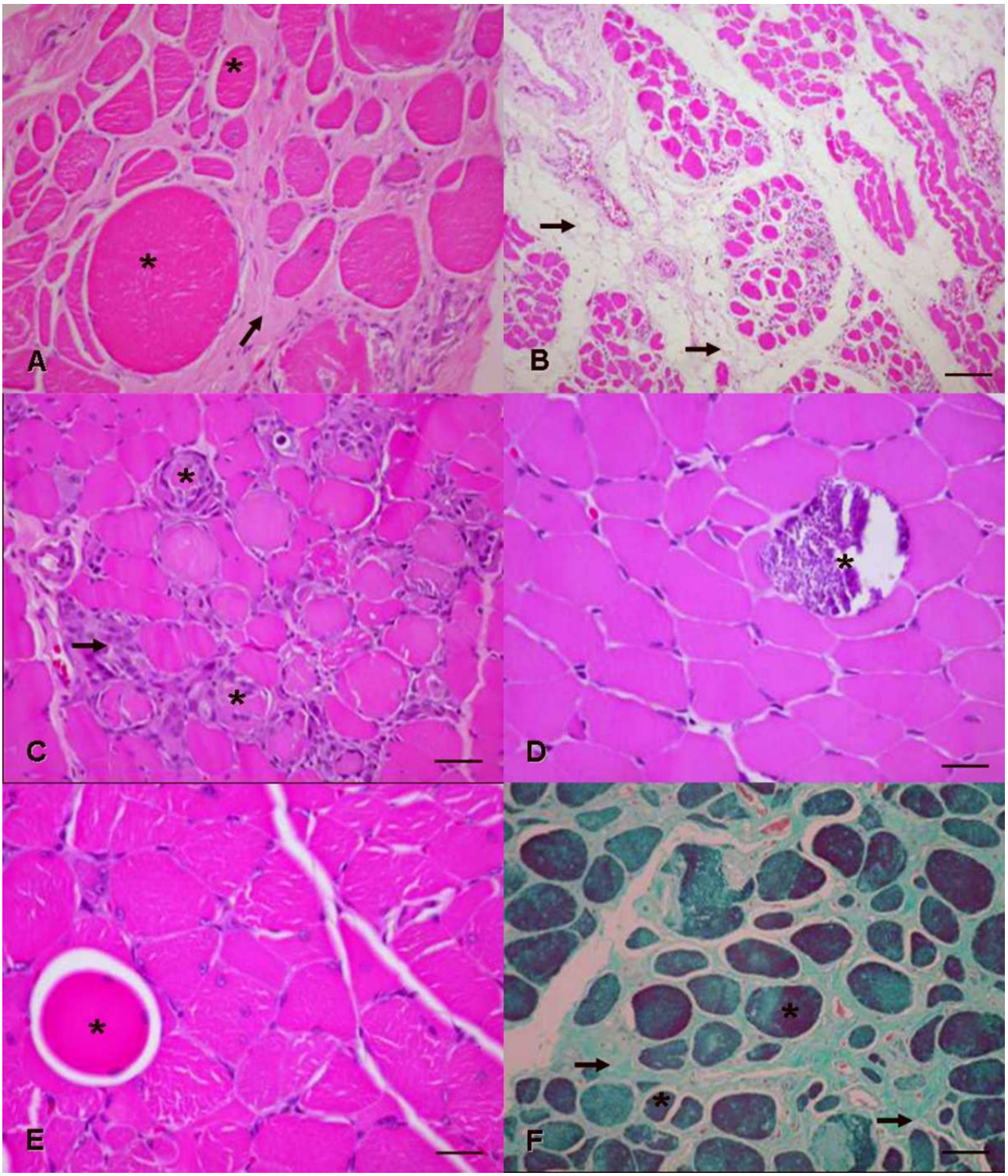

Figure 1. Histopathological changes in muscles of dystrophic dogs. (A) Diaphragm: changes in muscle fiber diameters (*) and hyperplasia of the perimysial and endomysial connective tissue (arrow). Scale bar, 25 µm. HE (B) Brachial biceps: abundance of adipose tissue (arrow). Scale bar, 50 µm. (C) Masseter: presence of inflammatory cells (arrow), phagocytosis (*) and necrosis of fibers. Scale bar, 12,5 µm. HE. (D) Masseter: dystrophic calcification of muscle fiber. Scale bar, 12,5 µm. HE. (E) Brachial triceps: hyalinization of muscle fiber (*). Scale bar, 12,5 µm. HE. (F) Semitendinosus: changes in muscle fiber diameters (*) and hyperplasia of the perimysial and endomysial connective tissue (arrow). Scale bar, 25 µm. GMT.

Brazilian Journal of Veterinary Pathology. www.bjvp.org.br . All rights reserved 2007.

Table 1: Frequencies (%) of lesions grades found in the Golden Retrievers affected by muscular

Muscle	Grade 1	Grade 2	Grade 3
Masseter	11	67	22
Diaphragm	10	10	80
Brachial biceps	10	30	60
Brachial triceps	0	0	100
Semitendinosus	0	14	86
Semimembranosus	0	0	100
Femorarl biceps	0	12	88
Sartorius	0	13	87

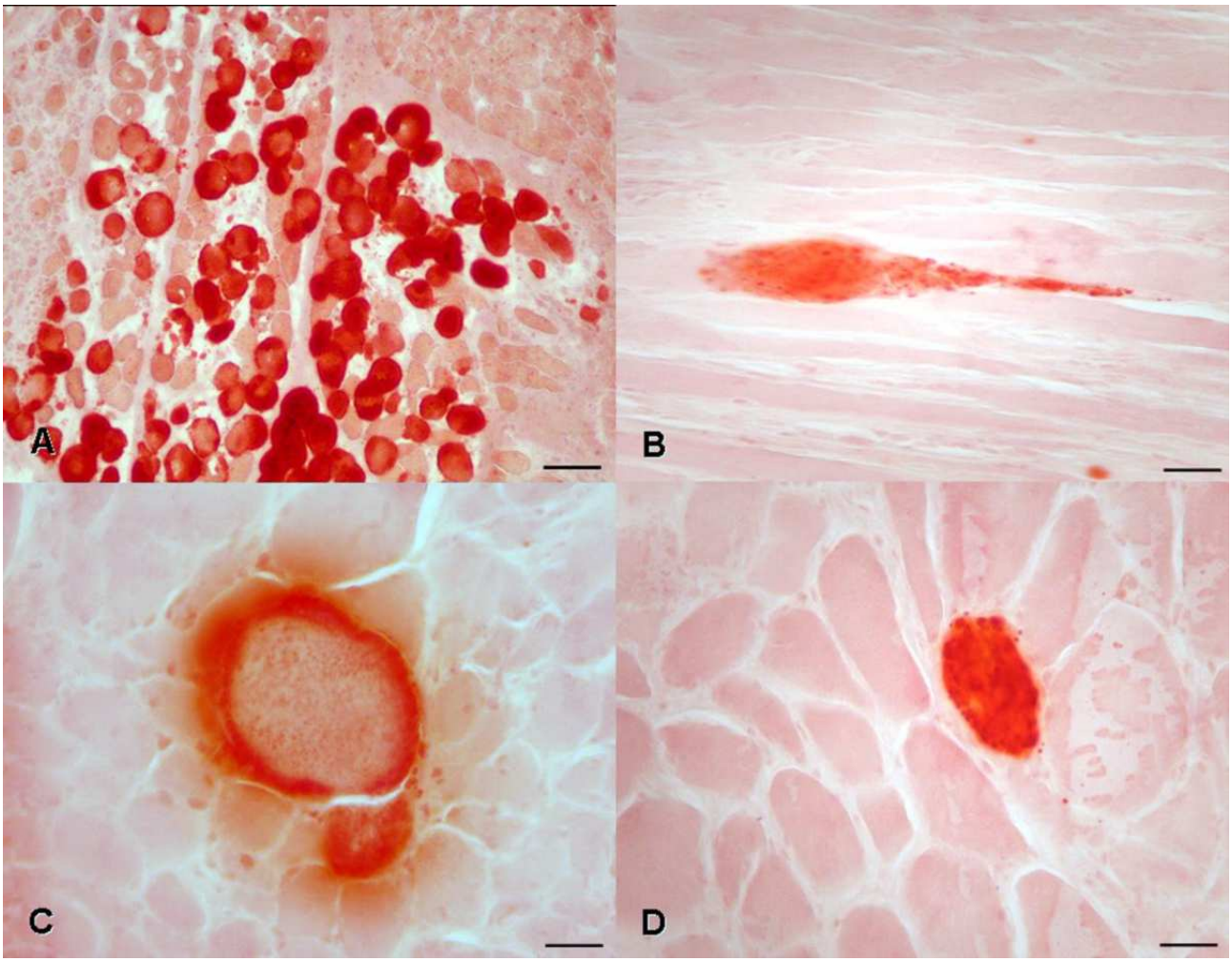

Figure 2. Photomicrograph of muscles of dystrophic dogs stained with alizarin red S (pH 4.3) (A) Masseter: intracellular calcium accumulation presented in foci of grouped necrosis. Scale bar, 50 µm. (B) Brachial biceps: aspect of the calcification of fiber in longitudinal section. Note the partially calcified in a segmental of fiber. Scale bar, 25 µm. (C) Brachial biceps: excessive amount of intracellular calcium concentrated at the cell borders, under the sarcolemma. Scale bar, 25 µm. (D) Brachial biceps: aspect of an isolated fully calcified myofiber. Scale bar, 25 µm.

Evaluation of intracellular calcium

The calcium-positive and negative fibers were quantified and analyzed by descriptive statistics, for all the muscles selected in the dystrophic and non-dystrophic animals. Means and frequencies (%) were calculated (Table 2).

Statistical analysis of the calcium-positive fibers showed that there was a significant difference ($\rho<0.05$) between the dystrophic and non-dystrophic groups for 5 muscles: masseter, brachial biceps and triceps, femoral biceps and sartorius. The marking for calcium did not show any statistically significant difference in relation to the diaphragmatic, semimembranosus and semitendinosus muscles (Table 3).

Table 2: Absolute values of the means and frequencies (%) for the calcium-positive and negative fibers of the Golden Retriever affected by muscular dystrophy and the unaffected animals

Muscle	CNF				CPF			
	affected		unaffected		affected		unaffected	
	mean	(%)	mean	(%)	mean	(%)	mean	(%)
Masseter	188	94.0	194	97.0	12	6.0	06	3.0
Diaphragm	190	95.0	198	99.0	10	5.0	02	1.0
Brachial biceps	190	95.0	199	99.5	10	5.0	01	0.5
Brachial triceps	192	96.0	199	99.5	08	4.0	01	0.5
Semitendinosus	191	95.5	199	99.5	09	4.5	01	0.5
Semimembranosus	191	95.5	200	100.0	09	4.5	01	0.0
Femoral biceps	192	96.0	199	99.5	08	4.0	01	0.5
Sartorius	192	96.0	199	99.5	08	4.0	01	0.5

CNF: calcium negative fibers; CPF: calcium positive fibers.

Table 3: Coefficient values from the Mann –Whitney U test for calcium positive e negative fibers of Golden Retriever affected or unaffected muscular.

Muscle	Coefficient from the Mann –Whitney U test
Masseter	0.027
Diaphragm	0.099*
Brachial biceps	0.022
Brachial triceps	0.008
Semitendinosus	0.060*
Semimembranosus	0.054*
Femoral biceps	0.049
Sartorius	0.023

* Non-significant at 5% probability level

Discussion

The role of calcium in cell injury and death has motivated many studies over recent years. It has been scientifically proven that defects in calcium homeostasis are closely involved in cell death (8, 22).

The distribution of calcium in muscle cells under normal and pathological conditions suggests that increases in intracellular calcium are involved in fiber necrosis. This characteristic is shown in spontaneous and experimentally induced myopathy (3, 16, 25, 26). In muscular dystrophy cases, calcium has a fundamental role in explaining the physiopathogenesis of the disease. In Duchenne muscular dystrophy, fiber necrosis and calcium accumulations in degenerated fibers are observed (3, 6, 7, 14).

Although intracellular calcium increases are nonspecific, the cytochemical staining techniques for calcium help in diagnosing cases of necrosis and skeletal muscle disorders (3). It has been observed that there is significantly greater presence of calcium-positive fibers in Duchenne muscular dystrophy in humans that in other types of myopathy (3).

Among the different types of muscle disorder in dogs, calcium-positive fibers are frequent findings in masticatory myositis and muscle dystrophy. These fibers are seen to be normal or present atrophy, thus indicating that the initial accumulation of this ion may demonstrate early degenerative alterations that are not visible under an optical microscope (23). This confirms the results from the present study, in which muscle fibers (whether degenerated or not) were shown to be calcium-positive in the different dystrophic muscles evaluated, independent of the lesion grade.

In our study, we found significant increases in the numbers of calcium-positive fibers, in relation to most of the muscle studied in the dystrophic dogs (masseter, brachial biceps and triceps, femoral biceps and sartorius), thus confirming that breakdown of calcium homeostasis is associated with serious degenerative lesions. In many types of myopathy and in muscular dystrophy, particularly the Duchenne type, it has been proposed that calcium increases are the result from primary defects of the plasmatic membrane (3, 6, 7, 25). There is also evidence for dysfunction in the sarcoplasmatic reticulum (6).

In the literature consulted there are few reports of studies of morphological studies that characterize muscle lesions during the evolution of the disease and calcium accumulations in degenerated fibers until adult age. Most of the studies are based on assaying the calcium concentrations in dystrophic muscle cells and do not emphasize the morphological aspects of the disease. For these reasons, this study could give support

 All rights reserved 2007.

in others studies and use the cytochemical staining techniques for calcium as a tool in the diagnosis of muscular dystrophies.The extent of calcification is in fact a histological parameter of interest for furthering the evaluation of the disease.

Acknowledgments

The authors thank The State of São Paulo Research Foundation (FAPESP), for financial support (process 07/58360-1), The Veterinary Surgery Department, University of São Paulo (USP), Brazil; The School of Medicine, University of North Carolina (UNC), USA; Dr. Joe N. Kornegay, Mr. José Alexandre M. Pigatto, Mrs. Maria Ines Y. de Campos and Mrs. Francisca A. Ardison for technical assistance.

References

1. Bancroft JD, Stevens A In: Bancroft JD, Gamble M (ed) Theory and practice of histological techniques. Edinburgh, Churchill Livingstone., 1982, p 800.
2. Bisquerra RF, Sarriera JC, Martínez F. In: Bisquerra RF, Sarriera JC, Martínez F (ed) Introdução à Estatística – *enfoque* informático com o pacote estatístico SPSS. Porto Alegre, Artmed, p 255, 2004.
3. Bodensteiner MD, Engel AG. Intracellular calcium accumulation in Duchenne dystrophy and other myopathies: A study of 567,000 muscle fibers in 114 biopsies. Neurol., 1978, 28:439-446.
4. Cooper BJ, Winand NJ, Stedman H, Valentine BA, Hoffman EP, Kunkel LM, et al. The homologue of the Duchenne locus is defective in X-linked muscular dystrophy of dogs. Nature., 1988, 334:154-156.
5. Cozzi F, Cerletti M, Luvoni GC, Lombardo R, Brambilla PG, Faverzani S, et al. Development of muscle pathology in canine X-linked muscular dystrophy. II. Quantitative characterization of histophatological progression during postnatal skeletal muscle development. Acta Neurophatol., 2001, 101:469-478.
6. Cullen MJ, Mastaglia FL. Morphological changes in dystrophic muscle. Br Med Bull., 1980, 36:145-152.
7. Emery AEH, Burt D. Intracellular calcium and pathogenesis and antenatal diagnosis of Duchenne muscular dystrophy. Br Med J., 1987, 280:355-357.
8. Faber JL. Membrane injury and calcium homeostasis in the pathogenesis of coagulative necrosis. Lab Invest., 1982, 47:114-122.
9. Hoffman EP, Brown RH, Kunkel LM (1987) Dystrophin: the protein product of the Duchenne muscular dystrophy locus. Cell., 1987, 51:928-929.
10. Honeyman K, Carville KS, Howell JM, Fletcher S, Wilton SD (1999) Delopment of a snapback method of single-strand conformation polymorphism analysis for genotyping Golden Retrievers for the X-linked muscular dystrophy allele. AJVR., 1999, 60:734-737.
11. Howell, JM, Fletcher S, Kakulas BA, O´Hara M, Lochmuller H, Karpati G. Use of the dog model for Duchenne muscular dystrophy in gene therapy trials. Neuromuscul Disord., 1997, 7:325-328.
12. Koenig M, Monaco AP, Kunkel LM. The complete sequence of dystrophin predicts a rod-shaped cytoskeletal protein. Cell.,1988, 53:219-228.
13. Martínez-Amat A, Boulaiz H, Prados J, Marchal JA, Puche PP, Caba O, et al. Release of actin into serum after skeletal muscle damage. Br J Sports Méd., 2005, 39:830-834.
14. Mendell JR, Higgins R, Sahenk Z, Cosmos E (1979) Relevance of genetic animal models of muscular dystrophy to human muscular dystrophies. Ann NY Acad Sci., 1979, 317:409-430.
15. Nguyen F, Cherel Y, Guigand L, Goubault-leroux I, Wyers M. Muscle lesions associated with dystrophin deficiency in neonatal Golden Retriver puppies. J Comp Pathol., 2002, 126:100-108.
16. Oberc MA, Engel WK. Ultrastructural localization of calcium in normal and abnormal skeletal muscle. Lab Invest., 1977, 36:566-577.
17. Putchtler H, Susan NM, Mary ST. On the history and mechanism of alizarin and alizarin red S stains for calcium. J Histochem Cytochem., 1969, 17:110-124.
18. Raphael J, Rivo J, Gozal Y. Isoflurane-induced myocardial preconditioning is dependent on phosphatidylinositol-3-kinase/Akt signalling. Br J Anaesth., 2005, 95:756-763
19. Reeve JL, McArdle A, Jackson MJ. Age-related changes in muscle calcium content in dystrophin-deficient mdx mice. Muscle Nerve, 1997, 20:357-360.
20. Saiki RH, Gelfand DH, Stofell S, Scharf SJ, Higuchi R, Horn GT, et al. Primer-directed enzymatic amplification of DNA with a thermostable DNA polymerase. Science., 1988, 239:487-491.
21. Sharp NJH, Kornegay JN, Van Camp SD, Herbstreith MH, Secore SL, Kettle S, et al. An error in dystrophin mRNA processing in golden retriever muscular dystrophy, an animal homologue of Duchenne muscular dystrophy. Genomics., 1992, 13:115-121.
22. Trump BF, Berezesky IK. The role of calcium desregulation in cell injury and cell death (introduction). Surv Synth Pathol Res., 1983, 2:165-169.
23. Valentine BA, Cummings JF, Cooper BJ. Development of Duchenne-type cardiomyopathy: Morphologic studies in a canine model. Am J Pathol., 1989, 135:671-678
24. Valentine BA, Cooper BJ, Cummings JF, de Lahunta A. Canine X-Linked Muscular Dystrophy: Morphologic Lesions. Neurol Sci., 1990, 97:1-23.

 All rights reserved 2007.

25. Wrogemann K, Jacobson BE, Blanchaer MC (1973) On the mechanism of a calcium-associated defect of oxidative phosporylation in progressive muscular dystrophy. Arch Biochem Biophys 159:267-278

26. Yoshimura, T, Sujihata M, Satoh A, Mori M, Hazama R, Kinoshita N, et al. Ultrastructural study of the effect of calcium ionophore, A23187, on rat muscle. Acta Neuropathol., 1986, 69:184-192.

Brazilian Journal of Veterinary Pathology. www.bjvp.org.br . All rights reserved 2007.