BJVP
Brazilian Journal of Veterinary Pathology

Case Report

Renal Cell Carcinoma with Cutaneous Metastasis in a Dog

Pablo H. Carvalho[1], Lissandro G. Conceição[1], Tatiana Shmitz Duarte[1], Maria Cristina Ferrarini Nunes Soares Hage[1], Márcia S. Barros[1], José C. L. Moreira[1], Renée L. Amorim[2], Pedro Pinczowski[2]

[1]Departamento de Veterinária – Universidade Federal de Viçosa.
[2]Faculdade de Medicina Veterinária e Zootecnia – Universidade Estadual Paulista – UNESP/Botucatu.
Corresponding author: Lissandro G. Conceição - Departamento de Veterinária, Universidade Federal de Viçosa, Av. P.H. Rolfs, s/n, Campus Universitário, CEP 36570-000, Viçosa, Minas Gerais – Brazil.

Submitted February 11th 2011, Accepted June 6th 2011

Abstract

The present report describes the occurrence of skin metastasis in a dog with primary renal carcinoma. The clinical findings included progressive weight loss, inappetence, palpable abdominal mass and cutaneous tumor. The histopathological examination was carried out after unilateral nephrectomy and was confirmed by immunohistochemistry. The immunohistochemical and histopathological findings characterized this case as renal cell carcinoma with skin metastasis.

Key Words: diseases of dogs**,** skin metastasis, renal tumors, immunohistochemistry, renal carcinoma

Introduction

Secondary (metastatic) skin neoplasm are uncommon to rare in dogs. Mammary adenocarcinoma is the tumor most likely to metastasize within skin (34), but gastrointestinal and vascular tumors and melanomas are also reported in dogs and cats (32).

Primary renal tumors are uncommon in dogs and cats (1,3,11,31). Their frequency in dogs represents 0,3 to 1,0% of all primary neoplasm reports (1,16,21) and 1,5 to 2,5% in cats (11). However, a wide variety of tumors occur in the kidneys (28), and malignant tumors are the most frequent in both species (10,11,23). In human medicine, kidney tumors are very relevant because they correspond to 3% of malignancies in adults, with high mortality rate (8,22,25).

Renal neoplasms commonly occur in aged animals (14,17), with an average age of onset of eight years (1,3,11). However, undifferentiated nephroblastomas and renal sarcomas may occur more frequently in young dogs and cats (7). Apparently, there is sexual bias, with a male x female ratio of 1.8:1, described in dogs with primary renal cell carcinoma (11,13,19). Similarly, the ratio in humans is 1.5: 1 (18). Although renal tumors may appear in the renal epithelium, renal mesenchyme or embryonic tissues (3), 85.2% of the cases are of epithelial origin (11,23). Most malignant tumors reported in dogs are tubular cell carcinoma, cystadenocarcinoma, squamous cell carcinoma, transitional cell carcinoma of the pelvis and nephroblastoma (11,17). However, in cats lymphoma is the most common renal neoplasm (7,23). Although malignant tumors are more frequent, benign renal tumors can also occur, and adenomas are the most common. Hemangiomas, papillomas, lipomas, fibromas, neurofibromas and oncocytomas are occasionally reported in dogs and cats (14,17).

The present case demonstrates a complex renal carcinoma with skin metastasis in a German Shepherd dog and presents additional discussion on metastatic skin and renal tumors in dogs.

Case Report

A seven-year-old male German shepherd dog was presented to the Hospital Veterinário of the Universidade Federal de Viçosa with the main complaint of chronic weight loss, apathy and a skin

 All rights reserved 2007.

mass localized in the right thorax. According to the owner, despite the animal was eating normally, weight loss had been observed for six months.

On physical examination, the patient was alert, emaciated, and a non- ulcerated, normochromic and haired skin tumor was seen in the right shoulder. The mass had five centimeters in diameter, was well circumscribed, firm and without pain evidence on palpation. In the abdominal palpation, it was observed a mass of about 15 cm in diameter, in the mesogastric region, with a painful reaction.

With the clinical suspicion of a neoplastic lesion, complete blood count (CBC), urinalysis, serum biochemistry, electrolytes profile, abdominal and thoracic roentgenograms and fine needle aspiration of the skin tumor for cytological examination were required.

No significant changes were observed in the hematocrit, red blood cells counts, hemoglobin concentration, MCV, MCH and MCHC. The total protein was slightly raised (8.2 g/dL). A slight neutrophilic leukocytosis (16,400/ mm^3) with relative (15%), but not absolute (2,460p/mm^3) eosinophilia was seen. Biochemical and electrolyte profile were within normal range. The urinalysis was not performed due to poor sample preservation.

The cytological assessment of the skin nodule presented a large number of epithelial cells with clear criteria of malignancy, including anisocytosis and anisokaryosis, nuclear basophilia and increased nucleus/cytoplasm ratio.

The radiological examination of the abdomen, in both lateral and ventrodorsal projections, revealed a radiopaque spherical mass. No evidences of lung metastasis were observed in the chest X-rays.

With the presumptive diagnosis of neoplastic disease, the dog was submitted to exploratory celiotomy which revealed a mass of about 12 cm in diameter, firm, not attached to the abdominal wall and intensely vascularized involving the entire right kidney. A total unilateral nephrectomy, with exeresis of regional lymph node was performed. No macroscopic focus of metastasis was observed in the abdominal cavity. The excisional biopsy of the skin nodule was also performed for histopathogical diagnosis. Unfortunately, half an hour after the surgical procedure, the animal had a cardiopulmonary arrest unresponsive to the standard cardiopulmonary resuscitation maneuver and died.

Macroscopically, the abdominal mass was firm, brown in color and measured 12,5 x 11,0 x 10,8 cm. The skin tumor was soft, light-brown and measured 6,5 x 6,0 x 4,8 cm. Representative fragments of both tumor were fixed in 10% buffered formalin and submitted for histopathological and immuhistochemistry diagnosis.

Microscopically, it was observed loss of the normal renal parenchyma architecture, with a narrow band of peripherically dislodged cortical tissue containing colapsed glomeruli (Figure 1). Some areas of preserved tubular structure, diffuse necrosis, hemorrhage and mild polymorphonuclear inflammatory infiltration were also found (Figure 2A). The epithelial cells had a tubulopapillary arrangement and the cells showed oval nuclei and light eosinophilic cytoplasm. The mitotic activity was low (Figure 2B). Based on the histological findings, tubulo-papillary renal cell carcinoma and collecting duct carcinoma were diagnosed. According to the World Health Organization (WHO), it was classified as undifferentiated renal carcinoma.

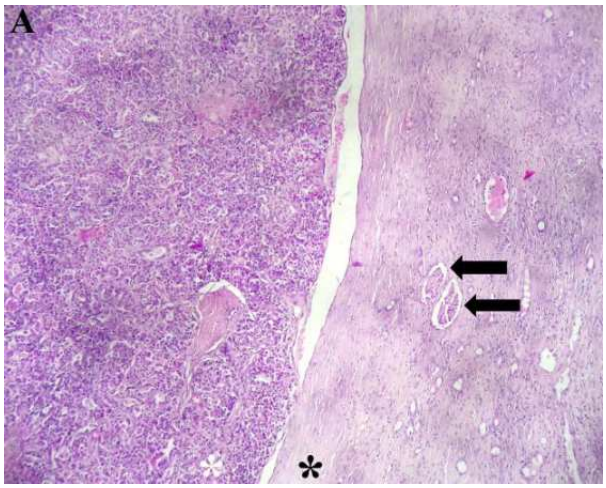

Figure 1. Renal cortico-medullary transition evidencing the neoplastic mass (white asterisk) and renal cortex (black asterisk) with collapsed glomeruli (arrows) (H&E, 40X).

The skin tumor had essentially the same histopathological alterations as described above confirming a cutaneous metastasis from a primary renal tumor (Figure 3A and 3B).

The antibodies used in the immunohistochemical analysis were: cytokeratin AE1/AE3 (dilution 1:50), high molecular weight cytokeratin 34BE12 (1:50), low weight cytokeratin (7), Vimentin (1:50) and EMA (clone E-29, 1:100).

The samples were incubated overnight and submitted to antigen retrieval with citrate at pH 6.0 for 30 minutes in water bath. The Envision Dual Link System (Dako) and DAB chromogen were used for amplification, for 1 hour and 5 minutes, respectively. The specimens were counter-stained with hematoxylin for 30 seconds.

The fragment of renal mass and skin nodule presented the same pattern of immunohistochemical staining, according to table1.

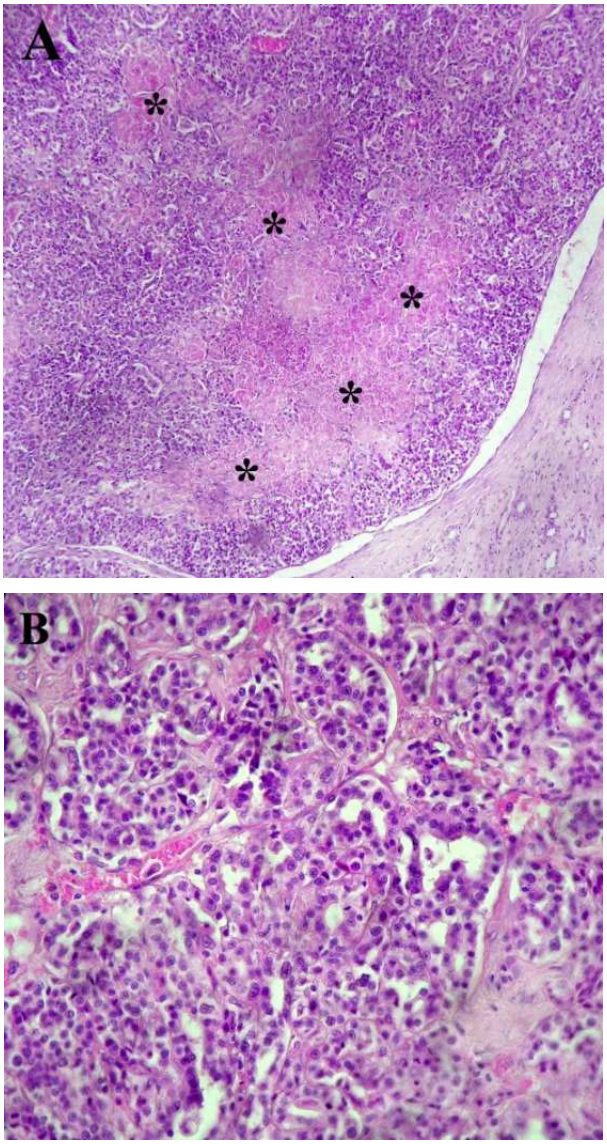

Figure 2. A. Renal mass presenting high cell density, with diffuse necrosis (asterisk) and hemorrhage (H&E, 40X). B. Cuboidal cells with basophilic cytoplasm, arranged in tubular structures (H&E, 400X).

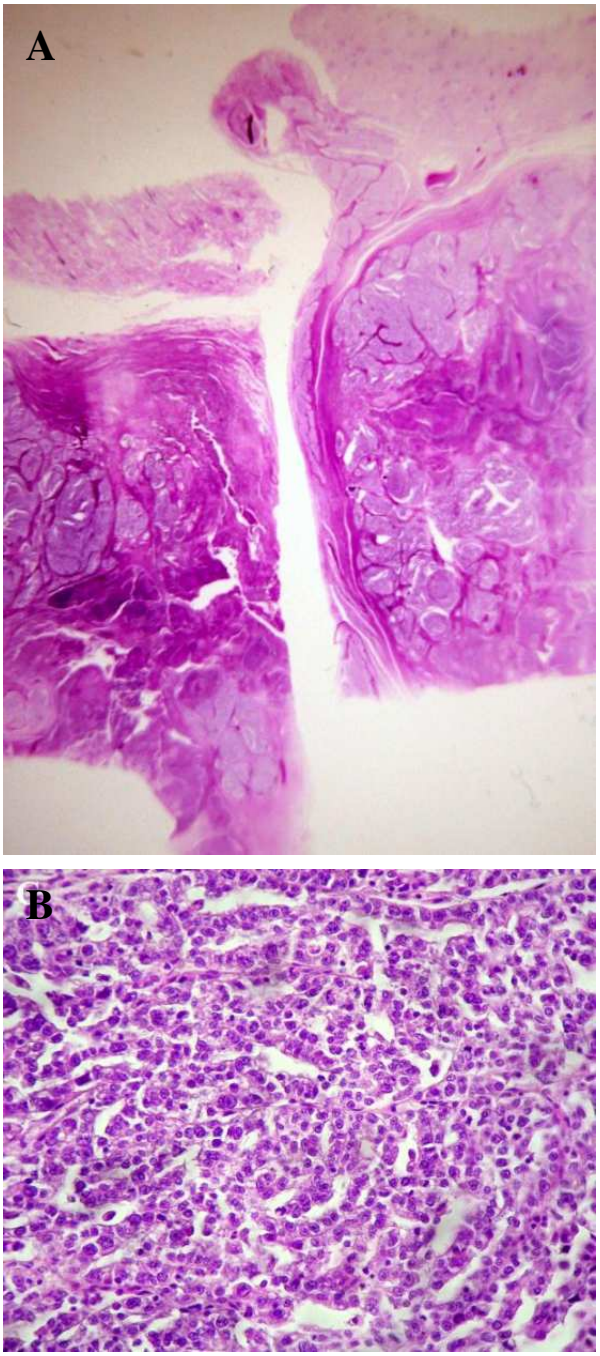

Figure 3. A. Neoplastic process involving the subcutaneous tissue. (H.E, 40X). B. Cuboidal cells with basophilic cytoplasm, arranged in tubular structures like the renal mass (H&E, 400X).

Table 1. Immunohistochemical findings of the of renal and skin samples

Antibodies	**AE1/AE3**	**CK7**	**High molecular weight cytokeratin**	**Vimentin**	**EMA**
Renal and skin masses	Positive with weak and diffuse reaction	Positive with weak and diffuse reaction	Negative	Negative	Positive with intense and diffuse reaction

Brazilian Journal of Veterinary Pathology. www.bjvp.org.br . All rights reserved 2007.

The diagnosis of renal cell carcinoma with skin metastasis was confirmed, but definitive classification was not possible, so undifferentiated renal carcinoma was the final diagnosis.

Discussion

Unequivocally, this report describes the occurrence of cutaneous metastatic lesion in a dog caused by primary renal cancer. Secondary (metastatic) skin neoplasm are uncommon to rare in dogs. Besides mammary adenocarcinomas, other neoplasms that may metastasize to the skin include, colonic, jejunal and pancreatic ductal adenocarcinomas, visceral hemangiosarcomas, oral melanomas and prostatic carcinoma (32). Specific and non specific cutaneous signs of leukemia cutis were also reported in dogs (32).

At first glance, on physical examination, adnexal follicular tumor and a metastatic skin tumor were the main differential diagnosis of the case described here. Skin metastasis from colonic, jejunal and pancreatic carcinomas usually are manifested as multiple papules and nodules, localized mainly on the ventral abdomen and inguinal region (32). Additionally, gastrointestinal signs are frequently present in these cases (11). Non solar-induced hemangiosarcomas are usually solitary, may occur on the trunk, but are poorly circumscribed, bleed easily and are dark red to violaceous in color. Hemorrhage and ulceration are common features of dermal or subcutaneous hemangiosarcomas (32). Melanomas are usually solitary, may occur in the trunk (32), and the color of the tumor may vary from jet black to a non pigmented red nodule (9).

There are no data on the occurrence of skin metastasis from kidney neoplasms in veterinary medicine, except for a short report in a textbook (12). In human medicine, however, skin is a common site for RCC metastasis (26).

Unilateral renal involvement and malignancy observed in this present case were also reported to be more common in dogs with kidney neoplasm (3,10, 19, 25,30). In most cases, the clinical signs presented by dogs with RCC are nonspecific and include apathy, anorexia, weight loss, hematuria, palpable abdominal mass, polydipsia, vomiting and diarrhea (1,3,12,18). The case presented here also showed some of these clinical signs, which are generally non specific and common to other neoplastic process. The suspicion of a malignant neoplastic epithelial lesion occurred after the cytologic evaluation of the skin nodule.

The reported case did not present significant hematological changes, except for relative eosinophilia, which could be explained due to intestinal parasitism or a paraneoplastic syndrome (2). The first one could also explain the presence of loose stools reported by the owner.

Hematuria, pyuria, proteinuria and isosthenuria are the most frequently abnormalities observed in urinalysis (3,7). In human beings, the macroscopic hematuria is more often associated with the carcinoma of the renal pelvis. Our patient did not present macroscopic hematuria, but microscopic hematuria could not be evaluated due to the loss of urine sample. However it is interesting to note that hematuria is reported not to be common in dogs with RCC (18), in contrast of which is observed in human medicine (24).

The most common sites of metastases from renal tumors in dogs are lungs, lymph nodes, bones and liver (3,5,10,12,26,27), however a cutaneous metastasis was present in this case.

In human medicine, 10% of the tumors of the genitourinary tract may develop skin metastasis (31), and the skin is the region most affected by RCC metastasis (26,27).

It is interesting to mention one aspects of this case: the presence of cutaneous tumor and absence of complains regarding to urogenital disorder. The clinical condition of oligosymptomatic RCC with manifestation of skin metastasis seems to be rare in either veterinary or human medicine. RCC usually presents hematuria as the main clinical manifestation in human beings (6,29).

Skin metastasis as a marker of the visceral disease means that the disease is advanced, with worse prognosis (17,26,31). This was the case here, since all right kidney was affected by the neoplasm. Local extension to the adrenal gland occurs in approximately 4% in humans. Extension to the adrenal gland, cava and mesenteric veins occasionally occurs in humans (20). Although there may be invasion of the renal vein in dogs, metastasis may not occur (12). In this case, despite the advanced cancer, these structures were not compromised, and the skin nodule was the only lesion regarded as metastatic.

According to the World Health Organization (WHO), RCC can be histologically classified as: clear cell carcinoma, papillary carcinoma, chromophobe cell carcinoma, collecting duct carcinoma and undifferentiated carcinoma (24,28). These variants can be usually differentiated on HE staining (28). Immunohistochemical examination may offer additional benefit for distinguishing renal carcinomas and defining the origin of some metastatic carcinomas (4,12,24,33). However, because of the lack of a specific cell marker, a panel of antibodies should be used and analyzed in an algorithm model, to achieve an indication of the most probable diagnosis or primary sites (4).

The most used markers in the RCC are vimentin, S100 protein, cytokeratin AE1/AE3 and CD10. Several cytokeratins have also been used, according to the histological classification (5,16,33). The renal cell papillary carcinoma typically are positive for vimentin, cytokeratin (CK 8/18, 19, 7), and epithelial membrane antigen (EMA) (4). The collecting duct carcinoma seems to originate from the distal nephron and shows characteristics between the renal cell carcinoma and renal pelvis carcinoma, coexpressing CK8/18, 19 and vimentin, but it is negative for CK13 (4).The immunohistochemical results obtained in the present case was not useful to distinguish the type of renal carcinoma as it is described in human medicine.

Due to the aggressiveness and malignancy of renal tumors and the fact that these are rarely diagnosed early, the prognosis is poor and the mortality rate is high (10,14,15). Survival after diagnosis is 16 months and, after surgery, six to eight months (1,10). The prognosis is good only in cases without metastasis, for unilateral tumors that can be completely removed at surgery (1,14). In this case, although the patient's anesthetic risk was high because of poor general condition, there were no intraoperative anesthetic complications. The death occurred during recovery from anesthesia, but the cause of the death was not determined, since necropsy was not allowed.

References

1. BENNETT F. Unilateral renal cell carcinoma in a Labrador retriever. Can. Vet. Journal, 2004, 45, 860–862.

2. BERGMAN PJ. Paraneoplastic syndromes. In: WITHROW SJ., VAIL DM. Small animal clinical oncology. St Louis: Saunders Elsevier, 2007, 77-94.

3. BRYAN JN., HENRY CJ., TURNQUIST SE., TYLER JW., LIPTAK JM., RIZZO SA., SFILIGOI G., STEINBERG SJ., SMITH AN., JACKSON T. Primary renal neoplasia of dogs. Journal. Vet. Intern. Med., 2006, 20, 1150-1160.

4. CAVALCANTE, FBC., ,ALVES VAF. Tumores Urológicos. In: ALVES VAF., BACCHI CE., VASSALLO J. - Manual de Imuno Histoquímica**.** São Paulo : Sociedade Brasileira de Patologia, 1999, 47-54.

5. CHIANG YC., LIU CH., HO SY., LIN CT., YEH L.S. Hypertrophic osteopathy associated with disseminated metastases of renal cell carcinoma in the dog: a case report. Journal Vet. Med. Sci., 2007, 69, 209-212.

6. EKE N., EGHWRUDJAKPOR P., ECHEM RC. Renal cell carcinoma presenting as a scalp swelling. Niger J. Med., 2003, 12, 154-156.

7. FOSSUM TW. Neoplasias renais e ureterais. In: FOSSUM TW. Cirurgia de Pequenos Animais, 2.ª ed., São Paulo : Roca, 2005, 567-571.

8. FREITAS VR., MOURA RA. Carcinoma metastático de células renais para a coróide - Relato de caso. Rev. Bras. Oftal., 2004, 63, 365-368.

9. GOLDSCHIMIDT MH., SHOFER FS. Skin tumors of the dog and the cat. 1st ed. Oxford: Pergamon Press, 1992.

10. GRILLO TP., BRANDÃO, CVS., MAMPRIM MJ., JESUS CMN., SANTOS, TC., MINTO BW. Hypertrophic osteopathy associated with renal pelvis transitional cell carcinoma in a dog. Can. Vet. Journal, 2007, 48, 745-747.

11. GUILFORD WG., STROMBECK DR. Neoplasms of the gastrointestinal tract, APUD tumors, endocrinopathies and the gastrointestinal tract. In: GUILFORD WG., CENTER SA., STROMBECK DR., WILLIAMS DA., MEYER DJ. Strombeck's Small Animal Gastroenterology. 3rd ed. Philadelphia: W.B. Saunders Company, 1996: 519-531.

12. JUBB KVF. Urinary System – renal neoplasia. In: Jubb, Kennedy and Palmer's Pathology of Domestic Animals. 5th ed., Saunders, 2007, 498-502.

13. KIM HL., SELIGSON D., LIU X. Using tumor markers to predict the survival of patients with metastatic renal cell carcinoma. J. Urol., 2005, 173, 1496–1501.

14. KLAUSNER JS., CAYWOOD DD. Neoplasms of the Urinary Tract. In: OSBORNE CA., FINCO DR. Canine and Feline Nephrology and Urology**.** Philadelphia : Williams & Wilkins, 1995, 903-916.

15. KNAPP DW. Tumors of the Urinary System. In: WITHROW SJ., VAIL DM. Withrow & MacEwen´s Small Animal Clinical Oncology. 4th ed., Canada : Saunders, 2007, 649-658.

16. KOBAYASHI N., SUZUKI K., SHIBUYA H., SATO T., AOKI I., NAGASHIMA Y. Renal Collecting Duct Carcinoma in a Dog. Vet. Pathol., 2008, 45, 489-494.

17. KOGA S., TSUDA S., NISHIKIDO M., MATSUYA F., SAITO Y., KANETAKE H. Renal cell carcinoma metastatic to the skin. Anticancer Res., 2000, 20, 1939-1940.

18. LANGOHR IM., IRIGOYEN LF., SALLES MWS., KOMMERS GD., BARROS CSL. Cistadenocarcinoma renal e dermatofibrose nodular em cães Pastor Alemão: 4 casos. Ciência Rural, v.32, n.4, p.621-626, 2002.

19. LANZ O I. Neoplasias do rim. In: SLATTER D. Manual de Cirurgia de Pequenos Animais. 3ª ed., São Paulo: Manole, 2007, 2445-2451.

20. LINEHAN WM., BATES SE., YANG JC. Cancer of the kidney. In: DEVITA VTJr., HELLMAN S., ROSENBERG SA. Cancer Principles and Practice of Oncology, 7th ed., Philadelphia: Lippincott, Williams and Wilkins, 2005, 1139–1167.

21. MAULDIN GE. Nutritional Management of the Cancer Patient. In: WITHROW SJ., VAIL, DM. Withrow & MacEwen´s Small Animal Clinical Oncology. 4th ed. Missouri : Saunders Elsevier, 2007, 307-326.

22. MEUTEN DJ. Tumors of the Urinary System. In: __ Tumors in Domestic Animals. 4th ed., Iowa : Blackwell Publishing Company, 2002, 509-546.

23. MILITERNO G., BAZZO R., BEVILACQUA D., BETTINI G., MARCATO PS. Transitional Cell Carcinoma of the Renal Pelvis in Two Dogs. J. Vet. Med., 2003, 50, 457-459.

24. MORITZ JE., Avaliação de 39 casos de tumores renais. Monografia de Graduação em Medicina apresentado na Universidade Federal de Santa Catarina, Florianópolis, 2006.

25. MORRISON WB. Cancers of the Urinary Tract. In: Morrison W B. Cancer in Dogs and Cats – Medical and Surgical Management. 2nd ed., 2002, 545-554.

26. MUELLER TJ., WU H., GREENBERG RE., HUDES G., TOPHAM N., LESSIN SR., UZZO RG. Cutaneous metastases from genitourinary malignancies. Urology, 2004, 63, 1021-1026.

27. POMPEU ACL., SAMI ARAP, MNRS., MONTEIRO DS. Ocular metastasis as first presentation of renal cell carcinoma: report of 2 cases. Clinics, 2005, 60, 75-78.

28. PRASAD SR., HUMPHREY PA., CATENA JR., NARRA VR., SRIGLEY JR., CORTEZ AD., DALRYMPLE NC., CHINTAPALLI KN. Common and Uncommon Histologic Subtypes of Renal Cell Carcinoma: Imaging Spectrum with Pathologic Correlation. RadioGraphics, 2006, 26, 1795-1806.

29. PREETHA R., KAVISHWAR VS., BUTLE P. Cutaneous metastasis from silent renal cell carcinoma. J. Postgrad. Med., 2004, 50, 287-288.

30. RAWLINGS CA., BJORLING DE., CHRISTI, BA. Rins.. In: SLATTER, D. Manual de Cirurgia de Pequenos Animais. 3ª ed., São Paulo: Manole, 2007, 1606-1618.

31. SAEED S., KEEHN CA., MORGAN MB. Cutaneous metastasis: a clinical, pathological e immunohistochemical appraisal. J. Cutan. Pathol., 2004, 31, 419-430.

32. SCOTT DW., MILLER WH., GRIFFIN CE. Muller & Kirk's Small animal dermatology. 6th edition. Philadelphia: SaundersCompany, 2001.

33. SERAKIDES R., SANTOS RL., ALVES VAF. et al. Anatomopathological and immnohistochemical studies of metastatic renal carcinoma in a cow. Arq. Bras. Med. Vet. Zootec., 1999, 51, 21-25.

34.YAGER JA., WILCOCK BP. Color atlas and text of surgical pathology of the dog and cat. Dermatopahology and skin tumors. 1st edition. London: Mosby-Year Book Europe, 1994.