



Original Full Paper

Morphology and Immunophenotypes of Canine Lymphomas: a Survey from the Service of Animal Pathology, School of Veterinary Medicine and Animal Science, University of São Paulo, Brazil

Kátia C. Kimura¹, Danielle A. Zanini¹, Adriana T. Nishiya³,
Ricardo A. Dias², Maria L. Z. Dagli¹

¹Departamento da Patologia, Faculdade de Medicina Veterinária e Zootecnia da Universidade de São Paulo (FMVZ-USP), São Paulo, Brazil

²Departamento da Medicina Veterinária Preventiva e Saúde Animal, FMVZ-USP, São Paulo, Brazil

³Departamento de Clínica e Cirurgia de Pequenos Animais, Anhembi Morumbi, São Paulo, Brazil

Corresponding Author: Kátia C. Kimura, Departamento da Patologia, Faculdade de Medicina Veterinária e Zootecnia - Universidade de São Paulo
- FMVZ-USP. Av. Prof. Dr. Orlando Marques de Paiva, 87. CEP 05508-900 - São Paulo, SP - Brazil.

E-mail: katiackimura@yahoo.com.br

Submitted August 17th 2011, Accepted October 17th 2011

Abstract

Lymphoma is a malignant clonal expansion of lymphoid cells, and is reported to be one of the most common hematopoietic neoplasms in dogs. The purpose of this study was to perform a survey of lymphomas diagnosed at the Service of Animal Pathology of the School of Veterinary Medicine and Animal Science, University of São Paulo, Brazil, from 1995 to 2009, and determine their morphological subtypes and immunophenotypes. Breed, age and gender were recorded. The canine lymphomas were classified according to the updated Kiel classification, and all the cases were submitted to immunostaining for CD3 and CD79a antibodies to reveal their T or B origin, respectively. In addition, mitotic figures were counted in all samples, in 10 microscopic fields. Mixed breed dogs were the most affected breed (43%), followed by Boxer (14%), German Shepherd (11%), Brazilian terrier (3%), Poodle (3%) and Rottweiler (3%). Other breeds were represented at a rate below 1%. Among the 65 cases of lymphomas, 30 cases were found in females and 35 in males. The mean age was 8.7 years with a range of 5 months to 15 years. The most frequent localization was multicentric lymphadenopathy (37%), followed by extranodal (23%), cutaneous (20%), alimentary tract (18%) and mediastinal site (2%). From 65 canine lymphomas, 55 (85%) had T-cell origin and 10 (15%) had B-cell origin. Among mitotic index, 51% (n=33) of T-cell origin had high mitotic index, 34% (n=22) had a low mitotic index; 9% (n=6) of B-cell origin had high mitotic index and 6% (n=4) had low mitotic index. The most common subtypes were pleomorphic small cell and centroblastic polymorphic type for T-cell lymphoma and B-cell lymphoma, respectively. The 55 T-cell lymphomas were subtyped as: 19 (34%) of pleomorphic small cell, 11 (20%) of cutaneous T cell, high grade, 10 (18%) of lymphoblastic, 4 (7%) of aggressive large granular cell, 3 (5%) of pleomorphic mixed, 2 (4%) of cutaneous T cell, low grade, 2 (4%) of pleomorphic large cell, 2 (4%) of plasmacytoid, 1 (2%) of immunoblastic and 1 (2%) of prolymphocytic. The 10 B-cell lymphomas were subtyped as: 3 (30%) of centroblastic polymorphic, 2 (20%) of Burkitt, 2 (20%) of lymphoplasmacytic, 1 (10%) of anaplastic/mediastinal, 1 (10%) of small lymphocytic and 1 (10%) of prolymphocytic. Our results are in accordance with other studies which state that T-cell lymphomas are the most common in dogs. The possible factors that contribute to the development of lymphomas in dogs remain unknown.

Key Words: canine, lymphoma, immunophenotyping, updated Kiel, histological types

Introduction

Lymphoma is a malignancy of hematopoietic tissue caused by the malignant clonal expansion of lymphoid cells. Lymphoma is reported to be the most common hematopoietic neoplasm in dogs and represents 83% of the hematopoietic cancers (3,4,30). Etiology of the canine lymphoma remains poorly characterized (10).

According to current literature, the incidence of non-Hodgkin lymphoma in dogs is 33 cases per 100,000 dogs per year (7, 31) and the mean age is 6.7 years (2, 5, 25). No gender preference has been reported. The following breeds seem predisposed to lymphoma: Boxer, Scottish terrier, Basset hound, Airedale terrier, Chow Chow, German Shepherd, Poodle, Saint Bernard, Beagle, Golden Retriever and Bulldog (20, 26, 32).

Anatomic forms of canine lymphoma are categorized in four groups: multicentric, alimentary, mediastinal, and extranodal (renal, CNS, and cutaneous) (35).

The histopathological classification of canine lymphoma is still controversial. The most used histopathological classifications for canine lymphoma are the updated Kiel classification and the Revised European-American Lymphoma (REAL) adopted in 2002 by the World Health Organization (WHO) classification (8, 31). The updated Kiel classification is based on cell type (centroblastic, immunoblastic and centrocytic) and immunophenotype (T cell or B). It is an important classification due to its potential prognostic value to determine the time of relapse in animals under treatment and to estimate the survival time (6, 7, 8, 17, 18, 19). The Working Formulation classification is based on standard tissue (diffuse or follicular) and cell type (small cleaved, large, and immunoblastic), but does not include immunophenotyping, and it does not correlate with the prognostic (24). The new classification called REAL-WHO classification added immunophenotyping in the diagnosis of canine lymphoma (31).

Immunophenotyping may be used as a prognostic tool because T-cell canine lymphoma is at significantly higher risk of relapse and early death following therapy than B-cell lymphoma (5, 7, 18, 21, 26, 28, 29).

The purpose of this study is to classify and to immunophenotype canine lymphomas retrieved from the Service of Animal Pathology of the Faculdade de Medicina Veterinária e Zootecnia da Universidade de São Paulo (FMVZ-USP), Brazil.

Material and Methods

Samples

Formalin-fixed paraffin wax-embedded tissue samples were collected from 65 canine lymphomas in the period from 1995 to 2009 from the Service of Animal Pathology of FMVZ-USP, São Paulo, Brazil.

They were classified morphologically according to the updated Kiel classification scheme (18). Breed, gender and age were recorded. This project was approved by the Ethics Committee of School of Veterinary Medicine and Animal Science, University of São Paulo.

Immunohistochemistry

For immunohistochemistry, the sections were placed on silanized slides and dewaxed. After endogenous peroxidase block in with 10% H₂O₂ in a microwave for 15 minutes, the slides were incubated with primary antibodies to anti-CD79a (clone M7051 Dako) diluted in 1:50 and anti-CD3 (rabbit polyclonal, Dako) antibody diluted in 1:100, overnight, at 4°C. Labeled streptavidin biotin (LSAB) reagents and reacted with 3-diaminobenzidine (DAB) were used. Negative controls were obtained by performing the same steps of the immunohistochemical reaction, omitting the primary antibody in the sections.

Histological criteria

Histological types were diagnosed by the size of cells, nuclei morphology and by the mitotic rates according to updated Kiel classification (18). The cell size was defined as small (nucleus smaller than red blood cells), medium (nucleus equal to red blood cells) and large (nucleus larger than two red blood cells). The mitotic rate was counted in histological specimens by scanning 10 fields at 400x. A low mitotic index was defined as 0-2 mitosis/ten fields, and high grade as ≥ 6 /ten fields (7, 8, 18, 19).

Results

The results of the breed distribution by retrospective study identified the prevalence of Mixed breed (43%; n=28), followed by Boxer (14%; n=9), German Shepherd (11%; n=7), Brazilian terrier (3%; n=5), Poodle (3%; n=5), Rottweiler (3%; n=5), Doberman (3%; n=2), Pit bull (2%, n=1), Pinscher (2%, n=1), Fila brasileiro (2%, n=1), Schnauzer (2%, n=1), Great Dane (2%, n=1), Scotch terrier (2%, n=1), Cocker Spaniel (2%, n=1), Teckel (2%, n=1), Golden Retriever (2%, n=1) and Labrador (2%, n=1) shown in Fig. 1. From 65 canine lymphomas, 30 cases were found in females and 35 were found in males.

The incidence of canine lymphoma was higher between 5 to 9 years (45% of total cases), followed by ages between 10 to 13 years (34%); 17% had an age below 4 years and 5% had an age up to 14 years. The mean age was 8.7 years with a range of 5 months to 15 years.

The anatomical distribution showed that 37% (n=24) cases were multicentric lymphadenopathy, 23% (n=15) cases were extranodal, 20% (n=13) cases were cutaneous, 18% (n=12) were in the alimentary tract and 2% (n=1) case were mediastinal.

From 65 canine lymphomas, 55 (85%) had T-cell origin and 10 (15%) had B-cell origin and none had

B-cell and T-cell origin. T-cell lymphoma was the most prevalent. Different morphological subtypes of canine NHL, 6 subtypes of the B-cell and 11 subtypes of the T-cell were studied. Among mitotic index, 51% (n=33) of

T-cell origin had high mitotic index and 34% (n=22) had a low mitotic index and 9% (n=6) of B-cell origin had high mitotic index and 6% (n=4) had low mitotic index.

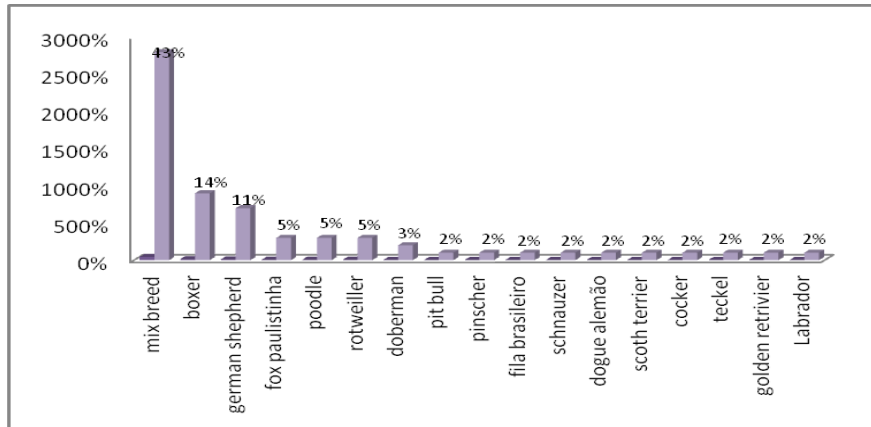


Figure 1 - Distribution according to breed in canine lymphoma. Service of Animal Pathology of the FMVZ-USP, Brazil, from 1995 to 2009.

The T-cell lymphomas were subtyped as: 19 (34%) of pleomorphic small cell, 11 (20%) of cutaneous T-cell, high grade, 10 (18%) of lymphoblastic, 4 (7%) of aggressive large granular cell, 3 (5%) of pleomorphic mixed, 2 (4%) of cutaneous T-

cell, low grade, 2 (4%) of pleomorphic large cell, 2 (4%) of plasmacytoid, 1 (2%) of immunoblastic and 1 (2%) of polymphocytic, as shown in Fig. 2.

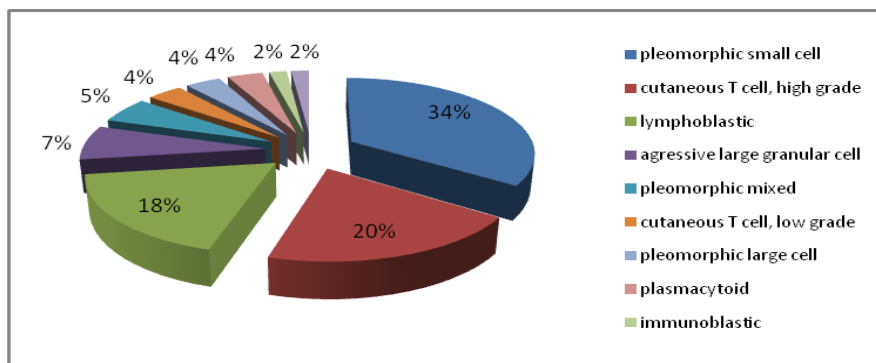


Figure 2 - Histological classification of T-cell lymphoma canine lymphoma. Service of Animal Pathology of the FMVZ-USP, Brazil, from 1995 to 2009.

Among the histological subtypes of cutaneous T-cell lymphoma, the following values were obtained: 7 (54%) of cerebriform small (mycosis fungoides), 2 (15%) of cerebriform large cell in transformation immunoblastic, 2 (15%) of blastic, 1 (8%) of monocytoid and 1 (8%) of cerebriform small cell, as observed in Fig. 3.

The 10 B-cell lymphomas were subtyped as: 3 (30%) of centroblastic polymorphic, 2 (20%) of Burkitt, 2 (20%) of lymphoplasmacytic, 1 (10%) of anaplastic/mediastinal, 1 (10%) of small lymphocytic and 1 (10%) of polymphocytic, as represented in Fig. 4.

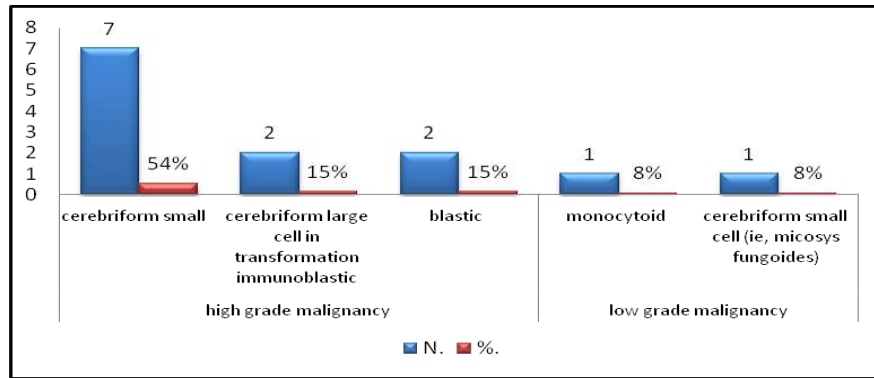


Figure 3 - Histological classification of cutaneous T-cell lymphoma in canine lymphoma. Service of Animal Pathology of the FMVZ-USP, Brazil, from 1995 to 2009.

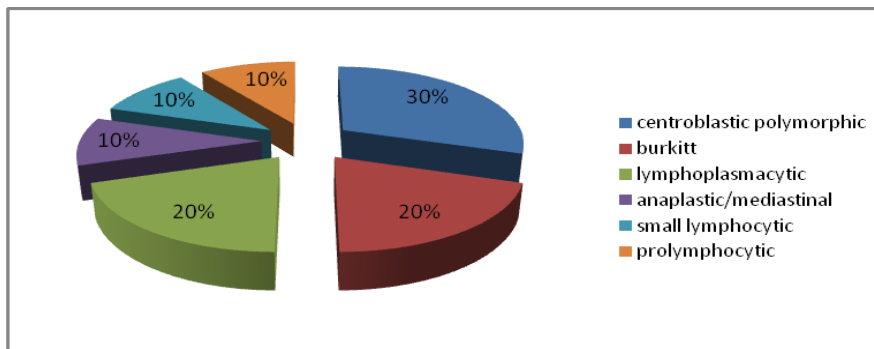


Figure 4 - Histological classification of B-cell canine lymphoma. Service of Animal Pathology of the FMVZ-USP, Brazil, from 1995 to 2009.

The photomicrograph of some subtypes of T and B lymphoma are shown in Figs. 5, 6, 7, 8, 9 and 10.

Discussion

This study diagnosed morphological subtypes and immunophenotypes of 65 canine lymphomas retrieved from the Service of Animal Pathology of the FMVZ-USP from 1995 to 2009. The Service of Animal Pathology is responsible for biopsy and necropsy specimens diagnosis derived from the Veterinary Hospital of FMVZ-USP, as well as private veterinary clinics or other public or private institutions. In a previous study, it was determined that the Veterinary Hospital of the FMVZ-USP receives cases of dogs bearing tumors from all regions of the city of São Paulo (data not shown). Therefore, we believe that such types of studies are important to characterize the epidemiology of these neoplasms in the city of São Paulo.

The majority of findings described Mixed breed as the more prevalent in canine lymphoma followed by German Shepherd. However, the German Shepherd was third in our findings (2,16,31). Mixed breed was the most affected breed, followed by Boxer, similar to other authors (24,25). The most T-cell lymphomas detected by immunophenotype were in the Boxer breed. The mean age of the dogs with lymphoma was 8.7 years (5 months to 15 years). The canine lymphoma is higher between 5 to 9 years. Worldwide,

the mean age ranges from 5.9 and 8 years, similar to our results (13, 14, 19, 25, 28). The higher prevalence of canine lymphoma was variable showing a higher predominance among dogs aged between 6 to 10 years with 6.58 of mean age (23). Other studies identified that 54.4% had an age up to 6 years and 7.2 mean age (24); similar to other results that showed 80% of cases had an age between 5 to 11 years and mean age of 5.9 (16); 80% had an age between 4 to 13 years (22) and other results identified the mean age of 7.9 and an age between 1 to 16 years (31).

Male dog was the most affected gender in this study (53%) in comparison with females (46%). However, the gender predilection of tumors was not significantly different. Other authors found a predominance of lymphoma in male dogs, although that was not significantly different, similar to our study (3, 22). Other authors showed a predominance of lymphoma in female dogs, contradicting the result of some articles (22, 25). Although there is a controversy related to gender, it is believed that gender is not a risk factor for the development of lymphoma in dogs (10, 16, 17).

Multicentric lymphoma was the most common in this study followed by extranodal. This result is similar to the majority of studies found in the literature (6, 12, 16, 19, 20, 23, 24, 31).

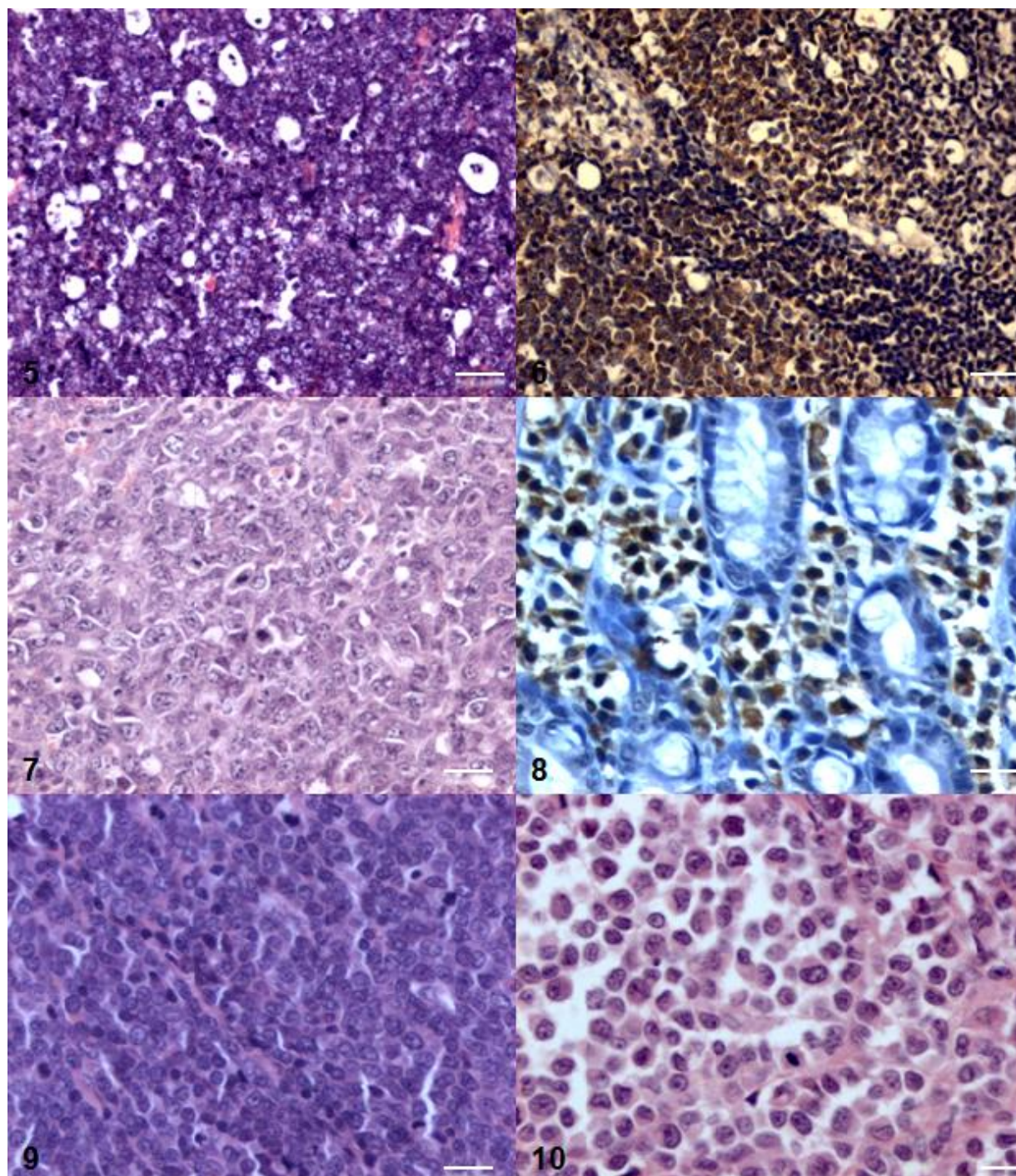


Figure 5. Spleen. Burkitt-subtype B-cell lymphoma. Medium-sized cells characterized with round nuclei, irregular chromatin and several nucleoli. 'Starry-sky' appearance due to a high number of tingible body macrophages. Hematoxylin and Eosin (H&E). Bar=100µm. Figure 6. Spleen. Burkitt- subtype B-cell lymphoma. Neoplastic B-cell lymphoma is densely CD79 positive. Immunolabeling with anti-CD79, hematoxylin counterstain. Bar=100µm. Figure 7. Lymph node. Anaplastic/mediastinal - subtype B-cell lymphoma. Large-sized cells are markedly anaplastic with abundant cytoplasm. H&E. Bar=50µm. Figure 8. Intestine. Small lymphocytic- subtype T-cell lymphoma. Small-sized T cells with round nuclei and absent nucleoli are CD3 positive. hematoxylin counterstain. Bar=50µm. Figure 9. Lymph node. Lymphoblastic- subtype T-cell lymphoma. Medium-sized cells with vesicular nuclei, peripheralized chromatin and visible small nucleoli. H&E. Bar=50µm. Figure 10. Lymph node. Plasmacytoid T-cell subtype. Large-size cell with eccentric nuclei, occasional binucleation, acidophilic cytoplasm. H&E. Bar=50µm. Service of Animal Pathology of the FMVZ-USP, Brazil, from 1995 to 2009.

The role of immunophenotyping lymphomas is to differentiate lymphoma from other non-neoplastic proliferations of lymph nodes and evaluate the prognosis of the patient. The T-cell phenotype was associated with a worse prognosis, unlike the B-cell phenotype that can be associated with good, intermediate and poor prognosis, as previously reported in veterinary and human medicine(1, 16, 18, 35). This study showed T-cell lymphoma was the most common (85% of cases) like some other studies (13, 15, 18). Other researchers from different countries found the predominance of B-cell lymphoma (60-80%) similar to human results that showed the predominance of B-cell lymphoma (80–85%) with the exception of Asia(1, 13, 15, 18, 19, 33, 34). Canine lymphoma are classified as mixed (22%) (double stained for T cell and B cell) and less than 5% are not immune reactive, similar to human studies (8,30) .The predominance of Boxers with T-cell lymphoma was also found in previous studies, similar to our result (7, 14, 17).The epidemiology of canine lymphoma is still controversial in the literature. There is variation in terms of breed predisposition, different phenotypes, different types and subtypes with different biological behavior and response to treatment, varying according to region or country making canine lymphoma, an epidemiological, clinical and pathological challenge whose etiology is still unknown.

The most frequent subtype of T-cell lymphoma in this study was pleomorphic small cell, followed by cutaneous T-cell, high grade and lymphoblastic. The high prevalence of cutaneous T-cell lymphoma was reported in some studies (7, 8, 24). One study found 23.9% of pleomorphic mixed, small, and large-cell lymphomas, 23.9% of lymphoblastic lymphoma and 13.0% of pleomorphic large cells (7). Other articles described 6% of pleomorphic mixed, 3% of plasmacytoid, 2% of pleomorphic large cell, 2% of immunoblastic and 1% of aggressive large granular (17).

Among the cutaneous T-cell lymphoma, in our study the following results were obtained: 4% of cutaneous low grade T-cell, and 20% of cutaneous high grade T-cell. Among the subtypes we observed: 7 (54%) of cerebriform small, 2 (15%) of cerebriform large cell in transformation immunoblastic, 2 (15%) of blastic, 1 (8%) of monocytoid and 1 (8%) of cerebriform small cell. This is in contrast with another study that found more cutaneous T-cell, low grade (9%) than high grade (3%) (17).

The most frequent subtype of B-cell lymphoma in this study was centroblastic polymorphic, followed by Burkitt, lymphoplasmacytic, according to the updated Kiel classification reported by some authors (6, 8, 23, 24).

Other studies described the predominance of centroblastic polymorphic (38%), followed by other subtypes as 11% of marginal zone and 8% of immunoblastic, 2% of Burkitt, 1% of lymphoplasmacytic, 1% of plasmacytoid, and others below 1% (small lymphocytic, prolymphocytic,

centroblastic-centrocytic, anaplastic/mediastinal and small cell not otherwise specified) (17).

In summary, our study has shown that, in general, the Mixed breed was the most affected breed, followed by German Shepherd, and the mean age was 8.7 years. There was no gender preference. T-cell lymphoma predominated in the Boxer breed. Multicentric type was the most common lymphoma. T-cell lymphoma was the most prevalent in dogs in the present study. The most common subtypes were pleomorphic small cell type and centroblastic type for T-cell lymphoma and B-cell lymphoma, respectively. These data are an important epidemiological tool for advancing the best methods in research, prevention and treatment of lymphoma in dogs. Possible factors contributing to the development of lymphoma in dogs remain unknown and require further research.

Acknowledgements

Katia Cristina Kimura is the recipient of a PhD fellowship from FAPESP (Proc. No. 08/54612-9). The study was supported by Fundação de Amparo à Pesquisa do Estado de São Paulo (FAPESP).

References

1. ASTER JC. Diseases of white blood cells, lymph nodes, spleen and thymus. In: Robbins and Cotran Pathologic Basis of Disease, 7th edn., KUMAR V., ABBAS AK., FAUSTO N., eds., Philadelphia, Elsevier Saunders, 2004.
2. CARLTON WW., MCGAVIN MD. Patologia Veterinária Especial de Thomson. 2.ed. Porto Alegre: Artemed, 1998.
3. DALEK CR., CALAZANS SG., NARDI AB. Linfomas. In: DALEK CR, NARDI AB, RODASKI S. Oncologia em cães e gatos. São Paulo: Roca, 2009.
4. DE MOURA VMBD., SEQUEIRA JL., AMORIN RL., BANDARRA EP. Aspectos Epidemiológicos dos Linfomas Caninos – Na região de Botucatu-SP. *Nosso Clínico.*, 2003, 31, 32-40.
5. DOBSON JM., BLACKWOOD LB., MCINNES EF., BOSTOCK DE., NICHOLLS P., HOATHER TM., TOM BD. Prognostic variables in canine multicentric lymphosarcoma. *J. Small An.Practice.*, 2001, 42, 377-84.
6. FAN TM., KITCHELL BE. An update on diagnosing and treating canine lymphosarcoma. *Vet.Med.*, 2002, 58-65.
7. FOURNEL-FLEURY C., MAGNOL JP., BRICAIRE P., MARCHAL T., CHABANNE L., DELVERDIER A., BRYON PA., FELMAN P. Cytohistological and immunological classification of canine malignant lymphomas: comparison with

- human non-Hodgkin's lymphomas. *J.Comp.Pathol.*, 1997, 117, 35-59.
8. FOURNEL-FLEURY C., PONCE F., FELMAN P., BLAVIER A., BONNEFONT C., CHABANNE L., MARCHAL T., CADORE JL., GOY-THOLLOT I., LEDIEU D., GHERNATI I., MAGNOL JP. Canine T-cell Lymphomas: A Morphological, Immunological, and Clinical Study of 46 New Cases. *Vet.Pathol.*, 2002, 39, 92-109.
 9. GREENLEE PG., FILIPPA DA., QUIMBY FW., PATNAIK AK., CALVANO SE., MATUS RE., KIMMEL M., HURVITZ AI., LIEBERMAN PHPG. Lymphoma in dogs: a morphologic, immunologic, and clinical study. *Cancer.*, 1990, 66, 480-490.
 10. JACOBS RM., MESSICK JB., VALLI VE. Tumors of the Hemolymphatic system. In: Meulten DJ. Tumors in domestic animals. 4ed. Iowa: State Press, 2002.
 11. JUBB KVF., KENNEDY PC., PALMER N. Pathology of Domestic Animals. 4.ed. San Diego, California: Elsevier, 2008.
 12. LURIE DM., LUCROY MD., GRIFFEY SM., SIMONSON E., MADWELL BR. T-cell derived malignant lymphoma in the boxer breed. *Vet. Comp.Oncol.*, 2004, 2, 171-175.
 13. LURIE DM., MILNER RJ., SUTER SE., VERNAU W. Immunophenotypic and cytomorphologic subclassification of T-cell lymphoma in the boxer breed. *Vet. Immunol. Immunopathol.*, 2008, 15, 102-10.
 14. MADEWELL BR. Canine lymphoma. *Veterinary Clinics of North America: Small An. Practice.*, 1985, 15, 709-723.
 15. MODIANO JF., BREEN M., VALLI VE., WOJCIESZYN JW., CUTTER GR. Predictive value of p16 or Rb inactivation in a model of naturally occurring canine non-Hodgkin's lymphoma. *Leukemia*, 2007, 21, 184-187.
 16. MORENO K., BRACARENSE APFRL. Estudo retrospectivo de linfoma canino no período de 1990 - 2004 na região norte do Paraná. *B. J. Vet. Res. An. Sci.*, 2007, 44, 46-52.
 17. MOULTON JE., HARVEY JW. Tumors of the lymphoid and hematopoietic tissues In: Moulton JE. Tumors in Domestic Animals. London: University of California Press, 1990.
 18. PONCE F., MAGNOL JP., LEDIEU D., MARCHAL T., TURINELLI V., CHALVET-MONFRAY K., FOURNEL-FLEURY C. Prognostic significance of morphological subtypes in canine malignant lymphomas during chemotherapy. *Vet. J.*, 2004, 167, 158-166.
 19. PONCE F., MARCHAL T., MAGNOL JP., TURINELLI V., LEDIEU D., BONNEFONT C., PASTOR M., DELIGNETTE ML., FOURNEL-FLEURY C. A morphological study of 608 cases of canine malignant lymphoma in France with a focus on comparative similarities between canine and human lymphoma morphology. *Vet. Pathol.*, 2010, 47, 414-33.
 20. RALLIS T., KOUTINAS A., LEKKAS S., PAPADIAMANTIS C. Lymphoma (malignant lymphoma, lymphosarcoma) in the dog. *J. Small An. Practice.*, 1992, 33, 590-596.
 21. RUSLANDER DA., GEBHARD DH., TOMPKINS MB., GRINDEM CB., PAGE RL. Immunophenotypic characterization of canine lymphoproliferative disorders. *In Vivo.*, 1997, 11, 169-172.
 22. SEQUEIRA JL., FRANCO M. Características dos linfomas caninos. *J. Anatomopatol.*, 1992, 7, 6-8.
 23. SUEIRO FA., ALESSI AC., VASSALLO J. Canine lymphomas: a morphological and immunohistochemical study of 55 cases, with observations on p53 immunorexpression. *J. Comp. Pathol.*, 2004, 131, 207-213.
 24. SUZANO SMC. Classificação Citológica e Imunocitoquímica dos Linfomas Caninos. 110 p. Dissertação (Mestrado) – Universidade Estadual Paulista, Botucatu, 2004.
 25. TESKE E., VAN HEERDE P., RUTTEMAN GR., KURZAMAN DI., MOORE PF., MACEWEN G. Prognostic factors for treatment of malignant lymphoma in dogs. *J. Am. Vet. Med. Assoc.*, 1994, 205, 1722-1728.
 26. TESKE E., WISMAN P., MOORE PF., VAN HEERDE P. Histologic classification and immunophenotyping of canine non-Hodgkin's lymphomas: unexpected high frequency of T cell lymphomas with B cell morphology. *Exp. Hematol.*, 1994, 22, 1179-1187.
 27. THOMAS R., SMITH KC., GOULD R., GOWER SM., BINNS MM., BREEN M. Molecular cytogenetic analysis of a novel high-grade canine Tlymphoblastic lymphoma demonstrating co-expression of CD3 and CD79a cell markers. *Chrom.Res.*, 2001, 9, 649-657.
 28. VAN PELT RW., CONNOR GH. Clinicopathological survey of malignant lymphoma in the dog. *J. Am. Vet. Med. Assoc.*, 1968, 152, 976-989.
 29. VAIL DM., KISSEBERTH WC., OBRADOVICH JE., MOORE FM., LONDON CA., MACEWENEG., RITTER MA. Assessment of potential doubling time (Tpot), argyrophilic nucleolar organizer regions (AgNOR), and proliferating cell nuclear antigen (PCNA) as predictors of therapy response in canine non-Hodgkin's lymphoma. *Exp. Hematol.*, 1996; 24:807-815.

30. VAIL DM., YOUNG KM. Hematopoietic tumors. In: WITHROW, S.J.; MACEWEN, E.G. Small Animal Clinical Oncology. 4.ed. Philadelphia: W.B. Saunders, 2007.
31. VEZZALI E., PARODI AL., MARCATO PS., BETTINI G. Histopathologic classification of 171 cases of canine and feline non-Hodgkin lymphoma according to the WHO. *Vet. Comp. Oncol.*, 2010, 8, 38-49.
32. VONDERHAAR MA., MORRISON WB. Lymphosarcoma. In: Morrison, WB. Cancer in dogs and cats. Philadelphia: Williams & Wilkins, 1998.
33. WILKERSON MJ., DOLCE K., KOOPMAN T., SHUMAN W., CHUN R., GARRETT L., BARBER L., AVERY A. Lineage differentiation of canine lymphoma/ leukemias and aberrant expression of CD molecules. *Vet. Imm. Immunopathol.*, 2005, 106, 179-196.
34. WILLMANN M., ILAUER LM., ARESPACOCCHAGA AG., REIFINGER M., MOSBERGER I., THALHAMMER JG. Pax5 immunostaining in paraffin-embedded sections of canine non-Hodgkin lymphoma: A novel canine pan pre-B- and B-cell marker. *Vet. Comp. Oncol.*, 2010, 8, 38-49.
35. WORLD HEALTH ORGANIZATION: International Classification of Diseases for Oncology. 2.ed. Geneva, 2001.