



Review article

Consensus for the Diagnosis, Prognosis and Treatment of Canine Mammary Tumors - 2013

Geovanni D. Cassali^{1*}, Gleidice E. Lavallo², Enio Ferreira¹, Alessandra Estrela-Lima³,
Andrigo B. De Nardi⁴, Cristina Ghever⁵, Renata A. Sobral⁶, Renne L. Amorim⁷, Luciana O. Oliveira⁸,
Felipe A. R. Sueiro⁹, Hugo E. O. Beserra¹⁰, Angélica C. Bertagnolli¹¹, Conrado O. Gamba¹,
Karine A. Damasceno¹, Cecília B. Campos¹, Marina R. Araujo¹, Liliane C. Campos¹,
Lidianne N. Monteiro¹, Fernanda C. Nunes¹, Rodrigo S. Horta¹², Diego C. Reis¹,
Maria Cecília R. Luvizotto¹³, Georgia M. Magalhães¹⁴, Josiane B. Raposo⁵, Ana M. R. Ferreira¹⁵,
Neide M. Tanaka¹⁶, Fabrizio Grandi¹⁰, Rodrigo Ubukata¹⁷, Karen Batschinski¹⁷, Erika M. Terra¹⁸,
Rosana C. L. Salvador¹⁸, Paulo C. Jark¹⁸, Juliana E. R. Delecrodi¹⁹, Nara A. Nascimento³,
Danielle N. Silva³, Laís P. Silva³, Kelly Cristine R. S. Ferreira⁸, Michele S. Frehse²⁰,
Giovana W. di Santis²⁰, Elisângela O. Silva²⁰, Tainã N. Guim²¹, Beatriz Kerr²², Priscila P. Cintra¹⁴,
Franciele B. F. Silva¹⁵, Juliana S. Leite¹⁵, Marcela F. V. Mello¹⁵, Maria de Lourdes G. Ferreira¹⁵,
Heidge Fukumasu²³, Breno S. Salgado²⁴, Rafael Torres⁷

¹Laboratório de Patologia Comparada, Departamento de Patologia Geral, ICB/UFMG, Belo Horizonte – MG, Brazil.

²Hospital Veterinário, Escola de Veterinária, UFMG, Belo Horizonte – MG, Brazil.

³Departamento de Patologia e Clínicas, Escola de Medicina Veterinária, UFBA, Salvador – BA, Brazil.

⁴Departamento de Clínica e Cirurgia, Faculdade de Ciências Agrárias e Veterinárias UNESP, Jaboticabal - SP, Brazil.

⁵Laboratório Regional de Diagnóstico, Departamento de Patologia Animal, Faculdade de Veterinária, UFPEL, Pelotas - RS, Brazil.

⁶Onco Cane Clínica Veterinária Ltda- São Paulo - SP, Brazil.

⁷Departamento de Clínica Veterinária, Faculdade de Medicina Veterinária e Zootecnia, UNESP, Botucatu - SP, Brazil.

⁸Hospital de Clínicas Veterinárias, UFRGS, Porto Alegre - RS, Brazil.

⁹Patologia e Biologia Molecular Veterinária, Campinas - SP, Brazil.

¹⁰Departamento de Clínica Veterinária, Faculdade de Medicina Veterinária e Zootecnia, UNESP, Botucatu – SP, Brazil.

¹¹Fepagro Saúde Animal – Instituto de Pesquisas Veterinárias Desidério Finamor (IPVDF), Eldorado do Sul - RS, Brazil

¹²Departamento de Clínica e Cirurgia Veterinárias – Escola de Veterinária, UFMG, Belo Horizonte - MG, Brazil.

¹³Departamento de Clínica Cirurgia e Reprodução Animal, UNESP, Araçatuba - SP, Brazil.

¹⁴ Hospital Veterinário, UNIFRAN, Franca – SP, Brazil.

¹⁵Setor de Anatomia Patológica Veterinária, Departamento de Patologia e Clínica Veterinária, Faculdade de Veterinária, UFF, Niterói – RJ, Brazil.

¹⁶Curso de Medicina Veterinária, Centro de Ciências Biológicas e da Saúde, UNOPAR, Londrina - PR, Brazil.

¹⁷Setor de Oncologia, PROVET, São Paulo – SP, Brazil.

¹⁸Hospital Veterinário Governador Laudo Natel, Departamento de Clínica e Cirurgia, Faculdade de Ciências Agrárias, UNESP, Jaboticabal – SP, Brazil.

¹⁹CenterVet Hospital Veterinário, Contagem – MG, Brazil.

²⁰Departamento de Medicina Veterinária Preventiva, Centro de Ciências Agrárias, UEL, Londrina - PR, Brazil.

²¹Hospital Universitário Veterinário, UNIPAMPA, Uruguaiana – RS, Brazil.

²² Instituto de Ciências da Saúde, UNIP, São Paulo – SP, Brazil.

²³Laboratório de Oncologia Comparada e Translacional, Departamento de Medicina Veterinária, Faculdade de Zootecnia e Engenharia de Alimentos, USP, Pirassununga – SP, Brazil.

²⁴Curso de Medicina Veterinária, UNIFENAS, Alfenas – MG, Brazil.

* Corresponding Author: Laboratório de Patologia Comparada, Departamento de Patologia Geral, ICB/UFMG- Av. Antonio Carlos, 6627, 31270-901, Belo Horizonte/MG, Brazil. E-mail: cassalig@icb.ufmg.br

Submitted July 07th 2014, Accepted July 21st 2014

Abstract

The purpose of this paper is to establish criteria that could guide the diagnosis, prognosis and treatment of canine mammary neoplasias. It was elaborated during the Mammary Pathology Meeting: Diagnosis, Prognosis and Treatment of the Canine Mammary Neoplasia, held on November 6th and 7th, 2010 in Belo Horizonte – MG, Brazil. Academics from several regions of Brazil were present and contributed to this work. After three years, a new discussion was found necessary in order to address important questions: 1 - Have Brazilian DVMs applied the consensus? 2 - What were the main difficulties in applying the consensus? 3 - What were the obtained results? 4 - What were the main differences among the various oncology services/groups? 5 - How could the criteria be improved and uniformed? A spreadsheet that allowed data collection and an abstract was submitted by each oncology service/group from various parts of the country. Based on the abstracts we identified the main differences in diagnosis and therapeutic conducts among the groups. These differences have guided the discussions of the II Mammary Pathology Meeting and the publication of a second consensus that has been revised and updated. The II Mammary Pathology Meeting: Diagnosis, Prognosis and Treatment of the Canine mammary Neoplasia, was held on December 9th, 10th and 11th, 2013 in Belo Horizonte – MG, sponsored by the Laboratory of Comparative Pathology of the Federal University of Minas Gerais (UFMG), with the support of the Brazilian Association of Veterinary Pathology (ABPV) and Brazilian Association of Veterinary Oncology (ABROVET). Academics from several regions of Brazil were present and contributed to this work.

Key words: mammary neoplasias, dogs, mammary gland, veterinary oncology.

Introduction

Mammary tumors are the most frequent neoplastic processes of the female dog and represent a problem of large impact in veterinary medicine. In this context, many efforts are being directed towards adopting criteria towards standardization of the diagnosis, understanding tumor behavior and evolution and evaluating prognostic and predictive factors such as: morphology, molecular and genetic alterations. The knowledge and adoption of these parameters are fundamentally important for choice and success of therapies that promote reduction of tumoral recurrence and increase in overall survival (18).

In 2010, a paper was elaborated during the course of the Mammary Pathology Meeting: Diagnosis, Prognosis and Treatment of the Canine Mammary Neoplasia, held on November 6th and 7th, 2010 in Belo Horizonte – MG. The meeting sponsored by the Laboratory of Comparative Pathology of the Federal University of Minas Gerais (UFMG), with the support of the Brazilian Association of Veterinary Pathology (ABPV) and Brazilian Association of Veterinary Oncology (ABROVET). The aim was to bring teachers and/or researchers, practitioners and graduate students working in the field of anatomical pathology and clinical oncology together to establish criteria that could guide the diagnosis, prognosis and treatment of canine mammary neoplasias. The paper was published in Brazilian Journal of Veterinary Pathology (27).

After three years, a new discussion was found necessary in order to address important questions: 1 - Have

Brazilian DVMs applied the consensus? 2 - What were the main difficulties in applying the consensus? 3 - What were the obtained results? 4 - What were the main differences among the various oncology services/groups? 5 - How could the criteria be improved and uniformed?

The first step was to acquire information regarding diagnosis and treatments performed by each oncology service/group based on the I Consensus (27). A spreadsheet that allowed data collection and an abstract was submitted by each oncology service/group from various parts of the country. Based on the abstracts we identified the main differences in diagnosis and therapeutic conducts among the groups. These differences have guided the discussions of the II Mammary Pathology Meeting and the publication of a second consensus that has been revised and updated.

The II Mammary Pathology Meeting: Diagnosis, Prognosis and Treatment of the Canine Mammary Neoplasia, was held on December 9th, 10th and 11th, 2013 in Belo Horizonte – MG, sponsored by the Laboratory of Comparative Pathology of the Federal University of Minas Gerais (UFMG), with the support of the Brazilian Association of Veterinary Pathology (ABPV) and Brazilian Association of Veterinary Oncology (ABROVET).

1. CLINICAL SIGNS

Mammary gland tumors affect middle aged and old female dogs that are sexually intact or spayed (38, 43). The majority of dogs with mammary neoplasias are

clinically healthy at the time of diagnosis and the tumors can be identified by the owner or a professional during a routine physical examination (146).

Canine mammary neoplasias are commonly presented as circumscribed nodules with variable size, consistency and mobility to the skin and muscle. They can also be associated with skin ulceration and local inflammatory reactions. Multiple tumors are frequently observed in a single mammary gland or may involve multiple mammary glands simultaneously and can be of different histological types (87, 107). However, the tumor with the worst prognosis will always determine the clinical evolution of the patient (32). The caudal abdominal and inguinal mammary glands are affected more frequently than thoracic glands (22).

2. DIAGNOSIS

Clinical examination

A thorough history and a complete physical exam including careful palpation of the mammary glands should be performed in all dogs with mammary gland tumors (148). During the examination, the general clinical condition of the animal is evaluated. The professional must collect information concerning medical history, reproductive cycle (regular heat, number of births, castration, hormone therapy use, abortion and history of pseudo pregnancy), the approximate date when the lesions were first noticed by the owner, and previous tumor lesions. This information should be recorded in a cancer record form (26, 62). A complete medical record that may be mainly implemented for mammary gland lesion research purposes is available in supplement 1. An additional concise medical record is available in supplement 2.

During the clinical examination, the two mammary chains and the regional lymph nodes should be explored. To determine the precise clinical staging of the cancer, the professional should perform chest radiographs in three views (Ventrodorsal and right and left Laterolateral) as a standard diagnostic procedure for evaluation of pulmonary metastatic disease. Pulmonary lesions ranging in size from six to eight mm in diameter can be detected using conventional radiography. Early detection of metastatic lesions smaller than 6 mm can be achieved using computed tomography. The lung is the most common site for distant metastasis in dogs with malignant mammary gland tumors, but additional tests such as an abdominal ultrasound is recommended for investigation of other anatomical sites. The observation of distant metastases is associated with an unfavorable prognosis (146).

Excisional biopsy is the recommended diagnosis method for canine mammary tumors. Curing dogs presenting with small malignant well-differentiated tumors

is feasible as long as surgical margins are not compromised.

Inspection of the regional lymph nodes should be included in the routine clinical evaluation of dogs with mammary tumors, as the presence of metastasis impacts on the clinical staging of the cancer and therefore survival and treatment approach. Cytology is a safe method for inspecting lymph nodes. It has 100% sensitivity and 96% specificity for identification of metastasis (90). Therefore, fine needle aspiration cytology (FNAC) of palpable lymph nodes is recommended as the presence of metastasis impacts on the clinical staging of the cancer and the treatment approach. In cases of positive or suspicious results for metastasis, excision of affected lymph nodes should be performed (146). FNAC should be performed on lymph nodes presenting with alterations in volume, shape and consistency upon clinical examination. Cell smears obtained from puncture (3-5 slides) should be air dried or immediately fixed in a solution of 70% ethanol. Excessive contamination with blood, hair and liquefied material should be avoided as this could compromise the quality of the sample (25).

Clinical staging: TNM

Determining the clinical stage enables the definition of the extension of the tumor. As a consequence, this allows a prognosis to be established and treatment to be planned, giving precise indications to the pathologist concerning the material submitted for analysis and for comparing clinical observations from different sources (145).

Clinical staging is determined according to the TNM system established by the World Health Organization (WHO) for canine mammary tumors. Based on this system, the size of the primary lesion (T), the extent of its spread to regional lymph nodes (N) and the presence or absence of distant metastases (M) must be assessed (113) (Table 1-2).

Tumor size is considered an independent prognostic factor for mammary tumors in bitches. Tumors sized 3.0 cm or smaller are significantly correlated with better prognosis compared with larger tumors. This parameter can be easily obtained and should be considered when making decisions concerning complementary therapy (31,146). During a study concerning canine mammary tumors that included 15 benign and 23 malignant cases, Ferreira et al. (2009) (61) observed that most lesions greater than 5.0 cm (T3) were malignant, with a higher proliferation rate and lower positivity for progesterone receptors (PR) when compared with to smaller tumors (T1, T2).

The evaluation of regional lymph nodes has a major impact on the survival of dogs with mammary gland tumors. Animals with regional lymph node metastases exhibit a significant decrease in survival expectancy

Table 1. Clinical staging (TNM) of canine mammary tumors (modified from Sorenmo et al., 2013) (147).

Modified System			
T – Primary Tumor			
	T1 <3cm		
	T2 3-5cm		
	T3 >5cm		
N – Regional Lymph Nodes			
	N0 Histologic or Cytologic – No metastasis		
	N1 Histologic or Cytologic – Metastasis present		
M – Distant Metastasis			
	M0 No Distant Metastasis Detected		
	M1 Distant Metastasis Detected		
	T	N	M
Stage I	T1	N0	M0
Stage II	T2	N0	M0
Stage III	T3	N0	M0
Stage IV	Any T	N1	M0
Stage V	Any T	Any N	M1

compared with individuals who tested negative for lymph node metastasis (31,146). Hellmén et al. (1993) (79) performed a study involving 202 female dogs with mammary cancer. They demonstrated that regional lymph node involvement was a statistically significant unfavorable prognostic factor as determined by univariate analysis, but were not significant when multivariate analysis was performed.

The presence of distant metastasis is detrimental for prognosis compared with to female dogs that present with spreading to regional lymph nodes only (146).

Inflammatory carcinoma

Inflammatory mammary carcinoma (IMC) is named after the initial clinical appearance of the lesion, which resembles an inflammatory process of the skin or mammary gland. It is an uncommon tumor with an aggressive clinical course and unfavorable prognosis (5, 117, 154). The IMC can affect humans and canines (5, 81, 154), the latter being the only animal species in which the cancer occurs spontaneously (73). Approximately 50% of mammary tumors are malignant (31, 125), and of these approximately 7.6% are classified as IMC mainly based on clinical examination as well as histopathology findings (119).

The tumor is microscopically characterized by the presence of an association between any carcinoma subtype

and an inflammatory reaction, with presence of tumor emboli in lymphatic vessels in the dermis (5, 30, 31). Macroscopically, the lesions grow as continuous, firm and hyperemic plaques without specific demarcation (30). Other symptoms include itching, local temperature rise, intense or moderate pain, swelling and redness of the skin overlying the mammary gland (5, 16, 73, 117). IMCs have a high potential for metastasis therefore, it is prudent to carry out additional tests including chest radiographs and abdominal ultrasound to monitor for possible metastatic foci. Dogs with inflammatory carcinoma are classified in T4 of clinical staging (113).

Fine needle aspiration of the primary tumor

Excisional biopsy is recommended for initial diagnosis of tumors of the mammary gland in the bitch, but the use of aspiration cytology has increased over time and high levels of agreement between cytological and histopathology results have been described (25, 172). Experienced cytologists must collect the samples, a restraint for the wide use of FNAC in veterinary medicine (25).

Cytological examination may be useful for excluding differential diagnoses such as mastitis, lipomas and mast cell tumors, among others. In clinical evaluations, the execution of FNAC on the primary tumor does not interfere with the surgical planning for patients as

this procedure is selected according to lesion size (T), the affected mammary gland and its lymphatic draining.

Moreover, the final diagnosis should be based on histopathology reports as this allows tumor histomorphology to be assessed meticulously, such as pleomorphism, differentiation degree, mitotic index, presence or absence of necrosis and the precision of excision (107).

Anatomopathological examination

Sample harvesting for anatomopathological examination

The histological classification of mammary tumors is the best tool to predict biological behavior (9). Therefore, it is essential to conduct an anatomopathological examination of all nodules regardless of their size, as this examination provides important additional information that can assist the clinician in defining the prognosis and the best treatment plan (165). The main factors affecting sample quality include the lack of representation, inadequate fixation, and the lack of information regarding the sample.

Specimens should be fixed in formaldehyde and sent to laboratories within 24 hours for processing. Ferreira et al. (2003) (62) proposed that when nodulectomy and partial mastectomy were performed, each affected mammary gland, including the skin and subcutaneous tissue, and the regional lymph nodes should be collected separately and immediately fixed in 10% neutral phosphate buffered formalin. However, this procedure could make the evaluation of the surgical resection margins difficult. Therefore, the whole mammary chain with inguinal lymph nodes could be placed in a bottle with 10% formalin. If the surgical sample is large, some cuts on the cutaneous side of the sample could avoid inadequate fixation. The volume of this solution must be at least 10 times the size of the fragment. It is recommended that the fixation time does not exceed 24-48 hours, and after fixation, the fragment should be placed in a solution of 70% alcohol so that immunohistochemistry is not compromised. The vials should be labeled with the name of the animal, organ, and lesion location and accompanied by the clinician's request with accurate information provided concerning the animal's medical history, including the macroscopic description of the tumor (see model of anatomopathological protocol published by Ferreira et al., 2003) (62).

For trimming procedures, the recommendations of Estrela-Lima et al. (2010) (56) should be followed. For tumors between 3-5 cm and specimens larger than 5 cm, three and five fragments of the tumor mass should be collected, respectively, and each fragment must measure no more than 1.5x1.5x0.5 cm. The margins should be prioritized, and the central necrotic areas excluded. Putting forth a blanket recommendation for how every tumor

biopsy specimen should be trimmed is impossible because each specimen is unique. Specimen size, overall margin area, tumor type, and potential financial restrictions should be considered. Cross-sectioning (radial method, "halves and quarters") is the most commonly used method for small or moderately sized masses. The tumor is bisected along its shortest axis. Subsequently, each half of the tissue is bisected through its longest axis, creating quarter sections that demonstrate the mass in a different plane. On the other hand, parallel slicing at regular intervals (complete bread loafing, serial sectioning) increases the percentage of marginal tissue examined (82). All mammary glands of the submitted chain must be sampled, even if they do not contain a tumor. The margin evaluation is mandatory and can be identified using India ink staining.

In this context, the standardization of the harvesting and shipping procedures of specimens by surgeons and clinicians, and the material cleavage procedures performed by the pathologist, is essential to establish criteria for research. When conducting prospective studies within or across institutions, a standardized trimming method should be used to maintain the consistency of results (82). Therefore, histopathological diagnosis will be not compromised, and the prognosis for patients with mammary neoplasias will be accurate.

Evaluation of surgical resection margins

Whenever there are neoplastic cells in the area stained with Indian ink, the sample should be considered as having "compromised margins". Lateral, deep and superficial margins should be evaluated for the presence of neoplastic cells. If the margins are free, it is recommended to assign a distance in millimetres from the tumor to the smallest margin. If there are compromised margins, these must be identified and the type of imperfection must be assigned (presence of isolated cells or lesion continuity).

Evaluation of metastasis in lymph nodes

During lymph node excision it must be measured and, in case of size augment, cut into longitudinal sections. Histopathological evaluation with hematoxylin-eosin staining allows the assessment of lymph node metastasis by counting the number of cell clusters. Macrometastasis occurs when the cluster size is greater than 2mm, while sizes between 0.2 mm and 2 mm characterize micrometastases. Areas that measure less than 0.2mm are considered isolated cancer cells (2). It can be difficult to visualize metastasis using routine HE staining. In such cases, it is suggested that immunohistochemistry using specific antibodies against epithelial cell proteins such as cytokeratins are utilized (103).

The sentinel lymph node (SL) is defined as the first lymph node of a regional lymphatic chain to receive lymph from a primary tumor, and, therefore, is expected to

first contain a micrometastasis (13). The identification of the SL is necessary due to the inexistence of a standard lymphatic draining in the bitch. As seen in human mammary tumors, lymphatic draining also undergoes peritumoral lymphatic reconfiguration due to the presence of prolymphangiogenic cytokines (49, 83, 140). Although literature is scarce, identification of the SL through vital markers such as Patent Blue V (PB), Methylene Blue, and autogenous hemosiderin have been reported in bitches (8, 122, 123, 151).

Authors believe that PB should be used to facilitate the localization and surgical excision of axillary lymph nodes. The location of the lymph node receiving drainage from the tumor followed by its surgical excision is aided by the visual analysis of the presence of the color blue (123). The main concern is with lymph nodes that may not be evident in cases of canine mammary neoplasias presenting well established poor prognosis characteristics, such as: T3 size, ulceration, adherence to adjacent skin or muscle. Poor prognosis neoplasias may be related to higher incidence of metastases. In some cases, metastasis may be presented as isolated tumor cells or micrometastases, unlikely evident in the clinical exam of regional lymph nodes due to lack of macroscopic alterations. Palpation may be an insensitive indicator of nodal metastasis in the dog (166). As micrometastases may take many months to produce palpable lymphadenomegaly, early evaluation of the lymph node can allow for a more accurate assessment of stage (71). Furthermore, Fine Needle Aspiration Cytology (FNAC) performed in lymph nodes may have false negative results mainly in initial and smaller metastases. This justifies surgical excision for histopathological evaluation. Blue dyes were reported to have no interference with processing, staining or interpretation (cytological or histopathological) of the submitted samples (164).

PB is currently the most commonly used dye in human medicine due to its easy manipulation, safety, and low cost. The recommended dose is 0.2-0.3 mg/Kg, applied immediately before the surgical procedure. The total volume must be equally divided and injected into four superficial peritumoral intradermal points. After 20 minutes, the blue color of the superficial lymphatic vessels may be observed through the skin, indicating the drainage direction. Surgical inspection of the draining region will reveal strong staining of the SL (74).

Histopathological evaluation

The safest diagnostic method is histopathological examination of excisional or incisional biopsies. Besides facilitating lesion classification, histopathological examination allows investigators to evaluate infiltration of the skin, soft tissue and surrounding blood vessels, details concerning the histomorphology of the tumor (presence or absence of pleomorphism, degree of differentiation, mitotic index, presence or absence of necrosis) and

contributes to a precise excision, as proposed by Ferreira et al. (2003) (62).

The assessment of the integrity of the myoepithelial/basal cell layer is an important criterion for the diagnosis of breast carcinoma in women. It aids the differential diagnosis between *in situ* and invasive malignant lesions, being particularly useful for the detection of microinvasion spots (152, 169). In veterinary medicine, myoepithelial markers such as alpha smooth muscle actin (6, 40), S-100 (44), calponin (54), p63 (65) and maspin (55) have been used predominantly in research directed towards the determination of tumor histogenesis. However, their use as an auxiliary tool in the determination of invasion is limited and few studies have addressed this aspect (6).

Histological grading

Histopathological grading of breast cancer aims to evaluate the architecture of the neoplasia and morphological variations of the core, and the histological grade presents a significant correlation with tumor aggressiveness (51). Currently, in human medicine, the most widely used grading system is the Nottingham modified by Elston and Ellis (1998) (50), which has replaced previous subjective evaluations when the degree of tumor differentiation was estimated by the general appearance of the tumor. The Nottingham method allows the factors to be evaluated systematically using more objective criteria.

According to this system, determination of histological grade is based on the evaluation of the tubule formation index (1 point: more than 75% of the tumor is composed by tubules, two points: between 10% and 75% of tubular formations, and 3 points: the tubules occupy 10% or less of the tumor), nuclear pleomorphism (1 point: small and regular nuclei; 2 points: moderate increase in size and variation of nuclei; 3 points: marked pleomorphism, with large variation in size and shape of nuclei) and mitotic count (1 point: 0-8 mitosis, 2 points: 9-16 mitosis, and 3 points: above 17 mitosis in 40x lens). The histological grade of the tumor is obtained through the sum of the scores which results in a total amount that ranges from 3 to 9. The summary of tumor grades is: 3-5 points: grade I; 6-7 points: grade II; 8-9 points: Grade III. Anaplasia increases with an increase in grade. The histological grade is considered as an independent prognostic indicator for primary breast cancer in women. In veterinary medicine, the grading systems for mammary tumors with well-defined criteria are not frequently used (89). Among the most popular ones is the Misdorp et al. (1999) (107) and Gilbertson et al. (1983) (70) systems, both based on the combination of cellular and nuclear characteristics. Recently, the number of veterinary researchers who have adopted the criteria for histological grading proposed by Nottingham for evaluating breast carcinomas in dogs has increased (Table 2).

Table 2. Summary of Histological Grades of Breast Cancer according to Elston & Ellis (1998) (50).

Attribute	Score
Tubule Formation	
> 75% of tumor	1
10 to 75% of tumor	2
< 10% of tumor	3
Nuclear Pleomorphism	
Nuclear size similar to a normal cell (2 to 3 times the size of red blood cell)	1
Moderate increase in size and variation	2
Marked variation	3
Mitotic Count (HPF) *	
0 a 8 Mitotic counts / 10 HPF	1
9 a 16 Mitotic counts / 10 HPF	2
17 or greater Mitotic counts / 10 HPF	3

*Adapted according to the microscopy field size used in this study= 0.55 mm.
 HPF = high Power field. Olympus BX-41, 40 X objective lens.

These studies reveal a significant correlation between histopathological grading and other prognostic factors such as histological type and survival (32, 47, 48, 56, 84, 85, 104, 111). Therefore, histological grading of tumors determined by the Nottingham system and modified by Elston and Ellis (1998) (50), represents a sensible tool that can be incorporated into veterinary medicine as is the case with human oncology.

Classification of tumor lesions

Methods for classification of canine mammary tumors vary considerably. There may be disagreement about the most common tumors such as mixed tumors and carcinomas in mixed tumors (22). Several classifications have been proposed, but the most widely adopted is that of Misdorp et al. published in 1999 by the AFIP (Armed Forces Institute of Pathology) (107) (Table 3).

Non-neoplastic epithelial lesions

Alterations in the molecular behavior of canine mammary epithelium suggested that intraepithelial or intraductal lesions (ductal and lobular hyperplasia and ductal carcinoma *in situ*) represent evolutionary stages in

the process of malignant neoplastic progression (59, 63) (Figure 1).

Epithelial hyperplasia

Mammary epithelial hyperplasia is often observed in the final portion of the ductal gland in canine species. These lesions can arise in the extralobular ducts, called ductal hyperplasia, or in the intralobular ducts, called lobular hyperplasia. When these types of hyperplasia are diffuse or multifocal they are referred to as papillomatosis or epitheliosis. In such cases, the lesions affect ductal units and have similar morphological behavior (107).

Current evidence suggests that hyperplastic alterations affecting the ductal intralobular and extra lobular units have similar diagnostic and prognostic significance, as observed in the human mammary gland. It is suggested that other types of cellular alterations, classified as lobular hyperplasia in human breast, could occur in the canine mammary gland but with a distinct diagnostic significance (3, 109). There are three distinct types of canine hyperplastic alterations:

I) Ductal hyperplasia - refers to proliferations characterized by supernumerary projections of epithelial cells, which are morphologically similar to normal cells of

Table 3. Canine Mammary Neoplasias Histological Classification. Modified from Misdorp et al., 1999 (107).

<p><u>Non-neoplastic epithelial lesion</u></p> <p>Epithelial hyperplasia</p> <ul style="list-style-type: none">Ductal hyperplasiaLobular HyperplasiaAdenosis <p>Columnar cell lesions</p> <ul style="list-style-type: none">Columnar cell alterationColumnar cell hyperplasiaAtypical columnar cell lesions <p><u>Benign tumors</u></p> <ul style="list-style-type: none">AdenomaAdenomyoepitheliomaBasaloid adenomaFibroadenomaBenign mixed tumorDuctal papilloma <p><u>Malignant tumors</u></p> <p>Carcinomas</p> <p>Carcinomas <i>in situ</i></p> <ul style="list-style-type: none">Ductal carcinoma <i>in situ</i>Lobular carcinoma <i>in situ</i> <p>Carcinoma in a mixed tumor</p> <p>Papillar carcinoma</p> <p>Tubular carcinoma</p> <p>Solid carcinoma</p> <p>Special type carcinomas</p> <ul style="list-style-type: none">Micropapillary carcinomaInvasive lobular carcinomaPleomorphic lobular carcinomaSecretory carcinomaMucinous carcinomaLipid-rich carcinomaSquamous cell carcinomaSpindle-cell carcinomaAnaplastic carcinomaMammary neoplasias with sebaceous differentiation <p>Myoepithelial neoplasias</p> <ul style="list-style-type: none">Malignant adenomyoepithelioma <p>Sarcomas</p> <ul style="list-style-type: none">FibrosarcomaOsteosarcomaCarcinosarcomaSarcoma in mixed tumor <p>Other sarcomas</p> <ul style="list-style-type: none">CondrosarcomaLiposarcomaHemangiosarcoma

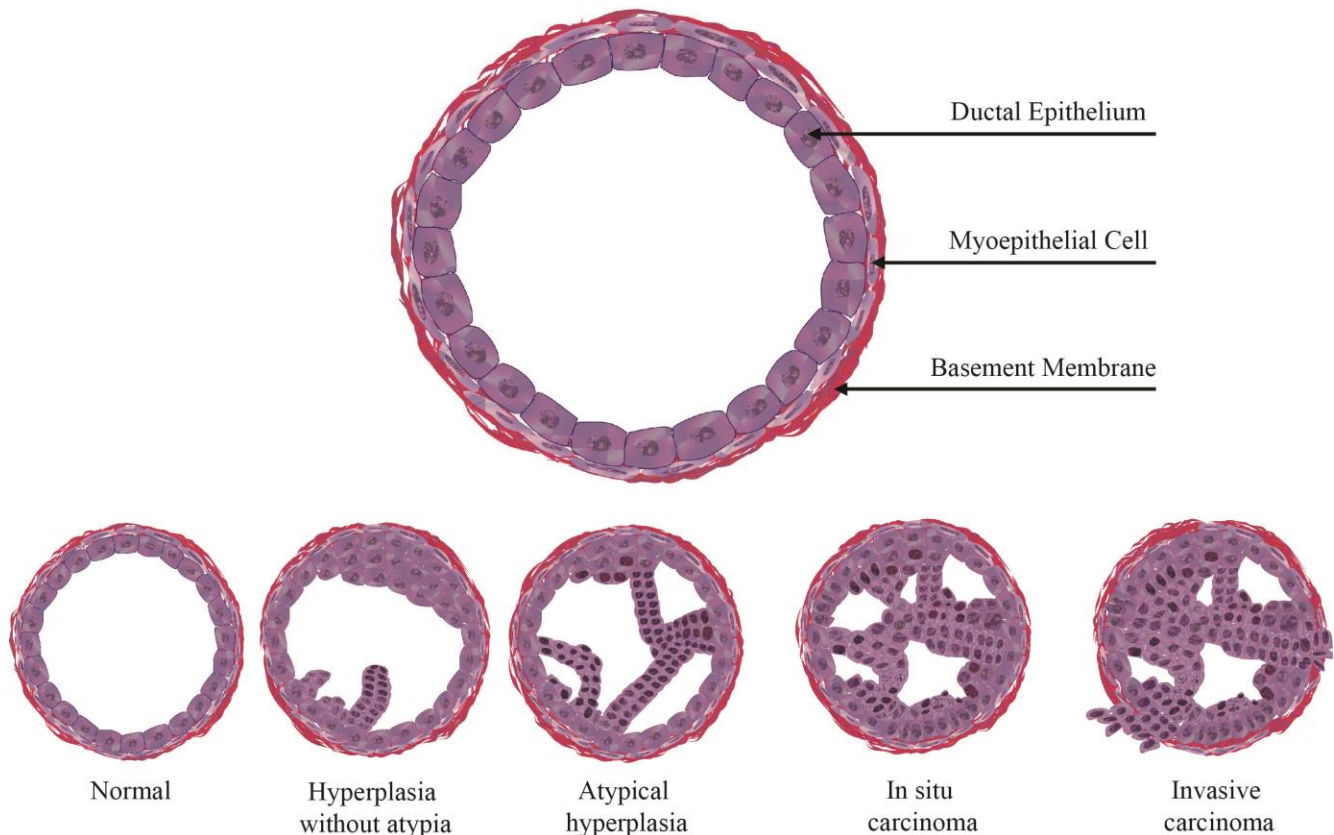


Figure 1. Canine mammary gland: normal duct and evolution of proliferative lesions.

the duct, with mild nuclear pleomorphism. Disorganized or irregular bridges formed by intraductal papillary projections can be observed. They are composed of one or two cells within the terminal ducts or in interlobular ducts. These types of hyperplasia have been previously referred to as papillomatosis or epitheliosis and may appear diffuse or multifocal. Histologically, atypical cellular behaviors are determined by small cells with uniform and monomorphic nuclei. These cells form solid bridges across the ductal lumen with an organized layer of myoepithelial cells that delimit the duct. The discrimination between an atypical hyperplastic lesion (Figure 2A) and a low degree duct carcinoma *in situ* is difficult (Figure 2B). In these situations, the evaluation of the number and size of lesions should be considered as criteria to distinguish them. However, both are potentially malignant. Molecular studies have demonstrated that atypical ductal hyperplasia and low grade ductal carcinoma *in situ*, apparently, have similar chromosomal alterations and probably share a similar role in the malignant transformation of the mammary gland (59, 60).

II) Lobular hyperplasia - occurs in the terminal lobular units of the mammary gland. In this type of injury, epithelial cells have a distinct morphological behavior. The cell nuclei are small and round, predominantly located in a central position and presenting with low pleomorphism and sometimes a single intracytoplasmic vacuole. This

uniform population of cells occupies the acinar units, leading to the growth of such units. No more than four units are compromised in the typical lobular hyperplasia. When five or more acinar units are affected the lesion is classified as an atypical lobular hyperplasia. This is an important distinction for human studies, as it has been demonstrated that atypical lobular lesions have greater potential for malignant transformation than typical lesions (60).

III) Adenosis – An alteration characterized by an increased number of acini and dilatation of the intralobular duct, thereby increasing the overall diameter of the lobular units (Figure 2E, F). Mild alterations in epithelial, myoepithelial and fibrous periductal tissues can occur. This injury is followed by periductal fibrosis (sclerosing adenosis). It is uncommon among dogs and does not appear to be related to neoplastic progression (60).

Columnar cell lesions (CCLs)

CCLs comprise a group of processes characterized by dilatation of the terminal ducts organized in a columnar cell pattern, arranged in one or two cell layers, with or without atypia. These lesions are associated with intraductal calcifications, atypical intraductal hyperplasia projections, and benign neoplasias, carcinoma *in situ* and invasive carcinoma (63). It is likely that the

CCLs represent a step toward the development of several types of low-grade carcinoma *in situ* and invasive carcinoma (35, 126).

These alterations can be classified into three histological types:

I) Columnar Cell Change (CCC), characterized by acini dilatations which are delimited by a layer of epithelial cells arranged in a columnar fashion. The cell nuclei are elongated with moderate chromasia. Apical cytoplasm projections are often present as well as intraluminal secretion (Figure 2C).

II) Columnar cell hyperplasia (CCH) – columnar lesions similar to CCCs, but a superposition of two or more layers of columnar epithelial cells are observed in the terminal lobular units.

III) Atypical columnar cell lesions – characterized by alterations in columnar cells. The nuclei of these cells are hyperchromatic and ovoid and have a higher ratio of nucleus/cytoplasm, and are not perpendicularly oriented by the basement membrane (Figure 2D). Owing to the flattened epithelial surface, this type of alteration is appropriately termed as Flat Epithelial Atypia (FEA). Foci of micropapillary projections and cytoplasmic intraductal tufts can also be observed.

Benign Tumors

Adenoma

Adenoma is a benign neoplasia of well-differentiated epithelial or myoepithelial cells. Tumors composed of well-differentiated epithelial cells are classified as a simple tubular type and should be differentiated from adenosis. Despite the proliferation of tubular structures, adenosis retains their architectural pattern with intralobular ducts. This type of lesion is rare in dogs and the solid nodes composed of fusocellular cells are referred to as myoepitheliomas and may require p63 immunohistochemistry for confirmation (20).

Adenomyoepithelioma or complex adenomas

Adenomyoepithelioma is a benign tumor originating from the proliferation of epithelial and myoepithelial cells, but with no evidence of myxoid matrix formation. Its differentiation from complex well-differentiated carcinomas can be difficult. The presence of a capsule, absence of necrosis and atypia and low mitotic activity is the basis for diagnosis (20).

Basaloid adenoma

Basaloid adenoma is a benign tumor consisting of uniform cords and basaloid monomorphic epithelial cell nests. The peripheral cells assume a palisade arrangement and are orientated against a thin basal lamina. These tumors are usually small (20).

Fibroadenoma

Fibroadenoma is a benign tumor originating from the proliferation of epithelial and stromal elements. There are two types: pericanicular fibroadenoma (epithelium surrounded by stroma) and intracanalicular fibroadenoma (epithelium that is compressed and deformed by the stroma), and fibroadenoma of low or high cellularity (20).

Benign mixed tumor

Benign mixed tumors are characterized by benign proliferation of cells that are morphologically similar to epithelial components (luminal or myoepithelial) and mesenchymal cells that produce cartilage and/or bone and/or adipose tissue, possibly in combination with fibrous tissue (107) (Figure 3A).

The proliferating myoepithelial cells may appear fusiform or stellate, and are often embedded in abundant extracellular matrix (myxoid matrix). The proliferation of myoepithelial cells in association with the myxoid matrix are the origin of the ectopic cartilage observed in mixed tumors, suggesting that it is a result of (myo) epithelial-mesenchymal transition (21, 52) (Figure 3B). The cartilage appears in the form of nodules or plaques of variable sizes. The bone tissue consists of osteoblasts that synthesize osteoid and mineralized bone. Bone marrow hematopoietic tissue and fat interposition are eventually observed (4).

Some degree of pleomorphism and atypia is always present in this kind of tumor, which often make differential diagnosis difficult, particularly in the case of carcinomas in benign tumors.

The histogenesis of these tumors is the subject of several studies (21). The current consensus is to assume that all elements of cancer including those of a mesenchymal nature, originate from myoepithelial or ductal reserve cells. It is the most common benign tumor in dogs.

Ductal papilloma

This is a benign tumor, ramified or lobed in a distended duct, with organized proliferation of ductal epithelium on a well-defined fibrovascular axis. The epithelium is distributed as a single layer, has little cellular atypia or nuclear hyperchromasia and minimal mitotic activity. It is placed on a layer of myoepithelial cells (20) (Figure 3C, D).

Malignant Tumors

Carcinomas

Mammary carcinomas are classified as carcinoma *in situ*, carcinomas in mixed tumor, tubular carcinoma, papillary carcinoma, solid carcinoma, anaplastic carcinoma and special types carcinomas (micropapillary carcinoma,

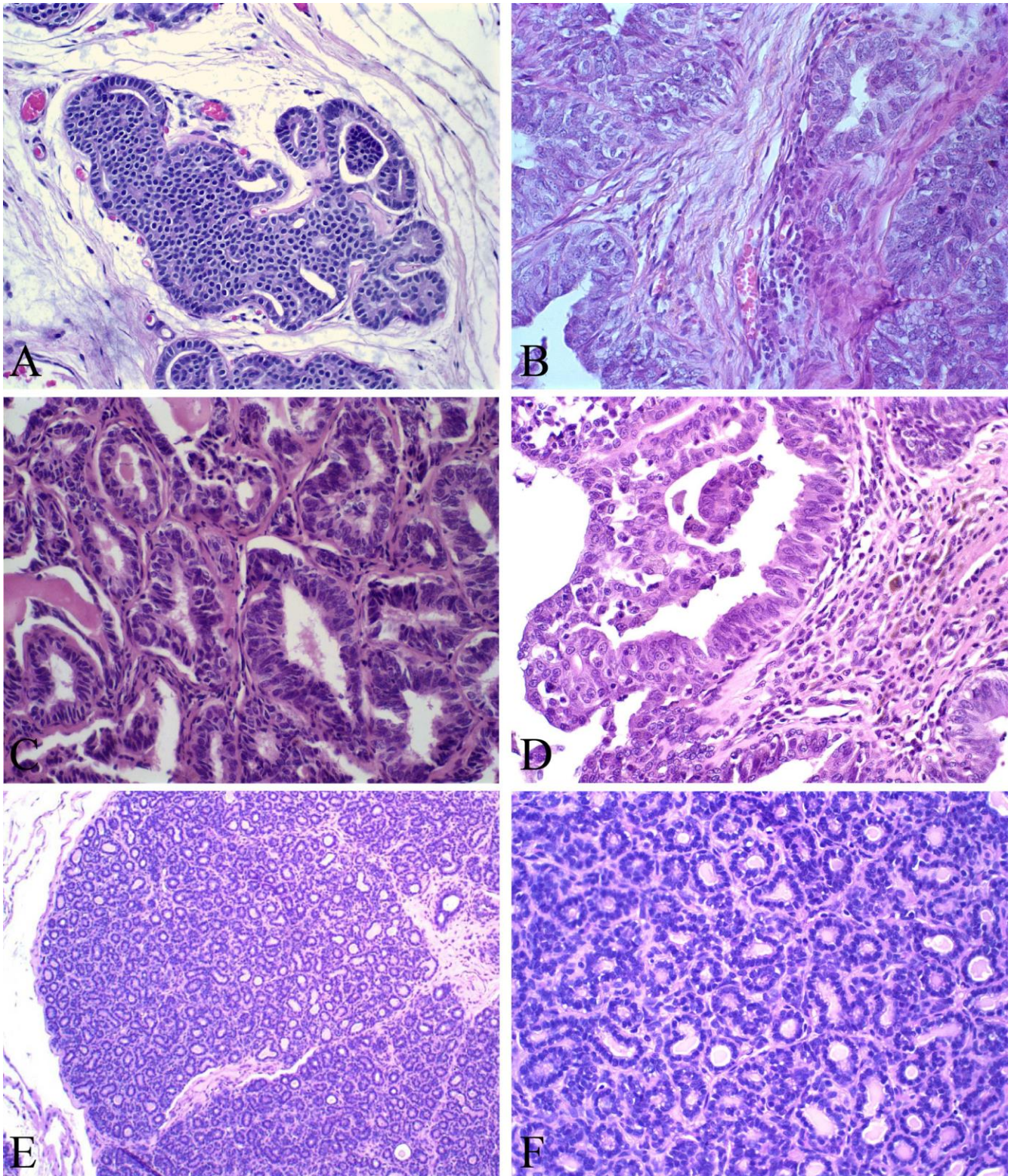


Figure 2. (A) Atypical ductal hyperplasia. H&E. 40x. (B) Ductal carcinoma *in situ*. PAS. 40x. (C) Columnar Cell Hyperplasia without atypia. H&E. 40x. (D) Columnar Cell Change with atypia. H&E. 10x. (E) Adenosis. H&E. 10x. (F) Adenosis. H&E. 40x

squamous cell carcinoma, mucinous carcinoma, secretory carcinoma, lipid-rich carcinoma and spindle cell carcinoma).

Carcinomas *in situ*

Different proliferative non-neoplastic mammary lesions are known as mammary cancer precursors in female dogs. However, carcinomas *in situ* are the only alterations recognized as precursor lesions of malignant transformation in the canine mammary gland, similar to human breast (3, 109).

Carcinoma *in situ* is characterized as a proliferation of malignant epithelial cells in the extralobular ductal units (Ductal Carcinoma *in situ*) or terminal lobular units of the mammary gland (lobular carcinoma *in situ*). The abnormal malignant cells occupy the ductal lumen with no discontinuity or absence of the basement membrane (77) (Figure 3E, F).

Carcinoma *in situ* with microinvasion areas is defined when the continuity of the basement membrane is lost, and nests of epithelial cells (< 1 mm) are present (77).

Ductal carcinoma *in situ* (DCIS)

This is the most common carcinoma *in situ*, often observed in association with invasive canine mammary carcinomas (solid carcinomas, papillary, carcinomas in mixed tumors). DCIS develops in the intra- or extra-lobular ducts. It is characterized by epithelial proliferations affecting more than two ductal units in the same histological section (Fig 3E, F). Epithelial cell proliferation exhibits an atypical cellular architecture characterized by connecting bridges along the ductal lumen and a layer of polarized epithelial cells associated with a continuous layer of myoepithelial cells. Microcalcifications are sometimes observed within the ductal lumen. DCIS can be associated with other types of non-neoplastic (hyperplasia and columnar cell lesions) and benign or malignant neoplasias. There is a direct correlation between the presence of DCIS, atypical columnar cell lesions and invasive mammary carcinomas in dogs (63).

The architecture of the proliferation of carcinomas *in situ* can be organized according to five different patterns: i) cribriform pattern, ii) papillary, iii) micropapillary, iv) solid, v) solid with central areas of necrosis (comedo), and the latter is predominantly observed in high grade *in situ* lesions.

DCIS grading

DCIS are categorized as low, intermediate and high grade lesions, depending on the cellular atypia level (mainly nuclear) and the loss of luminal polarization.

Low grade DCIS is characterized by a monomorphic cell pattern with no increase in nuclear size or fine and diffuse chromatin, mild prominent nucleoli and

lack of mitotic figures. High grade DCIS exhibit a significant level of cellular pleomorphism, nuclear diameters twice the size of normal ductal cells, loose or vesicular chromatin, multiple or prominent nucleoli and numerous mitotic figures (77).

Lobular carcinoma *in situ* (LCIS)

LCIS are termed as lobular lesions as the proliferation of epithelial cells leads to the filling and expansion of terminal lobular units. It affects more than 50% of the lobe and a complete loss of the lumen. However, there is no discontinuity or loss of the basement membrane (77).

The cell shape is invariable, the nuclei are small and spherical, and the nucleoli are uniform and discrete. There is a single cytoplasmic vacuole around the nucleus, represented by an invagination of the cytoplasmic membrane.

LCIS is a subtype of pleomorphic lobular carcinoma *in situ*, which is normally differentiated from invasive solid carcinoma. In this subtype, the proliferating cells exhibit pleomorphic nuclei and sometimes evident nucleoli, comedo type central areas of necrosis and microcalcifications. However, unlike the invasive carcinoma, this lesion exhibits no loss of continuity of the basement membrane.

Carcinoma in mixed tumor

Mixed tumors are frequent mammary gland neoplasias of the bitch. These tumors exhibit a complex histological pattern as they consist of components from epithelial and mesenchymal origin. Some can turn malignant, leading to the development of carcinoma in mixed tumors (107).

Carcinomas in mixed tumors are tumors that contain foci or nodules of epithelial cells with elevated pleomorphism and atypical mitosis, which arise in benign mixed tumors. Carcinoma proliferation can invade or completely replace the pre-existing benign lesion at the time of histopathological examination. The malignant epithelial cells often exhibit infiltrative growth, which can be identified by the loss of continuity of the basal/myoepithelial layer associated with clusters of tumor cells that penetrate into the stroma (41, 130) (Figure 4A). The occurrence of non-invasive carcinoma proliferations (*in situ*) can also be observed.

Microinvasion in carcinomas in mixed tumor

Differentiating between *in situ* and invasive carcinomas in mixed tumors is possible by the presence of stromal invasion and microinvasion. The invasion areas are characterized by the presence of clusters of infiltrative tumor epithelial cells in the periductal stroma near the carcinoma components. The microinvasion is identified by

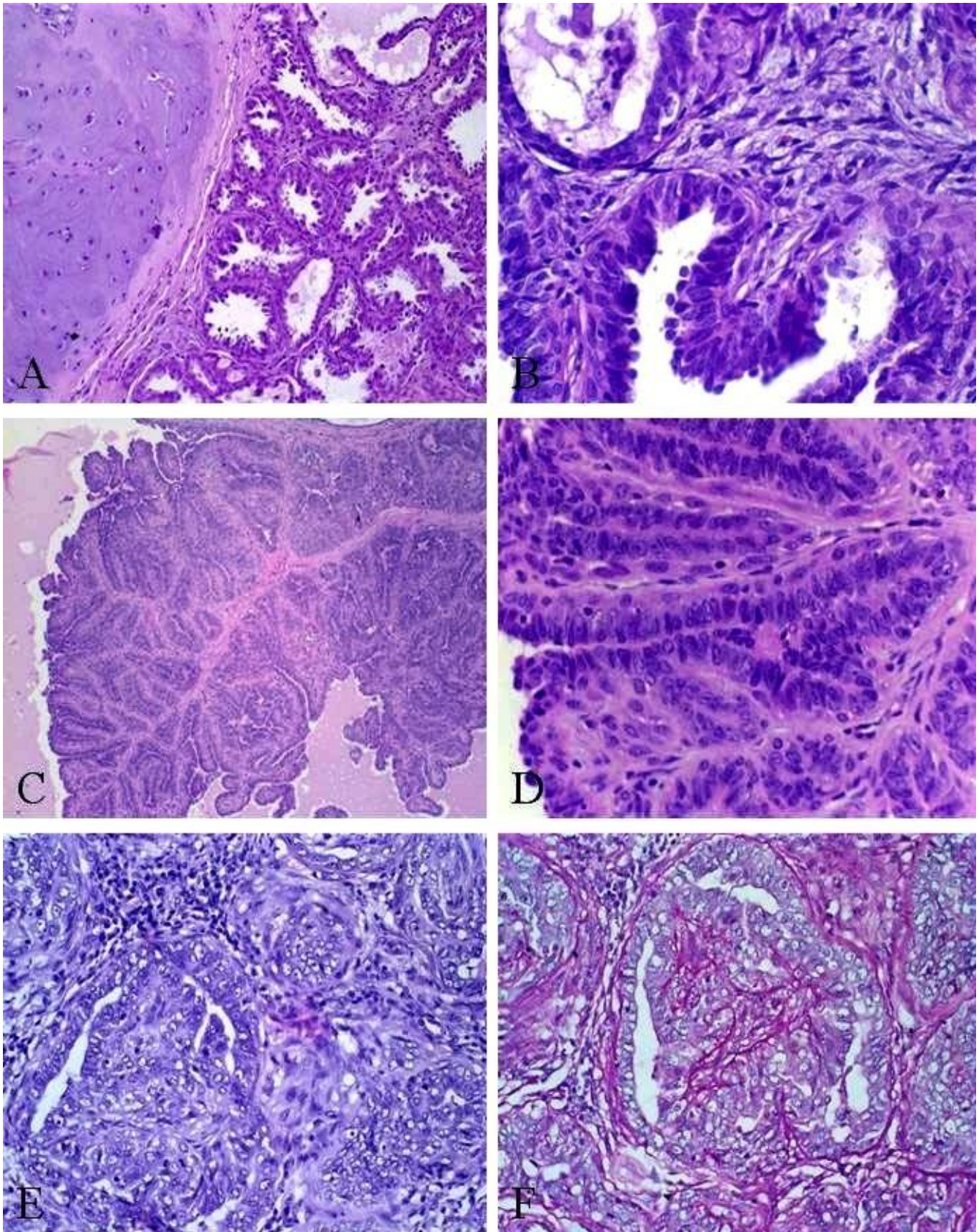


Figure 3. (A and B) Benign mixed tumor. H&E. 20x and 40x. (C and D) Papilloma. H&E. 10x and 40x. (E and F) Carcinoma *in situ*. H&E. 40x and PAS 40x.

the presence of carcinomas *in situ* areas with microscopic peripheral foci (with a diameter less than or equal to 1 mm) of neoplastic cells located beyond the basement membrane. Projections of neoplastic cells in continuity with areas associated with carcinomas *in situ* and disruption of the basement membrane are also considered as microinvasion (143).

Papillary carcinoma

Papillary carcinomas are tumors histologically characterized by papillary arborescent epithelial proliferation with central fibrovascular stroma (Figure 4B). Papillary lesions are classified as papillomas, carcinoma *in situ* in papillomas and non-invasive and invasive papillary carcinoma (135). The differentiation between benign and malignant variants is possible through the presence of myoepithelial cells within the neoplastic papillae located between epithelial cells and the basement membrane, which are not present in malignant tumors (160).

Papillomas with carcinoma *in situ* are characterized by the presence of benign papillary lesions associated with *in situ* carcinomatous areas which exhibit proliferation of uniform cells in solid or cribriform growth patterns (114, 160).

Non-invasive papillary carcinomas or encapsulated papillary carcinomas are usually solitary tumors. Well-defined lesions consisting of malignant papillary proliferation within a dilated duct are observed. Importantly, the cells are usually well differentiated with a low to moderate histological grade. The invasive papillary carcinoma is similar to that described above, but in this case areas of stromal invasion with no papillary morphology are usually present (114, 160).

For immunohistochemical analysis it is recommended that specific antibody labeling is used for myoepithelial cells since papillary malignant neoplasias (non-invasive and invasive papillary carcinomas) exhibit loss of myoepithelial cells, while this does not occur in benign neoplasias (papilloma). The most commonly used antibodies for this purpose are those that are specific for p63 protein and alpha-smooth muscle actin (114, 160).

Tubular carcinoma

This carcinoma is characterized by epithelial proliferation arranged in a predominantly tubular fashion (Figure 4C). The amount of stroma can vary considerably. Peritumoral lymphocytes are common whether necrosis is present or not. These tumors have a strong tendency to infiltrate into surrounding tissues and vessels (20).

Tumors with tubular and papillary areas are not rare. Using an adaptation of the classification system proposed by Seixas et al. (2007) (141) for feline micropapillary carcinomas, when carcinomas exhibit more than 60% tubular areas they are classified as tubular, if they exhibit more than 60% papillary areas they are

considered as papillary carcinomas. The so-called pure carcinomas are those with more than 90% prevalence of morphological characteristics.

Solid carcinoma

Solid carcinoma is a common type of mammary tumor in dogs. It is probably more advanced than the other types, as it is often observed when tumors develop over long time periods without surgical intervention.

Microscopically, there is proliferation of epithelial cells organized in a solid arrangement, with the formation of cords, sheets or clusters (Figure 4D). The tumor cells are undifferentiated, exhibit small and hyperchromatic nuclei, and the mitotic index is usually high (Figure 4E). Some solid carcinomas consist of cells that possess a vacuolated cytoplasm, possibly from myoepithelial origin. The amount of stroma can vary from small to moderate. Areas of necrosis are common (20).

Special types of carcinomas

Micropapillary carcinoma

Invasive micropapillary carcinoma of the mammary gland is a rare neoplasia, well described in humans, that is correlated to lymphotropism and to an unfavorable prognosis (96). In dogs, this tumor has been reported and exhibits similar behavior to those tumors observed in humans (29, 66, 68, 138).

Microscopically the tumor exhibits cystic spaces similar to lymphatic vessels that are diffusely distributed throughout the mammary tissue (Figure 5A). Inside these spaces are clusters of epithelial cells that exhibit a micropapillary pattern described as "morule-like" as well as abundant eosinophilic cytoplasm and a vesicular pleomorphic nucleus with prominent nucleoli. Invasive micropapillary areas can be associated with an *in situ* micropapillary carcinoma. *In situ* micropapillary areas are characterized by a malignant epithelial proliferation restricted to the duct (circumscribed by a basement membrane) containing nests of epithelial cells devoid of a fibrovascular core (Fig 5A). This *in situ* carcinoma generally exhibits intermediate nuclear grade (Fig 5B) (68). Moreover, micropapillary carcinomas can be defined as pure-type carcinomas, when more than 75% of the tumor is characterized by an invasive micropapillary pattern, and mixed-type carcinomas, when less than 75% of the tumor is characterized by an invasive micropapillary pattern associated with other infiltrating carcinomas (Fig 5C) (68). The mitotic index is variable and metastasis to lymph nodes is commonly observed (23, 29, 68).

In order to characterize the neoplasia the use of immunohistochemistry with a specific antibody for the epithelial membrane antigen (EMA) is recommended. This methodology allows investigators to identify the reversed polarity of the cluster of tumor cells that are in a

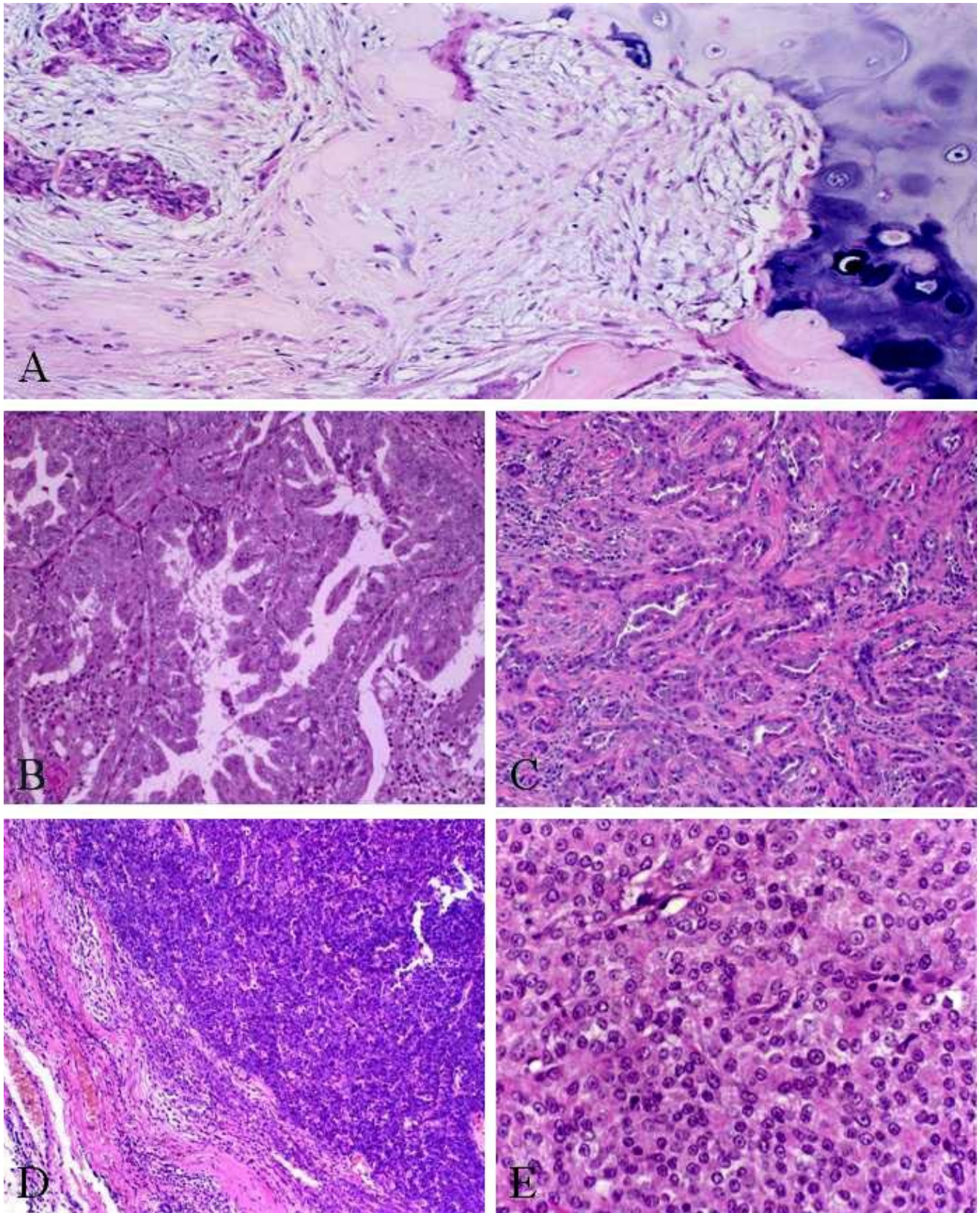


Figure 4. (A) Carcinoma in mixed tumor. H&E. 10x. (B) Papillary carcinoma. H&E. 10x. (C) Tubular carcinoma. H&E. 10x. (D) Solid carcinoma. H&E. 10x. (E) Solid carcinoma. H&E. 40x.

micropapillary arrangement, through the labeling of the apical plasma membrane. The use of endothelial markers such as CD-31 is recommended in order to differentiate between invasive areas and vessels. Gamba et al. (2013) (68) described positivity for hormonal receptors (estrogen and progesterone receptors) and cytokeratin 34 β E12; and negativity for HER-2 and EGFR in invasive micropapillary carcinomas in bitches.

Invasive lobular carcinoma

Invasive lobular carcinoma (ILC) is a neoplasia that represents 5-15% of all invasive breast tumors in women (144). Patients with ILC do not have a better prognosis than those with invasive ductal carcinoma. Histologically, the neoplasia is composed of small cells in a linear arrangement ('Indian row') that are uniform in size and do not reveal polarity.

It is also characterized by diffuse invasion and a large amount of fibrous stroma. Neoplastic cells sometimes constitute solid foci and occasionally contain mucin with a signet-ring appearance. In addition, the cells might be disposed in a concentric (targetoid) fashion around benign ducts. In humans, ILC is usually accompanied by *in situ* lobular lesions as in lobular carcinoma *in situ* (157).

ILC has recently been described in three dogs (127) and neoplastic cells in the primary lesions were immunohistochemically positive for cytokeratin and CK34 β E12, but negative for E-cadherin. In two dogs, subcapsular and medullary sinuses of lymph nodes were infiltrated by rounded cells morphologically similar to those of the primary tumor. However, it was difficult to distinguish these from sinusoidal macrophages as described for human patients (157). Pulmonary metastases were evident in two dogs after 63 and 80 days from first diagnosis.

Pleomorphic lobular carcinoma

Pleomorphic lobular carcinoma in humans is recognized as a variant of invasive lobular carcinoma (136, 137). The prognosis is unfavorable owing to their aggressiveness, and affected patients have a short survival time (45). In the dog, this histological type was first described in 2002, by considering the cytomorphological and immunohistochemical similarities with breast lesions in women (28).

Microscopically, tumor epithelial cells are dispersed in the stroma or arranged in a linear pattern exhibiting an irregular cell outline, abundant eosinophilic cytoplasm, pleomorphic and eccentric nuclei (136) (Figure 5D). Cytoplasmic vacuoles are often present and are easily stained with PAS (Periodic Acid Schiff) (28). Using immunohistochemistry they can be characterized by high cellular proliferation (KI-67), and CAM 5.2 positivity associated with loss of expression of the progesterone receptor, p53 and c-erbB2 (28). The absence of E-cadherin

expression at the plasma membrane is an important finding for the characterization of this histological type (163). Positivity in the cytoplasm for this molecule represents an abnormality in its expression pattern (28).

Secretory carcinoma

Secretory carcinoma is a neoplasia that rarely occurs in humans. In dogs the cytological, histological and immunophenotypical findings have been reported.

From fine needle aspiration samples, isolated cells are observed with round to oval shape and associated with numerous clusters of neoplastic epithelial cells. The nuclear chromatin is irregularly distributed with fragmented nucleoli. The cytoplasm is abundant and clear, with large secretory vacuoles that often displace the nucleus to the periphery (23). Histopathological analysis demonstrates an infiltrative carcinoma composed of cells with clear cytoplasm and prominent vacuoles that displace the nucleus to the periphery, resembling signet ring cells (Figure 6A). The pattern of proliferation can be solid and/or tubular containing eosinophilic secretion-filled spaces (24, 136). Neoplasias producing extracellular and intracellular content, as the lipid-rich carcinoma, rich in glycogen and mucinous should be considered as a differential diagnosis for secretory carcinoma. Differentiation between the neoplasias can be made by using Periodic Acid Schiff (PAS) staining associated with treatment with the enzyme diastase. The intracytoplasmic content of secretory carcinoma cells is PAS positive. In contrast, cells that compose in the lipid and glycogen-rich carcinomas are PAS negative. Alpha-lactalbumin is resistant to diastase in a different way from that observed for glycogen. Moreover, immunohistochemistry allows investigators to observe intracytoplasmic alpha lactalbumins that are produced by cells of the secretory carcinoma (136, 155).

Mucinous carcinoma

This tumor is not well described in the veterinary literature and is characterized by the presence of abundant extracellular mucinous material (105). It is known as gelatinous carcinoma, colloid, mucous or mucoid (134). In humans, when the histological pattern is considered pure, patients have a good prognosis as they present a long survival time (118, 134). Studies evaluating the clinical and pathological factors in dogs are scarce (11, 20, 106). This histological type is characterized by proliferation of epithelial cells that may compose arrangements in solid, tubular or papillary structures with spaces filled with large amounts of eosinophilic mucinous secretion reactive to the PAS-staining in diastase and Alcian Blue (11, 106, 107) (Figure 6B, C). At least 40% of its growth is composed of the mucinous pattern and accumulation of mucin is located predominantly in the intraductal component (134). However, leakage of mucoid substance can occur from this

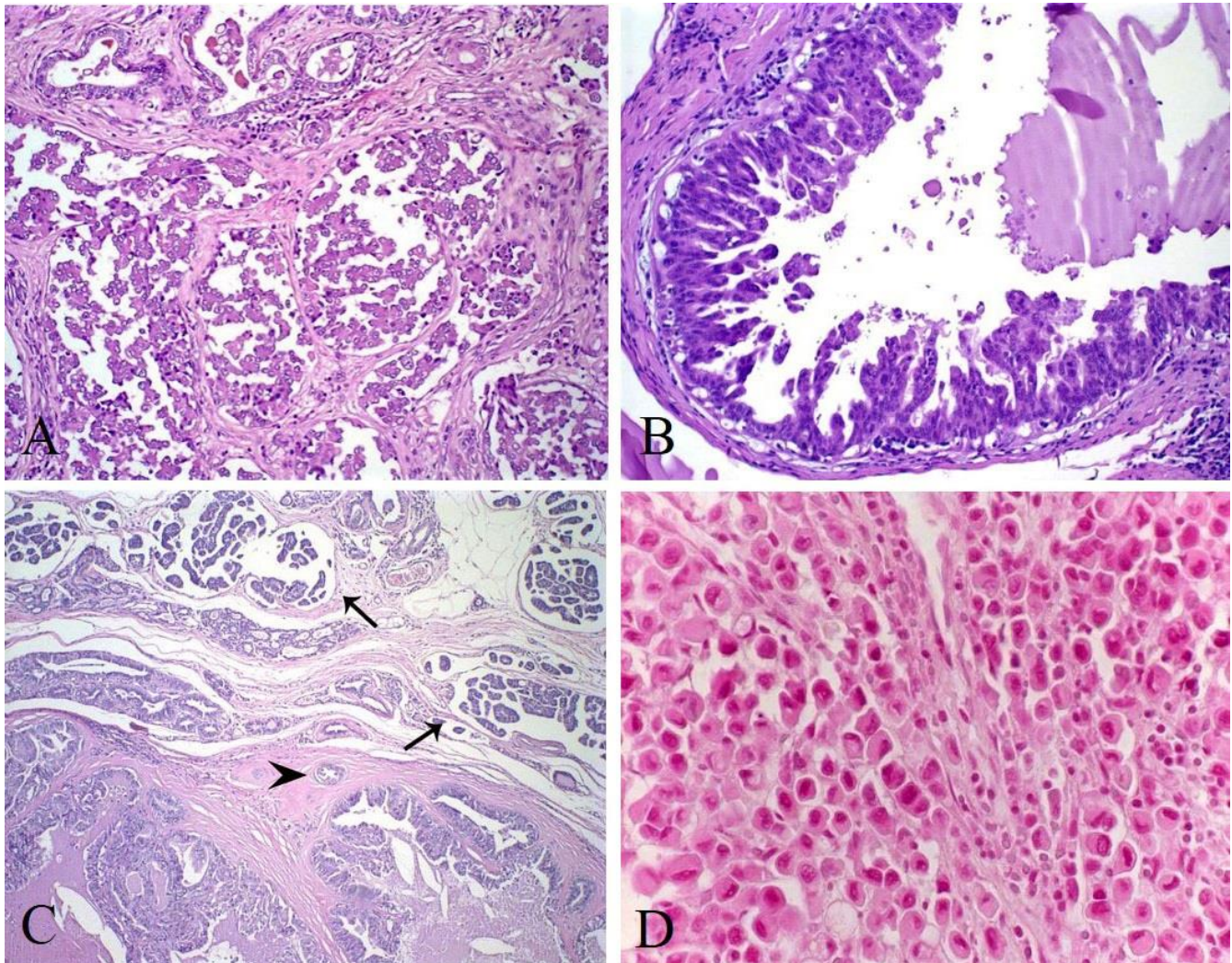


Figure 5. (A) Invasive micropapillary carcinoma. H&E. 10x. (B) *In situ* micropapillary area. H&E. 20x. (C) Invasive micropapillary carcinoma associated with invasive papillary carcinoma. Invasive micropapillary areas (arrows); Invasive papillary area (arrow head). H&E. 10x. (D) Pleomorphic lobular carcinoma. H&E. 40x.

intraductal structure, characterizing invasive mucinous carcinoma. If carcinoma-cells are present in mucoid medium, the diagnosis of invasive mucinous carcinoma is more appropriate (134).

Lipid-rich carcinoma

The lipid-rich carcinoma is considered a rare variant of invasive ductal carcinoma of human breast cancer and is extremely uncommon in dogs (53, 107).

The histological characteristic of the tumor is its expansive growth. Tumor cells are arranged in solid nests and cords separated by a moderate amount of stroma, they have vacuolated cytoplasm and a round to flat nucleus. Unique vacuoles that displace the nucleus to the periphery (signet-ring cell) are common. The malignant diagnosis is confirmed when more than 80% of the neoplastic cells are lipid-producing cells. Atypical cellularity ranges from moderate to high and lymphatic invasion can be observed.

To differentiate this tumor from other subtypes such as the secretory carcinoma and the glycogen-rich carcinoma, the use of "red oil O" and SUDAN III and IV is advised for staining intracytoplasmic lipid content on frozen sections. Moreover, the neoplastic cells that constitute lipid-rich carcinomas are PAS negative, unlike the case of secretory carcinoma (53, 120).

Immunohistochemical analysis with cytokeratins of various molecular weights and alpha actin yields varied results among affected dogs (53, 120).

Squamous cell carcinoma

This carcinoma is composed of cells in a solid arrangement in the form of sheets or cords with areas of squamous differentiation (Figure 6D). Basaloid cells are predominant in the periphery of the tumor. The center of more differentiated tumors consists of keratin layers, forming so-called keratin pearls. Many of these tumors are

highly infiltrative and lymphatic invasion is common. These should be distinguished from squamous cell carcinomas derived from the skin and appendages. This tumor is not common in dogs (20, 107).

Spindle cell carcinoma

The spindle cell carcinoma is an uncommon carcinoma subtype in dogs (107). Histologically, it is characterized by proliferation of spindle cells arranged in bundles, sometimes featuring a circular pattern. The tumor cells are characterized by an eosinophilic cytoplasm, often vacuolated and with oval vacuolated nuclei with fragmented chromatin. The confirmation of diagnosis requires that at least 80% of the tumor exhibits features of this subtype of carcinoma. The main differential diagnosis is fibrosarcoma. In spindle cell carcinomas multiple clusters of neoplastic cells are observed separated by reticular fibers, in fibrosarcomas the fibers are arranged between individual cells (16, 88, 136).

For confirmation of this neoplasia the use of immunohistochemical techniques and specific antibodies against proteins of mesenchymal (vimentin) and epithelial cells (cytokeratin) is recommended. The positive staining for cytokeratin confirms the epithelial origin of the neoplasia, discarding the occurrence of mesenchymal neoplasias such as fibrosarcoma. Moreover, for histogenetic study of the neoplasia, myoepithelial cell markers (alpha smooth muscle actin, p63 and S100) can be used (17).

Anaplastic carcinoma

This histological type is reported in dogs and is considered to have the worst prognosis because the affected female dogs present early recurrence and metastasis, which confirms its aggressiveness (95, 107).

These tumors are diffusely infiltrative and are characterized by atypical epithelial proliferation, without delineated arrangements, with individual cells invading the reactive, loose and abundant stroma (105, 107) (Figure 6E). The cells are large, anaplastic, with bizarre nuclei, fragmented chromatin and single or double prominent nucleoli (95). The mitotic index is high, with many atypical figures. Some cells may be multinucleated (95). Areas of invasion by neoplastic cells in blood and lymphatic vascular structures are observed. Intense inflammation is a strong feature of this tumor (105). Its distinction from inflammatory lesions can be difficult; therefore, the use of immunohistochemistry with specific antibodies (keratin to mark cancer cells and specific markers for histiocytes, such as lysozyme and α -1-trypsin) is recommended (107). Anaplastic sarcomas are frequently mistaken for this histological type. Therefore, vimentin expression and other muscle cell markers such as desmin, are useful for this distinction (107).

Mammary neoplasias with sebaceous differentiation

Mammary neoplasias may present different types of tissue differentiation in humans and dogs including bone, hematopoietic tissue and squamous epithelia (75, 107). However, sebaceous differentiation is rarely reported in mammary tumors in these species and its true importance is currently unknown. In human medicine, the World Health Organization classification for breast tumors has recognized it as a distinct subtype of invasive breast carcinomas (157). However, the presence of sebaceous morphology and other neoplasia components are highly variable among the reported cases, which makes classification criteria of mammary sebaceous carcinoma ambiguous. There is only one documented case in veterinary literature (33) in which two tumors were observed in the left inguinal mammary gland, both grossly presented as whitish to light brown multilobulated and superficially ulcerated masses. Microscopically, cells with abundant foamy cytoplasm resembling sebocytes were located within intraductal papillary-like nests of mammary carcinoma, suggesting sebaceous differentiation. In addition, large areas of a solid invasive sebaceous component were observed surrounding small-sized intraductal papillary neoplastic nests. Prognosis was guarded, since lymphatic spread was detected and the patient died three months after diagnosis.

Histochemically, the sebocyte-like cells are negative for PAS, Alcian Blue and mucicarmine stains; however, Oil Red O provides a positive staining pattern. In addition, immunohistochemical detection of adipophilin could be used in paraffin-embedded tissues to achieve a more accurate diagnosis (110).

Myoepithelial neoplasias

Malignant Adenomyoepithelioma

This is a malignant tumor that consists of the proliferation of epithelial and myoepithelial cells. However, there is no evidence of myxoid matrix. Differentiation from well-differentiated complex carcinomas and complex adenomas may be difficult. The absence of a capsule, presence of necrosis and atypia and high mitotic activity, support the diagnosis (20).

Sarcomas

Fibrosarcoma

These are malignant tumors of fibroblast cells with variable amounts of collagen. Such tumors are composed of spindle-shaped cells that produce collagen and are arranged as reticular fibers. The fibers can be arranged in parallel or disorganized. Fibrosarcomas and osteosarcomas are the most frequently encountered

mammary sarcomas in the dog (20).

Osteosarcoma

This is a sarcoma characterized by osteoid and/or bone formation by neoplastic cells. These sarcomas are non-combined (pure) or combined. The combined tumors are composed of osseous and cartilaginous malignant tissues. Pleomorphism and mitotic activity are usually prominent. However, the combined sarcomas and their metastases can be highly differentiated. Osteosarcomas occur predominantly in the dog (20).

Carcinosarcoma

These are rare tumors in women and have a poor prognosis compared with other types of carcinomas (159). In the dog, clinical and pathological features resemble those described in humans. The histological characteristics of this type are extremely variable and it was previously described as a malignant mixed tumor of the mammary gland (106). These tumors grow rapidly. Macroscopically they are often well delineated with a firm to bony cut surface (105). They are composed of cells that morphologically resemble epithelial cells (luminal epithelium and/or myoepithelial) and they present with various types of differentiation including adeno-, solid, squamous, mucinous and anaplastic, and sarcomatous areas with fibro-, chondro- and osteomatous differentiation (106) (Figure 6F). Metastases are of mixed type, sarcomatous or carcinomatous (106).

Sarcoma in mixed tumor

These are tumors with mesenchymal malignant cell foci or distinct nodules in benign mixed tumors. The criteria for malignancy evaluation of the mesenchymal component of mixed tumors are the same as for sarcomas, which take into account cellularity, cytological atypia and mitotic index (57). Unlike carcinomas in mixed tumors, which are very frequent, the sarcomatous transformation in benign mixed tumors is very rare.

Other sarcomas

Pure chondrosarcoma, liposarcomas and hemangiosarcoma are very rare but when present in the mammary gland they have morphological features similar to those observed in other organs (107).

3. PROGNOSIS

Prognostic and predictive markers

Prognostic factors can be defined as one or more specific clinical, pathological or biological characteristics of individuals and their tumors that permit prediction of

clinical outcome and survival of patients without subjecting them to additional and adjuvant therapies after initial surgery (32). Otherwise, the evaluation of predictive markers allows the selection of patients for specific and individualized treatments (100).

The study of prognostic factors is of utmost importance, as it enables the behavior and clinical outcome of mammary gland neoplasias to be predicted using individualized therapeutic protocols with appropriate intensity and effectiveness (1, 36, 102, 170). In mammary tumors of female dogs, they are useful for studies concerning comparative pathology, and the search for experimental models for research (161).

In women's breast cancer, various clinical and pathological factors such as tumor size, lymph node involvement, histological type and grade are traditionally evaluated for clinical staging and prognosis. Currently, veterinary oncologists seek information concerning the histological variant of the tumor and other prognostic indicators (61). In this respect, the determination of mitotic index, a parameter measured in the histological grading system of Nottingham modified by Elston and Ellis (1998) (50), is an interesting prognostic tool for estimating cell proliferation in canine mammary tumors. The advantages of assessing the mitotic index include the fact that it is cost-effective, applicable to most histological types and can be performed on sections of formalin-fixed tissues, and demonstrates significant association with the Ki-67 label index (47).

Molecular markers have been evaluated as information sources for prognosis and to predict the behavior of various types of cancers in humans and animals. Hormone receptors (estrogen receptor - ER and progesterone receptor - PR), COX-2, a marker of the tumor proliferative index (Ki-67), a marker of angiogenesis (CD31), epidermal growth factor (EGF), adhesion molecules (E-cadherin and β -catenin), Her-2 and p53 are examples of prognostic markers evaluated in canine mammary tumors using immunohistochemistry (19, 42, 61, 67, 91, 92, 98, 102, 128, 158, 170, 171).

Estrogen, progesterone and epidermal growth factor receptors have been identified in female canine mammary tumors and there is coexistence of these receptors in the same neoplasia (105). It is believed that there is an inverse relationship between the number of hormonal receptors and the proliferative capacity of the neoplastic cells (19, 34, 69). The analysis of hormone receptors, COX-2 and KI-67 expression should be incorporated into the routine as it is associated with the indication of specific therapeutic protocols. In dogs, similar results to those described in women were observed in terms of increased expression of Ki-67 (immunohistochemical marker of cell proliferation) in malignant mammary tumors, particularly in less differentiated cancers, and by the inverse correlation with immunostaining for progesterone receptor (19).

Cyclooxygenase-2 (COX-2) is a potential marker

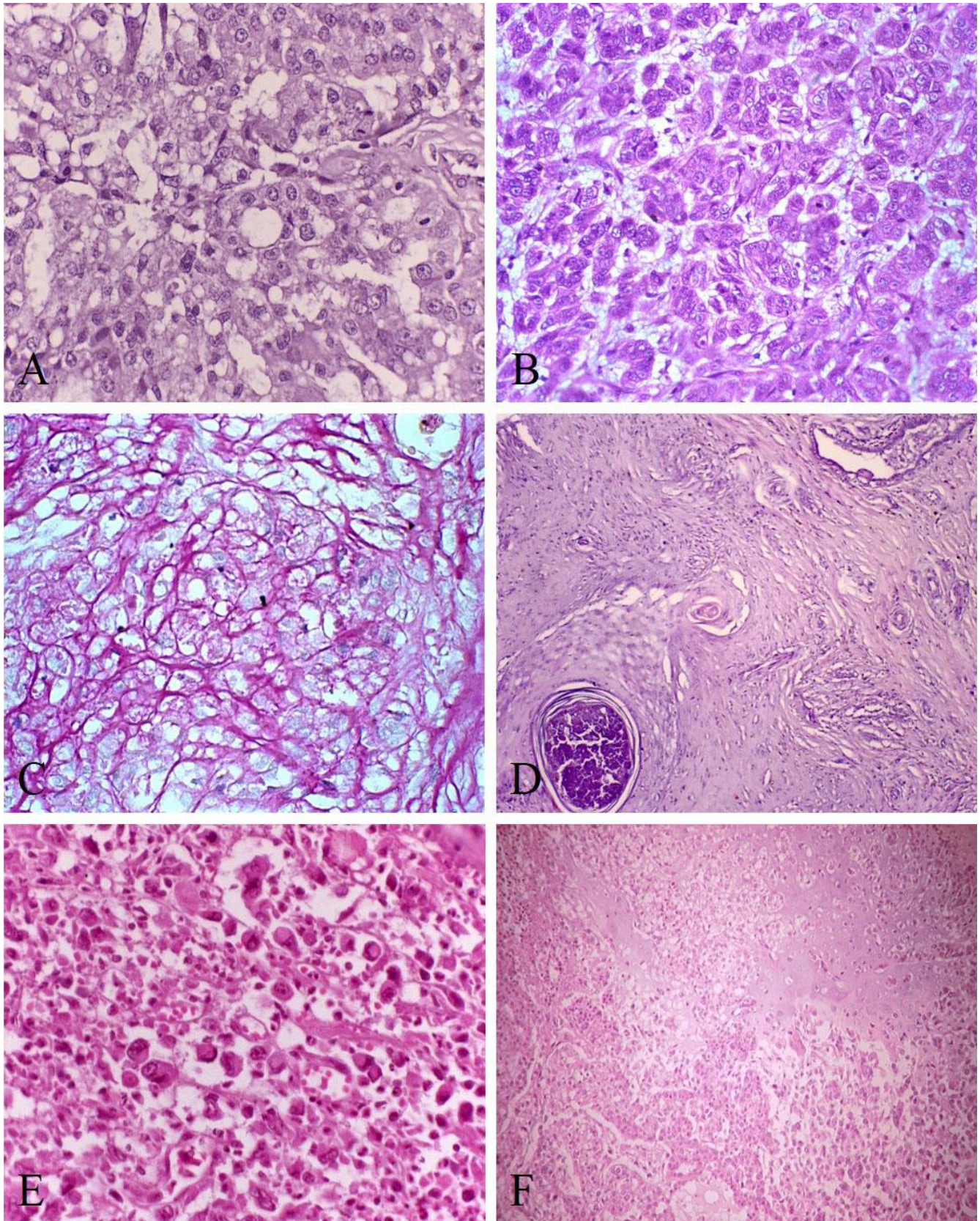


Figure 6. (A) Secretory carcinoma. H&E. 40x. (B) Mucinous carcinoma. H&E. 40x. (C) Mucinous carcinoma. PAS. 40x. (D) Squamous cell carcinoma. H&E. 10x. (E) Anaplastic carcinoma. H&E. 40x. (F) Carcinosarcoma. H&E. 10x.

for mammary cancer in women and dogs as its expression is higher in tumors with poor prognosis. It is inversely correlated with the overall survival rate, which changes the prognosis (92, 129). Some studies correlate the high expression of COX-2 to malignancy, increased proliferative capacity of neoplastic cells, decreased apoptotic rate and neovascularization, factors that increase the metastatic potential of the tumor cells (46).

High levels of angiogenic factors and histological evidence of increased tumor neovascularization detected by measuring the density of microvessels has been described as being of important prognostic value in human medicine for various solid tumors (149). Other factors such as reduction or loss of E-cadherin and β -catenin expression are associated with lower tumor cell differentiation, invasiveness and metastasis to regional lymph nodes (11), directly influencing prognosis (67).

Several studies demonstrate that HER-2 protein over-expression correlates with shorter survival, shorter disease-free periods and poor prognosis in humans (121, 149). Furthermore, mutations in the p53 gene are frequent in malignant mammary tumors of the dog and are associated with tumor progression (162).

Tumor markers are mostly normal cellular metabolism products that have increased production due to malignant transformation. These markers indicate malignancy and are characterized by substances present in the tumor, blood or other fluids. The most widely used serum markers in women breast cancer are cancer antigen 15.3 (CA 15.3) and carcinoembryonic antigen (CEA). Campos et al. (2012) (15) demonstrated an association between the presence of advanced mammary cancer in female dogs and an increase in serum CA15.3 levels, indicating a possible new serum tumor marker.

The identification of tumor markers is a valuable method for predicting the behavior of the neoplasia and to determine the prognosis of the disease. However, an accurate prognosis of a canine patient with mammary tumor can be difficult, since the biological behavior of these tumors varies considerably. Therefore, in veterinary medicine the increasing incidence and complexity of the clinical outcome of mammary tumors in female dogs have attracted special interest in the study of prognostic markers and their standardization so that they can be used as independent prognostic factors.

Evaluation of markers

The evaluation of immunostaining is variable and dependent on the antibody. It can be quantitative, qualitative or semi-quantitative.

The most commonly used antibodies for immunohistochemical evaluation of mammary tumors are the markers for hormone receptors (ER and PR) that allow assessment of the degree of differentiation of the neoplasia, and markers of cell proliferation (Ki-67) that determine the rate of cell proliferation and specific

antibodies that are important for assessing the expression of growth factor receptors (HER-2 and EGFR). Lower survival was recently demonstrated for patients whose tumors had a higher density of microvessels and increased expression of Cox-2 (92).

Evaluation for ER and PR immunostaining is based on the semi-quantitative analysis adopted by the American Society of Clinical Oncology / American College of Pathology (ASCO / ACP). In this system, specimens are scored as positive when more than 1% of tumor cells present nuclear staining (76).

Evaluation of Ki-67 staining (clone MIB-1) should be considered using a high magnification field (40X) and tumors are ranked as a high proliferative index (more than 25% labeled nuclei), intermediate proliferative index (between 10% to 25% of labeled nuclei) or low proliferative index (less than 10% labeled nuclei) (86). Peña et al. (1998) (116) applied this cutoff and reported an association between high values of Ki-67 and high risk of metastasis.

Cox-2 label analysis is semi-quantitative and the distribution score is estimated by the percentage of positive cells in five fields of high magnification (40x). For all tumors, a value of distribution between 0 and 4 is obtained, where 0 means 0%, 1 means less than 10% of cells labeled, 2 for 10 to 30%, 3 for 31 to 60 and 4 over 61% of labeled cells. Values for the intensity of staining are given from 0-3, where 0 means no labeling (-), 1 is equivalent to weak labeling (+), 2 for moderate labeling (+ +) and 3 for strong intensity (+ + +). The final score ranges from 0 to 12 and is obtained by multiplying the intensity and distribution values (46, 78).

For HER-2 and EGFR, the semi-quantitative method proposed by the American Society of Clinical Oncology/American College of Pathology (ASCO/ACP) (7, 167) is used. The sample is considered negative with scores of 0 to 1+, indeterminate with a 2+ score and positive for 3+ score. The score 0 is characterized by absence of labeling of the cytoplasmic membrane; 1+ when membrane labeling is weak and incomplete in any proportion of tumor cells, 2+ when labeling is complete, uneven and of low intensity in more than 10% of tumor cells or complete and intense membrane labeling of 30% or less of tumor cells; 3+ for more than 30% of complete uniform and intense membrane labeling in tumor cells.

4. TREATMENT

Surgery

Surgery is the first-line treatment for canine mammary tumors, except for inflammatory carcinoma (107). It is considered the most effective therapy for disease regional control (146). Thus, the complete surgical removal of localized tumors without metastatic involvement is the therapeutic procedure with highest probability of cure. Surgical excision also allows

histopathological examination increases survival time and patient's quality of life (42). Surgical excision may be curative in dogs with stage I of the disease and small tumors, non-invasive and well differentiated carcinomas. Dogs with large and high grade tumors, with a greater chance of metastatic development may benefit from additional therapy (146).

The lymphatic system is considered the main route for metastasis of malignant tumors of the mammary gland in dogs. It is important that the surgeon has knowledge concerning lymphatic drainage of canine mammary tumors so that the surgical excision can be performed adequately and an accurate prognosis is determined (115).

Patsikas et al. (2006) (115), studying the lymphatic drainage of neoplastic mammary glands, reported that thoracic cranial and caudal breasts drain toward the ipsilateral axillary lymph nodes. The abdominal cranial breast drains mainly into the axillary lymph node, but simultaneously into the ipsilateral superficial inguinal lymph node. The caudal and inguinal abdominal glands drain into the ipsilateral superficial inguinal lymph node. Furthermore, they report that lymphatic connections between neoplastic and normal adjacent mammary glands are rare but can occur. Therefore, the use of patent blue as mentioned above is recommended.

Therefore, the extent of surgery depends on the patient stage, lymphatic drainage, size and location of lesions. Lumpectomy must be considered for the removal of single solid superficial non-adherent small tumors, at most 0.5 cm. Larger lesions implies the need to remove the entire gland. Mammectomy or simple mastectomy is indicated for lesions up to three centimeters, affecting only one gland whilst regional mastectomy or in block resection is indicated for the removal of lymphatic connections of glands affected by lesions larger than three centimeters (10, 147). In this case, it is important to ensure the removal of the whole tissue interposed between the mammary gland and lymphatic drainage (108). The removal of cranial abdominal gland during regional mastectomy may be necessary in order to obtain adequate surgical margins or for lesions up to three centimeters located in this gland. Radical mastectomy consists in the removal of a unilateral mammary chain, when lesions larger than three centimeters affect the cranial abdominal gland. Regional and radical mastectomies may also be performed on patients with multiple lesions, to obtain a single surgical wound through a single incision and resection of mammary tissue (80, 147).

The inguinal lymph nodes must be resected in bloc, along the inguinal mammary gland, whenever this gland is removed or, by the same way as axillary lymph nodes, when changes in their shape, volume or consistency are observed or if a more accurate evaluation of lymph nodes is desired (147).

Palliative surgery in patients with mammary tumors aims at improving the quality of life without

providing a cure or even influencing on prognosis. This type of intervention is usually conducted from removal of the primary tumor when the patient already has metastatic lesions, providing relief from the direct effects of the tumor, such as pain and bleeding, when it is ulcerated, or even preventing ulcerations (39).

The advantages and disadvantages of extent and conservative surgical procedures have been extensively discussed. When studying the biological behavior of canine mammary tumors, Gilbertson et al. (1983) (70) indicated radical mastectomy as the optimal surgical option. In the same year, Brodey et al. (1983) (10) advocated individual treatments, in which the surgical procedure should respect known lymphatic connections and base itself on tumor location, number and size of lesions and existence of skin or muscular adhesences. A prospective study conducted by MacEwen et al. (1985) (97) with 144 dogs, did not find any difference between the recurrence rate and the survival time when the single mastectomy was compared to chain mastectomy. However, Stratmann et al. (2008) (153) described radical mastectomy as the best surgical option, regardless of the number and the size of lesions. Authors reported a greater probability of new tumor growth ipsilateral to the first surgery, although statistical significance was not assessed. Another study with 143 non-spayed dogs submitted to different surgical techniques according to well-established prognostic factors, no significant difference was found regarding recurrence or new lesion development (80).

Aggressive procedures, or prophylactic surgery, by means of a unilateral or bilateral mammary strip, can, of course, prevent mammary neoplasia developing in the future and may benefit a small number of patients, especially intact young dogs, with multiple lesions (147). This is, however, an extremely invasive procedure with significant risk of perioperative complications (124). Conservative approaches, based on well-established prognostic factors, may favor a better postoperative recovery in respect to these patients' quality of life, without any prejudice related to tumor control. Nevertheless, further investigations are required to assess the efficacy of more aggressive surgical techniques in patients with particular histological and prognostic features.

Chemotherapy

Women diagnosed with breast cancer are commonly treated with chemotherapy in an adjuvant setting to try to prevent or delay the development of metastasis in more aggressive cases. Additionally, neoadjuvant chemotherapy may be indicated for large tumor burdens and/or metastatic disease. Although adjuvant chemotherapy has been routinely used in dogs with malignant mammary gland tumors as an adjuvant therapy, there is limited information regarding the use and efficacy of chemotherapy in dogs with this disease (146),

mainly due to limited number of prospective studies. For this reason, there is no standard recommendation for the use of chemotherapy.

The toxicity of chemotherapeutic agents does not specifically target oncocytes; all of the patient's cells with high mitotic indices, including the normal ones, are affected. The most common side effects of antineoplastic agents are myelosuppression, gastrointestinal disorders, and alopecia (133). Karayannopoulou et al. (2001) (84) demonstrated that the combination of 5-fluorouracil (150 mg/m²) and cyclophosphamide (100 mg/m²), when administered on the same day weekly for four weeks, was well tolerated and exhibited a positive influence on the disease-free interval and survival time in dogs with complex carcinomas and carcinosarcomas. Marconato et al. (2008) (99) compared the time to local recurrence (TTR), time to distant metastases (TTM), and overall survival (OS) in a group of dogs with aggressive mammary carcinomas (simple carcinoma, squamous cell carcinoma, sarcoma, carcinosarcoma) treated with either surgery alone or in combination with adjuvant gemcitabine. Weekly adjuvant gemcitabine given at a dose of 800 mg/m² for at least four cycles was safe but did not result in any improvement in TTR, TTM, or OS when compared with surgery alone in dogs with aggressive mammary carcinomas. Lavallo et al. (2012) (93) demonstrated that animals treated with carboplatin, with or without Cox-2 inhibitors, had a statistically significant longer overall survival when compared with animals submitted exclusively to surgical treatment, indicating that this chemotherapeutic agent is beneficial for the treatment of malignant mammary gland neoplasias.

The protocols proposed in the literature consist of the use of doxorubicin associated with cyclophosphamide or the use of cisplatin or carboplatin as single drugs, but further studies are required to determine an efficient protocol for canine mammary tumors (39, 93, 108, 112, 147). The following protocols are also described in the literature:

Protocol: Doxorubicin and Cyclophosphamide

Day	Doxorubicin	Cyclophosphamide
1 st	X	
3 rd /4 th /5 th /6 th		X
22 nd	Repeat this cycle, every 21 days, 3 to 6 times total.	
Posology		
Doxorubicin: 30mg/ m ² / IV or 1mg/ kg/ IV (for dogs weighing less than 10kg).		
Cyclophosphamide: 50mg/ m ² / oral		

Protocol: Gemcitabine and Carboplatin

Day	Gemcitabine	Carboplatin
1 st	X	X
8 th	X	
22 nd	Repeat this cycle, every 21 days, 3 to 6 times total.	
Posology		
Gemcitabine: 200mg/m ² /IV, for 20 minutes, 4 hours before carboplatin.		
Carboplatin: 10mg/kg /IV, for 20 minutes.		

Protocol: Carboplatin

Day	Carboplatin
1 st	X
22 nd	Repeat this cycle, every 21 days, 3 to 6 times total.
Posology	
Carboplatin: 250 to 300mg/ m ² / IV, every 21 days.	

Protocol: Doxorubicin and Carboplatin (more appropriate in case of carcinosarcomas)

Day	Doxorubicin	Carboplatin
1 nd	X	
15 th		X
22 nd	Administrate the drugs interchangeably every 2 or 3 weeks, totalizing 3 administrations of each one.	
Posology		
Doxorubicin: 30mg/ m ² / IV ou 1mg/ kg/ IV (for dogs weighing less than 10kg).		
Carboplatin: 250 to 300mg/ m ² / IV, every 21 days.		

With occurrence of metastasis in the lung parenchyma or other organs, the treatment of choice is antineoplastic chemotherapy, and the use of paclitaxel has proved to increase survival in some cases (132).

Day	Paclitaxel
1 st	X
22 nd	Administer the drug every 21 days, 3 to 6 times total.
POSOLGY	
Paclitaxel: 170mg/ m ² / IV or 5mg/ kg/ IV	
Pre-medicate patients with dexamethasone and diphenhydramine three days before and after chemotherapy infusion to minimize the occurrence of hypersensitivity reactions.	

After histopathological evaluation, patients diagnosed with solid carcinomas, micropapillary carcinomas, anaplastic carcinomas and carcinosarcomas should undergo chemotherapy even when lymph node or lung metastasis is not evident. Chemotherapy is recommended for patients with metastasis regardless of the histological type of tumor.

Monitoring of patients should occur every three months in the first year after chemotherapy and every semester during the second year until completion of a two year period.

Cox inhibitors

Increased Cox-2 expression in canine mammary tumors has been associated with more aggressive tumors and a worse prognosis. Heller et al. (2005) (78) observed 50% immunostaining for Cox-2 in the analyzed tumors and higher staining in anaplastic carcinomas compared with adenocarcinomas. Lavalle et al. (2009) (92) observed that increased expression of COX-2 was associated with a worse prognosis and shorter survival time, and suggested that the use of COX-2 inhibitors may be an alternative in the treatment and control of advanced neoplastic disease of the mammary gland in female dogs.

Souza et al. (2009) (150) demonstrated strong COX-2 expression in inflammatory carcinomas and submitted these patients to treatment with piroxicam. An improvement in clinical conditions and increased survival of the treated animals was observed.

The use of Cox-2 inhibitors (firocoxib) is conditional upon completion of immunohistochemical analysis (score > 6) and confirmed Cox-2 positivity, reinforcing the use of immunohistochemistry for Cox-2 as a predictive factor for mammary cancer in dogs (92).

POSOLGY
Firocoxib: 5mg/ Kg/ oral – every 24 hours
Administration for 6 consecutive months, with monthly evaluation of renal function and hemogram.

Inflammatory carcinoma

In inflammatory carcinomas, as surgical neoplasia resection is not recommended, therapies that promote the effective control of pain associated with antineoplastic chemotherapy are indicated. Piroxicam at a dose of 0.3 mg/kg/oral every 24 hours or 0.5 mg/kg orally every 48 hours, has provided increased survival of dogs with inflammatory carcinoma (150). The administration should last as long as possible, and if the patient can tolerate the treatment it should last between three to six months. Another option for chemotherapy for this neoplasia is the combination of docetaxel and piroxicam. Recently, a new alternative treatment has been proposed using firocoxib

5mg/kg/oral every 24 hours in an attempt to provide clinical improvement (14).

Protocol: Docetaxel and Piroxicam

Day	Docetaxel	Piroxicam
1 st	X	Every day of the cycle
22 nd	Repeat this cycle, every 21 days, 3 to 6 times total.	

POSOLGY

Docetaxel: 30mg/ m²/ IV, every 21 days.

Pre-medicate patients with dexamethasone and diphenhydramine three days before and after chemotherapy infusion to minimize the occurrence of hypersensitivity reactions.

Piroxicam: 0,3mg/kg /oral/SID or 0,5mg/ kg/oral, every 48 hours.

Hormone therapy

According to Sorenmo (2003) (146), most mammary tumors in female dogs (both benign and malignant) expressed ER. Benign epithelial tumors and well-differentiated carcinomas often demonstrate positivity for ER, whereas poorly differentiated and anaplastic tumors tend to be negative for this hormone receptor (142, 61). Furthermore, dogs diagnosed with carcinomas positive for this receptor exhibit a higher survival rate (101).

The presence of hormone receptors in the mammary tumors of female dogs suggests that hormone therapy may be an alternative treatment for this species, as is the case in human medicine (146, 156). It is necessary to explore the anti-estrogenic therapeutic benefit in veterinary medicine by conducting studies using appropriate methodology and clinical follow-up.

With respect to ovariectomy (OH), Fonseca and Daleck (2000) (64) performed an extensive literature review and concluded that the development of mammary tumors in female dogs is an event programmed in the first years of life and is not influenced by the suppression of hormone stimuli at maturity. Steroid hormones play a relevant role in the pathogenesis of mammary neoplasias in dogs, similar to the case in humans. Early OH appears to be the only method of preventing the hormonal variability that occurs during the estrous cycle, which undoubtedly influences the development of these tumors. The classic study by Schneider et al. (1969) (139) demonstrated the protective effect of total hysterectomy with bilateral salpingo-oophorectomy (HSO) based on the number of estrous cycles exhibited by female dogs before surgery. When HSO was performed at the first estrus, the risk of mammary tumors was 0.5%; the risk increased to 8% and 26% when sterilization was performed after the second and

third estrous cycles, respectively. There is no consensus in the literature as to the protective effect of HSO when it is performed after the onset of cancer. OH at the time of surgical excision of the breast tumor in female dogs has no protective effect on the appearance of new tumors, metastases, or on the extension of life span. Most authors believe that HSO exerts no protective effect after the third estrous cycle independent of the presence of cancer (58, 108, 139, 147, 168).

The best time to perform HSO is currently under study, taking into consideration not only the prevention of mammary tumors but also the benefits and systemic consequences associated with the endocrine suppression induced by early spaying, especially the long-term one effects. The action of estrogen in the pre-pubertal stage interferes with the development of bones, muscles, sexual organs and the immune system, in particular. Riva et al. (2013) (131) observed that Golden Retriever dogs spayed in the pre-pubertal stage exhibited delayed epiphyseal plate closure and increased predisposition to musculoskeletal disorders, ruptured cranial cruciate ligament, and hip dysplasia, in particular, due to hypoestrogenism. Thus, spaying immediately after the first estrous cycle is an option that should be taken into consideration.

It is suggested that spayed dogs suffering from hormone receptor positive tumors can be treated with tamoxifen (0.8 mg /kg), but confirmatory studies are required (156).

Ovarian ablation, aromatase inhibitors, and tamoxifen are some treatment options in women with breast cancer characterized as endocrine responsiveness. Such therapies are known as endocrine therapies (ET) and are effective in improving disease-free and overall survival (72). In canine mammary gland neoplasias, the authors believe that ET may be considered as an important treatment option in dogs that present primary tumors and/or metastasis positive for hormonal receptors (through immunohistochemical positivity for ER and PR). Due to lack of studies on other therapy modalities, the most important type of ET for dogs remains as ovariectomy.

5. CONCLUDING REMARKS

According to the available literature the use of TNM clinical staging criteria and evaluation of classic morphological prognostic factors (tumor size, mitotic count, histological grade and type, and lymphatic involvement), well established for humans, are useful in assessing the prognosis of female dogs with mammary carcinomas. Therefore, the diagnostic criteria should be improved and standardized, and continued investment in the study of prognostic and predictive markers is needed so that these factors are employed routinely by veterinary pathologists and provided to physicians and surgeons in an attempt to achieve appropriate treatment planning so that new treatment options and longer survival for these

patients can be established. The aim is not to submit patients to unnecessary aggressive treatments or to fail to treat those who would benefit. The animal's quality of life should always be prioritized.

This II Consensus has taken one step further towards standardizing criteria regarding the diagnosis and treatment of canine mammary tumors. As affirmed by Lipscomb (2012) (94), "If groups of experts from not only oncology and pathology, but all the many fields of veterinary diagnosis, treatment and research will take it upon themselves to apply their knowledge and experience in a framework of evidence-based medical principals to devise recommendations for studies in their specialties, a new era of veterinary medical progress will begin".

References

1. ABREU E., KOIFMAN S. Fatores prognósticos no câncer da mama feminina. **Rev. Bras. Cancerol.**, 2002, 48, 113-31.
2. AJCC, American Joint Committee on Cancer.
3. ANTUOFERMO E., MILLER MA., PIRINO S., XIE J., BADVE S., MOHAMMED SI. Spontaneous mammary intraepithelial lesions in dogs - a model of breast cancer. **Cancer Epidemiol. Biomarkers Prev.**, 2007, 16, 2247-56.
4. AULER P., BERTAGNOLLI AC., FERREIRA E., CAMPOS G., DIAS APM., CAMPOS CB., CAMPOS LC., CASSALI GD. Myeloid metaplasia in canine mixed mammary tumors: occurrence and characterization. **Vet. Q.**, 2011, 31, 173-77.
5. BENTUBO HDL., SOBRAL RA., UBUKATA R., HONDA ST., XAVIER JG. Carcinoma inflamatório de mama em cadela - relato de caso. **Rev. Clin. Vet.**, 2006, 65, 40-4.
6. BERTAGNOLLI AC., CASSALI GD., GENELHU MCLS., COSTA FA., OLIVEIRA JFC., GONÇALVES PBD. Immunohistochemical expression of p63 and Np63 in mixed tumors of canine mammary glands and its relation with p53 expression. **Vet. Pathol.**, 2009, 46, 407-15.
7. BERTAGNOLLI, AC., FERREIRA, E., DIAS, EJ., CASSALI, GD. Canine mammary mixed tumors: immunohistochemical expressions of EGFR and HER-2. **Aust. Vet. J.**, 2011, 89, 312-17.
8. BESERRA HEO., GRANDI F., IBANEZ FJ., ROCHA NS., PINHEIRO LGP. Sentinel lymph node identification: the importance of new methodologies and preclinical studies in dogs. **Braz. J. Vet. Pathol.**, 2013, 6, 5.
9. BOSTOCK DE. Canine and feline mammary neoplasias. **Br. Vet. J.**, 1986, 142, 506-15.
10. BRODEY RS., GOLDSCHMIDT MH., ROSZEL JR. Canine mammary gland neoplasias. **J. Am. Anim. Hosp. Assoc.**, 1983, 19, 61-90.
11. BRUNETTI B., SARLI G., MARCATO PS., BENAZZI C. Histochemical and immunohistochemical

- characterization of canine mammary mucinous carcinoma. **J. Comp. Pathol.**, 2003, 129, 131-36.
12. BRUNETTI B., SARLI G., PREZIOSI R., MONARI I., BENAZZI C. E-Cadherin and β -catenin reduction influence invasion but not proliferation and survival in canine malignant mammary tumors. **Vet. Pathol.**, 2005, 42, 781- 87.
 13. CABANAS RM. An approach for the treatment of penile carcinoma. **Cancer**, 1997, 39, 456-66.
 14. CAMPOS LC., LAVALLE GE., CARNEIRO RA., DUTRA AP., VIANA AAS., CASSALI GD. Carboplatina e inibidor de COX-2 no tratamento do carcinoma inflamatório de mama em cadela: relato de caso. **Rev. Clin. Vet.**, 2011, 92, 72-76.
 15. CAMPOS LC., LAVALLE GE., ESTRELA-LIMA A., MELGACO JC., FARIA O., GUIMARAES JE., DUTRA AP., FERREIRA E., SOUSA LP., RABELO EML., COSTA AFDV., CASSALI GD. CA15.3, CEA, and LDH in dogs with malignant mammary tumors. **J. Vet. Intern. Med.**, 2012, 26, 1383-88.
 16. CARDOSO MJL., BARBOSA MVF., SILVA SRV., ROCHA NS., FABRIS VE. Inflammatory mammary carcinoma in bitch. **Rev. Bras. Med. Vet.**, 2002, 24, 262-64.
 17. CARTER MR., HORNICK JL., LESTER S., FLETCHER CD. Spindle cell (sarcomatoid) carcinoma of the breast: a clinicopathologic and immunohistochemical analysis of 29 cases. **Am. J. Surg. Pathol.**, 2006, 30, 300-9.
 18. CASSALI GD. Comparative mammary oncology: canine model. **BMC Proc.**, 2013, 7, Suppl 2, K6.
 19. CASSALI GD. **Estudos morfológicos, imunohistoquímicos e citométrico de tumores mamários da cadela – aspectos comparativos com neoplasias da mama humana.** (2000). 73 f. (Doutorado) - Ciência Animal, Universidade Federal de Minas Gerais, Belo Horizonte, 2000.
 20. CASSALI GD. Patologias da glândula mamária. NASCIMENTO EF., LIMA RS. (Ed.). **Patologia da reprodução dos animais domésticos.** 3 Ed. Rio de Janeiro: Guanabara Koogan, 2002, 2, 131-33.
 21. CASSALI GD., BERTAGNOLLI AC., FERREIRA E., DAMASCENO KA., GAMBA CO., CAMPOS CB. Canine mammary mixed tumors: a review. **Vet. Med. International**, 2012, 1-7.
 22. CASSALI GD., BERTAGNOLLI AC., LAVALLE GE., TAVARES WLF., FERREIRA E., SILVA AE., CAMPOS CB. Perspectives for diagnosis, prognosis and treatment of mammary neoplasias in dogs. 34th World Small Animal Veterinary Congress - WSAVA 2009, São Paulo. **Proceedings of the 34th World Small Animal Veterinary Congress - WSAVA**, 2009.
 23. CASSALI GD., GÄRTNER F., VIEIRA DA SILVA MJ., SCHMITT FC. Cytological diagnosis of a metastatic canine mammary tumor in pleural effusion. **Arq. Bras. Med. Vet. Zootec.**, 1999, 51, 307-10.
 24. CASSALI GD., GOBBI H., GARTNER F., SCHMITT FC. Secretory carcinoma of the canine mammary gland. **Vet. Pathol.**, 1999b, 36, 601- 03.
 25. CASSALI GD., GOBBI H., MALM C., SCHMITT F. Evaluation of accuracy of fine needle aspiration cytology for diagnosis of canine mammary tumors: comparative features with human tumors. **Cytopathol.**, 2007, 18, 191-96.
 26. CASSALI GD., GOBBI H., MALMA C., OLIVEIRA SR., GHELLER VA. Protocol for the examination of cytologic specimens obtained by fine needle aspiration biopsy (FNAB) of canine breast tumors. **Arq. Bras. Med. Vet. Zootec.**, 1998, 50, 475-78.
 27. CASSALI GD., LAVALLE GE., DE NARDI AB., FERREIRA E., BERTAGNOLLI AC., ESTRELA-LIMA A., ALESSI AC., DALECK CR., SALGADO BS., FERNANDES CG., SOBRAL RA., AMORIM RL., GAMBA CO., DAMASCENO KA., AULER PA., MAGALHÃES GM., SILVA JO., RAPOSO JB., FERREIRA AMR., OLIVEIRA LO., MALM C., ZUCCARI DAPC., TANAKA NM., RIBEIRO LR., CAMPOS LC., SOUZA CM., LEITE JS., SOARES LMC., CAVALCANTI MF., FONTELES ZGC., SCHUCH ID., PANIAGO J., OLIVEIRA TS., TERRA EM., CASTANHEIRA TLL., FELIX AOC., CARVALHO GD., GUIM TN., GUIM TN., GARRIDO E., FERNANDES SC., MAIA FCL., DAGLI MLZ., ROCHA NS., FUKUMASU H., GRANDI F., MACHADO JP., SILVA SMMS., BEZERRIL JE., FREHSE MS., ALMEIDA ECP., CAMPOS CB. Consensus for the diagnosis, prognosis and treatment of canine mammary tumors. **Braz. J. Vet. Pathol.**, 2011, 4, 153-80.
 28. CASSALI GD., GÄRTNER F., SCHMITT FC. Pleomorphic lobular carcinoma of the canine mammary gland: histopathologic and immunohistochemical features. **Arq. Bras. Med. Vet. Zootec.**, 2002, 54.
 29. CASSALI GD., SERAKIDES R., GÄRTNER F., SCHMITT FC. Invasive micropapillary carcinoma of the dog mammary gland. A case report. **Arq. Bras. Med. Vet. Zootec.**, 2002, 24, 366-69.
 30. CASTELLANO MC., IDIART JR. Carcinoma mamário inflamatório em la perra. **Rev. Med. Vet.**, 1994, 76, 244-48.
 31. CAVALCANTI MF. **Fatores prognósticos na abordagem clínica e histopatológica dos carcinomas mamários de cadelas: estadiamento TNM e sistema de Nottingham.** (2006). 106 f. (Mestrado) - Patologia, Universidade Federal de Minas Gerais, Belo Horizonte, 2006.
 32. CAVALCANTI MF., CASSALI GD. Fatores prognósticos no diagnóstico clínico e histopatológico dos tumores de mama em cadelas - revisão. **Rev. Clin. Vet.**, 2006, 11, 56-64.
 33. CHANG SC., LIAO JW., WONG ML., LAI YS., LIU CI. Mammary carcinoma with sebaceous differentiation in a dog. **Vet Pathol.**, 2007, 44, 525-27.
 34. COSTA C., SOARES R., REIS-FILHO JS., LEITÃO

- D., AMENDOEIRA I., SCHMITT FC. Cyclooxygenase 2 expression is associated with angiogenesis and lymph node metastasis in human breast cancer. **J. Clin. Pathol.**, 2002, 55, 429-34.
35. DABBS DJ., CARTER G., FUDGE M., PENG Y., SWALSKY P., FINKELSTEIN S. Molecular alterations in columnar cell lesions of the breast. **Mod. Pathol.**, 2006, 19, 344-49.
36. DAGLI MLZ. The search for suitable prognostic markers for canine mammary tumors: A promising outlook. **Vet. J.**, 2008, 177, 3-5.
37. DALECK CR., DE NARDI AB., RODASKI S. **Oncologia em cães e gatos**. 1 ed. São Paulo: Roca, 2009.
38. DALECK CR., FRANCESCHINI PH., ALESSI AC., SANTANA AE., MARTINS MIM. Aspectos clínico e cirúrgicos do tumor mamário canino. **Ciênc. Rural**, 1998, 28, 95-100.
39. DALECK CR., RODASKI S. Cirurgia oncológica. Eds. **Oncologia em cães e gatos**. São Paulo: Roca, 2009.
40. DAMASCENO KA., BERTAGNOLLI AC., ESTRELA-LIMA A., RABELO BS., CAMPOS, LC., RIBEIRO LGR., CASSALI GD. Versican expression in myoepithelial cells from carcinomas in canine mixed mammary tumors. **Vet. J.**, 2014, 200, 146-51.
41. DAMASCENO KA., BERTAGNOLLI AC., ESTRELA-LIMA A., RIBEIRO LGR.; RABELO BS., CAMPOS CB., BARROS ALB., CASSALI GD. Versican expression in canine carcinomas in benign mixed tumors: is there an association with clinical pathological factors, invasion and overall survival? **BMC Vet. Res.**, 2012, 8, 195.
42. DE NARDI AB., DALECK CR., LAUFER-AMORIM R., RODASKI S., PIEKARZ CH., MAGALHAES GM., CALAZANS SG., FERNANDES SC., CESAR JRF., CASTRO JHT., SILVA MCV., MOTTA FR. Correlação da ciclooxigenase-2 com o prognóstico dos carcinomas mamários de cadelas. **Acta Scient. Vet.**, 2007, 35, 619-27.
43. DE NARDI AB., RODASKI S., SOUSA RS., COSTA TA., MACEDO TR., RODIGHERI SM., RIOS A., PIEKARZ CH. Prevalência de neoplasias modalidade de tratamentos em cães, atendidos no Hospital Veterinário da Universidade Federal do Paraná. **Arch. Vet. Sci.**, 2002, 7, 15-26.
44. DESTEXHE E., LESPAGNARD L., DEGEYTER M., HEYMAN R., COIGNOUL F. Immunohistochemical identification of myoepithelial, epithelial, and connective tissue cells in canine mammary tumors. **Vet. Pathol.**, 1993, 30, 146- 54.
45. DI COSTANZO D., ROSEN PP., GAREEN I., FRANKLIN S., LESSER M. Prognosis in infiltrating lobular carcinoma. An analysis of classical and variant tumors. **Am. J. Surg. Pathol.**, 1990, 14, 12-23.
46. DORÉ M., LANTHIER I., SIROIS J. Cyclooxygenase-2 expression in canine mammary tumors. **Vet. Pathol.**, 2003, 40, 207-12.
47. DUTRA AP., AZEVEDO JUNIOR GM., SCHMITT FC., CASSALI GD. Assessment of cell proliferation and prognostic factors in canine mammary gland tumors. **Arq. Bras. Med. Vet. Zootec.**, 2008, 60, 1403-12.
48. DUTRA AP., GRANJA NVM., SCHMITT FC., CASSALI GD. C-erbB-2 expression and nuclear pleomorphism in canine mammary tumors. **Braz. J. Med. Biol. Res.**, 2004, 37, 1673-81.
49. EL-GOHARY YM., METWALLY G., SAAD RS., ROBINSON MJ., MESKO T., POPPITI RJ. Prognostic significance of intratumoral and peritumoral lymphatic density and blood vessel density in invasive breast carcinomas. **Am. J. Clin. Pathol.**, 2008, 129, 578-86.
50. ELSTON CW., ELLIS IO. Assessment of histological grade. ELSTON CW., ELLIS IO. Eds. **Systemic Pathology. The breast**. London: Churchill Livingstone, 1998, 365-84.
51. ELSTON CW., ELLIS IO. Pathological prognostic factors in breast cancer. I. The value of histological grade in breast cancer: experience from a large study with long-term follow-up. **Histopathol.**, 1991, 19, 403-10.
52. ERDELYI I., VAN ASTEN AJ., VAN DIJK JE., NEDERBRAGT H. Expression of versican in relation to chondrogenesis-related extracellular matrix components in canine mammary tumors. **Histochem. Cell Biol.**, 2005, 124, 139-49.
53. ESPINOSA DE LOS MONTEROS A., HELLMÉN E., RAMÍREZ GA., HERRÁEZ P., RODRÍGUEZ F., ORDÁS J., MILLÁN Y., LARA A., MARTÍN DE LAS MULAS J. Lipid-rich carcinomas of the mammary gland in seven dogs: clinicopathologic and immunohistochemical features. **Vet. Pathol.**, 2003, 40, 718-23.
54. ESPINOSA DE LOS MONTEROS A., MILLÁN MY., ORDÁS J., CARRASCO L., REYMUNDO C., MARTÍN DE LAS MULAS J. Immunolocalization of the smooth muscle-specific protein calponin in complex and mixed tumors of the mammary gland of the dog: assessment of the morphogenetic role of the myoepithelium. **Vet. Pathol.**, 2002, 39, 247-56.
55. ESPINOSA DE LOS MONTEROS A., MILLÁN MY., RAMÍREZ GA., ORDÁS J., REYMUENDO C., MARTÍN DE LAS MULAS J. Expression of maspin in mammary gland tumors of the dog. **Vet. Pathol.**, 2005, 42, 250-57.
56. ESTRELA-LIMA A., ARAUJO MSS., COSTA-NETO JM., TEIXEIRA-CARVALHO A., BARROIN-MELO SM., CARDOSO SV., MARTINS-FILHO OA., SERAKIDES R., CASSALI GD. Immunophenotypic features of tumor infiltrating lymphocytes from mammary carcinomas in female dogs associated with prognostic factors and survival rates. **BMC Cancer**, 2010, 10, 1-14.
57. EVANS HL., AYALA AG., ROMSDAHL MM. Prognostic factors in chondrosarcoma of bone: a

- clinicopathologic analysis with emphasis on histologic grading. **Cancer**, 1977, 40, 818-31.
58. FERGUSON HR., Canine mammary gland tumors. **Vet. Clin. North. Am. Small. Anim. Pract.**, 1985, 15, 501-11.
59. FERREIRA E., GOBBI H., SARAIVA BS., CASSALI GD. Histological and immunohistochemical identification of atypical ductal mammary hyperplasia as a preneoplastic marker in dogs. **Vet. Pathol.**, 2012, 49, 322-9.
60. FERREIRA E. **Análise histomorfológica, imuno-histoquímica e de hibridização cromogênica in situ em lesões mamárias epiteliais ductais não neoplásicas de cadelas.** (2010). (Doutorado) - Patologia, Universidade Federal de Minas Gerais, Belo Horizonte, 2010.
61. FERREIRA E., BERTAGNOLLI AC., CAVALCANTI MF., SCHMITT FC., CASSALI GD. The relationship between tumor size and expression of prognostic markers in benign and malignant canine mammary tumors. **Vet. Comp. Oncol.**, 2009, 193, 1-6.
62. FERREIRA E., BREGUNCI GC., SCHMITT FC., CASSALI GD. Protocol for the anatomopathological examination of canine mammary tumors. **Arq. Bras. Med. Vet. Zootec.**, 2003, 55, 105- 09.
63. FERREIRA E., GOBBI H., SARAIVA B., CASSALI G. Columnar cell lesions of the canine mammary gland: pathological features and immunophenotypic analysis. **BMC Cancer**, 2010, 10, 1-7.
64. FONSECA CS., DALECK CR. Neoplasias mamárias em cadelas: influência hormonal e efeitos da ovari-histerectomia como terapia adjuvante. **Ciênc. Rural**, 2000, 30, 731-35.
65. GAMA A., ALVES A., GARTNER F., SCHMITT F. P63: a novel myoepithelial cell marker in canine mammary tissues. **Vet. Pathol.**, 2003, 40, 412- 20.
66. GAMA A., ALVES A., SCHMITT FC. Clinicopathologic features of mammary invasive micropapillary carcinoma (IMC) in dogs. **Vet. Pathol.**, 2008a, 45, 600-01.
67. GAMA A., PAREDES J., GÄRTNER F., ALVES A., SCHMITT F. Expression of E-cadherin, P-cadherin and β -catenin in canine malignant mammary tumors in relation to clinicopathological parameters, proliferation and survival. **Vet. J.**, 2008b, 177, 45-53.
68. GAMBA CO., DIAS EJ., RIBEIRO LGR., CAMPOS LC., ESTRELA-LIMA A., FERREIRA E., CASSALI GD. . Histopathological and immunohistochemical assessment of invasive micropapillary mammary carcinoma in dogs: A retrospective study. **Vet. J.**, 2013, 196, 241-6.
69. GERALDES M., GÄRTNER F., SCHMITT F. An immunohistochemical study of hormonal receptors and cell proliferation in normal canine mammary glands and spontaneous mammary tumors. **Vet. Rec.**, 2000, 146, 403-06.
70. GILBERTSON SR., KURZMAN ID., ZACHRAU RE., HURVITZ AI., BLACK MM. Canine mammary epithelial neoplasias: biologic implications of morphologic characteristics assessed in 232 dogs. **Vet. Pathol.**, 1983, 20, 127-42.
71. GILSON SD. Clinical management of the regional lymph node. **Vet. Clin. North Am. Small Anim. Pract.**, 1995, 25, 149-67.
72. GOLDHIRSCH A., GLICK JH., GELBER RD., COATES AS., THURLIMANN B., SENN HJ., MEMBER P. Meeting highlights: international expert consensus on the primary therapy of early breast cancer 2005. **Ann. Oncol.**, 2005, 16, 1569- 83.
73. GOMES C., VOLL J., FERREIRA KCRS., FERREIRA RR., OLIVEIRA LO., CONTESINI EA., OLIVEIRA RT. Carcinoma inflamatório mamário canino. **Acta Scien. Vet.**, 2006, 34, 171-74.
74. GOYAL A., NEWCOMBE RG., CHHABRA A., MANSEL RE. ALMANAC Trialists Group. Factors affecting failed localization and false-negative rates of sentinel node biopsy in breast cancer - results of the ALMANAC validation phase. **Breast Cancer Res. Treat.**, 2006, 99, 203-8.
75. GRANDI F., COLODEL MM., MONTEIRO LN., LEÃO JRVP., ROCHA NS. Extramedullary hematopoiesis in a case of benign mixed mammary tumor: cytological and histopathological assessment. **BMC Vet. Res.**, 2010, 6, 45.
76. HAMMOND MEH., HAYES DF., DOWSETT MD., ALLRED C., HAGERTY KL., BADVE S., FITZGIBBONS PL., FRANCIS G., GOLDSTEIN NS., HAYES M., HICKS DG., LESTER S., LOVE R., MANGU PB., MCSHANE L., MILLER K., OSBORNE CK, PAIK S., PERLMUTTER J., RHODES A., SASANO H., SCHWARTZ JN., SWEEP FCG., TAUBE S., TORLAKOVIC EE., VALENSTEIN P., VIALE G., VISSCHER D., WHEELER T., WILLIAMS RB., WITTLIFF JL., WOLFF AC. American society of clinical oncology/college of american pathologists guideline recommendations for immunohistochemical testing of estrogen and progesterone receptors in breast cancer. **J. Clin. Oncol.**, 2010, 28, 2784-95.
77. HANBY AM., HUGHES TA. In situ and invasive lobular neoplasia of the breast. **Histopathol.**, 2008, 52, 58-66.
78. HELLER DA., CLIFFORD CA., GOLDSCHMIDT MH., HOLT DE., SHOFR FS., SMITH A., SORENMO KU. Cyclooxygenase-2 expression is associated with histologic tumor type in canine mammary carcinoma. **Vet. Pathol.**, 2005, 46, 776- 780.
79. HELLMÉN E., BERGSTRÖM R., HOLMBERG L., SPÅNGBERG IB., HANSSON K., LINDGREN A. Prognostic factors in canine mammary tumors: a multivariate study of 202 consecutive cases. **Vet. Pathol.**, 1993, 30, 20-27.
80. HORTA RS., LAVALLE GE., CUNHA RMC., MOURA LL., ARAÚJO RB., CASSALI GD. Influence

- of surgical technique on overall survival, disease free interval and new lesion development interval in dogs with mammary tumors. **Adv. Breast. Cancer. Res.**, 2014, 3, 38-46.
81. JAIYESIMI IA., BUZDAR AU., HORTOBAGYI G. Inflammatory breast cancer: a review. **J. Clin. Oncol.**, 1992, 10, 1014-24.
 82. KAMSTOCK DA., EHRHART EJ., GETZY DM., BACON NJ., RASSNICK KM., MOROFF SD., LIU SM., STRAW RC., MCKNIGHT CA., AMORIM RL., BIENZLE D., CASSALI GD., CULLEN JM., DENNIS MM., ESPLIN DG., FOSTER RA., GOLDSCHMIDT MH., GRUBER AD., HELLMER E., HOWERTH EW., LABELLE P., LENZ SD., LIPSCOMB TP., LOCKE E., MCGILL LD., MILLER MA., MOUSER PJ., O'TOOLE D., POOL RR., POWERS BE., RAMOS-VARA JA., ROCCABIANCA P., ROSS AD., SAILASUTA A., SARLI G., SCASE JT., SCHULMAN FY., SHOIEB AM., SINGH K., SLEDGE D., SMEDLEY RC., SMITH KC., SPANGLER WL., STEFICEK B., STROMBERG PC., VALLI VE., YAGER J., KIUPEL M. Recommended guidelines for submission, trimming, margin evaluation, and reporting of tumor biopsy specimens in veterinary surgical pathology. **Vet. Pathol.**, 2011, 48, 19-31.
 83. KANDEMIR NO., BARUT F., BEKTAS S., OZDAMAR SO. Can lymphatic vascular density be used in determining metastatic spreading potential of tumor in invasive ductal carcinomas? **Pathol. Oncol. Res.**, 2011, 18, 253-62.
 84. KARAYANNOPOULOU M., KALDRYMIDOU E., CONSTANTINIDIS TC., DESSIRIS A. Histological grading and prognosis in dogs with mammary carcinomas: application of a human grading method. **J. Comp. Pathol.**, 2005, 20, 1-7.
 85. KARAYANNOPOULOU M., KALDRYMIDOU E., CONSTANTINIDIS TC., DESSIRIS A. Adjuvant post-operative chemotherapy in bitches with mammary cancer. **J. Vet. Med. A. Physiol. Pathol. Clin. Med.**, 2001, 48, 85-96.
 86. KESHGEGIAN AA., CNAAN A. Proliferation markers in breast carcinoma: mitotic figure count, S-phase fraction, proliferating cell nuclear antigen, Ki-67 and KI-67. **Am. J. Clin. Pathol.**, 1995, 104, 42-49.
 87. KURZMAN ID., GILBERTSON SR. Prognostic factors in canine mammary tumors. **Semin. Vet. Med. Surg. (Small Animal)**, 1986, 1, 25-32.
 88. KUSEWITT DF., HAHN FF., MUGGENBURG BA. Ultrastructure of a spindle cell carcinoma in the mammary gland of a dog. **Vet. Pathol.**, 1992, 29, 179-81.
 89. LAGADIC M., ESTRADA M., CAMADRO JP., DURAND P., GOEBEL J. Tumeurs mammaires de la chienne: critères du pronostic histologique et intérêt d'un grading. **Rec. Méd. Vét.**, 1990, 166, 1035-42.
 90. LANGENBACH A., MCMANUS P., HENDRICK M., SHOFRER FS., SORENMO KU. Sensitivity and specificity of methods of assessing the regional lymph nodes for evidence of metastasis in dogs and cats with solid tumors. **J. Am. Vet. Med. Assoc.**, 2001, 218, 1424-8.
 91. LAUFER-AMORIM R., SOUZA CHM., BANDARRA EP., SANCHES OC., PIZA ET. Immunohistochemical study of estrogen and progesterone receptors and cell proliferative index in canine inflammatory mammary carcinoma: 9 cases. **Braz. J. Vet. Pathol.**, 2008, 1, 16-20.
 92. LAVALLE GE., BERTAGNOLLI AC., TAVARES WLF., CASSALI GD. Cox-2 expression in canine mammary carcinomas: correlation with angiogenesis and overall survival. **Vet. Pathol.**, 2009, 46, 1275-80.
 93. LAVALLE, GE., CAMPOS, CB., BERTAGNOLLI, AC., CASSALI, GD. Canine malignant mammary gland neoplasias with advanced clinical staging treated with carboplatin and cyclooxygenase inhibitors. **In Vivo**, 2012, 26, 375-9.
 94. LIPSCOMB TP. Prognostic studies of mammary and other neoplasia in veterinary medicine: a new paradigm. **Vet. J.**, 2012, 193, 1.
 95. LOSCO PE. Local and peripheral eosinophilia in a dog with anaplastic mammary carcinoma. **Vet. Pathol.**, 1986, 23, 536-38.
 96. LUNA-MORÉ S., GONZALEZ B., ACEDO C., RODRIGO I., LUNA C. Invasive micropapillary carcinoma of the breast. A new special type of invasive mammary carcinoma. **Pathol. Res. Pract.**, 1994, 190, 668-64.
 97. MACEWEN EG., HARVEY HJ., PATNAIK AK., JAY H., PATNAIK AK., MOONEY S., HAYES A., KURZMAN I., HARDY WDJ. Evaluation of effects of levamisole and surgery on canine mammary cancer. **J. Biol. Response Mod.**, 1985, 4, 418-26.
 98. MACEWEN EG., PATNAIK AK., HARVEY HJ., PANKO WB. Estrogen receptors in canine mammary tumors. **Cancer Res.**, 1982, 42, 2255-9.
 99. MARCONATO L., LORENZO RM., ABRAMO F., RATTO A., ZINI E. Adjuvant gemcitabine after surgical removal of aggressive malignant mammary tumors in dogs. **Vet. Comp. Oncol.**, 2008, 6, 90-101.
 100. MARINHO VFZ., METZE K., SANCHES FSF., ROCHA GFS., GOBBI H. Marcadores moleculares em câncer de mama preditivos de metástases axilares. **Rev. Assoc. Med. Bras.**, 2008, 53, 203-7.
 101. MARTIN PM., COTARD M., MIALOT JP., ANDRÉ F., RAYNAUD JP. Animal models for hormone-dependent human breast cancer. Relationship between steroid receptor profiles in canine and feline mammary tumors and survival rate. **Cancer Chemother. Pharmacol.**, 1984, 12, 13-7.
 102. MARTINS DC., PLIEGO CM., FERREIRA MLG., FERREIRA AMR. Utilização de marcadores prognósticos no estudo da proliferação celular em

- adenocarcinomas mamários. **Ciênc. Anim. Bras.**, 2008, 9, 125-7.
103. MATOS AJF., FAUSTINO AMR., LOPES C., RUTTEMAN GR., GÄRTNER F. Detection of lymph node micrometastases in malignant mammary tumors in dogs by cytokeratin immunostaining. **Vet. Rec.**, 2006, 158, 626-30.
104. MENDES TC., GUIM TN., DIAS MCF., BONEL-RAPOSO J., FERNANDES CG. Comparação entre os sistemas histomorfológico e de gradação histológica para classificação prognóstica de tumores mamários em cadelas. **Acta Scient. Vet.**, 2007, 35, 339-45.
105. MISDORP W. Tumors of the mammary gland. DJ M. Eds. **Tumors in domestic animals**. Ames: Blackwell, 2002, 575-606.
106. MISDORP W., COTCHIN E., HAMPE JF., JABARA AG., VON SANDERSLEBEN J. Canine malignant mammary tumors III. Special types of carcinomas, malignant mixed tumors. **Vet. Pathol.**, 1973, 10, 241-56.
107. MISDORP W., ELSE RW., HELLMÉN E., LIPSCOMB E. **Definitions and explanatory notes**. WHO histological classification of mammary tumors of the dog and cat. Washington: Armed Forces Institute of Pathology, 1999, 18-27.
108. MORRISON WB. Canine and feline mammary tumors. Eds. **Cancer in dogs and cats: medical and surgical management**. 1st ed. Philadelphia: Lippincott, Williams & Wilkins, 1998, 591-8.
109. MOUSER P., MILLER MA., ANTUOFERMO E., BADVE SS., MOHAMMED SI. Prevalence and classification of spontaneous mammary intraepithelial lesions in dogs without clinical mammary disease. **Vet. Pathol.**, 2010, 47, 265-74.
110. MURAKAMI A., KAWACHI K., SASAKI T., ISHIKAWA T., NAGASHIMA YOJI., NOZAWA A. Sebaceous carcinoma of the breast. **Pathol. Int.**, 2009, 59, 188-92.
111. NIETO A., PÉREZ-ALENZA MD., DEL CASTILLO N., TABANERA E., CASTAÑO M., PEÑA L. BRCA-1 expression in canine mammary dysplasias and tumors: relationship with prognostic variables. **J. Comp. Pathol.**, 2003, 128, 260-8.
112. OGILVE GK., MOORE AS. Mammary neoplasia. Eds. **Managing the veterinary cancer patient; a practice manual**. New Jersey: Veterinary learning systems co., 1996, 431-3.
113. OWEN LN. **TNM Classification of tumors in domestic animals**. Ed. Geneva: World Health Organization, 1980.
114. PAL SK., LAU SK., KRUPER L., NWOYE U., GARBEROGLIO C., GUPTA RK., PAZ B., VORA L., GUZMAN E., ARTINYAN A., SOMLO G. Papillary carcinoma of the breast: an overview. **Breast Cancer Res. Treat.**, 2010, 122, 637-45.
115. PATSIKAS MN., DESSIRIS A. The lymph drainage of the neoplastic mammary glands in the bitch: a lymphographic study. **Anat. Hist. Embry.**, 2006, 35, 228-34.
116. PEÑA LL., NIETO AI., PEREZ-ALENZA D., CUESTA P., CASTAÑO M. Immunohistochemical Detection of Ki-67 and PCNA in canine mammary tumors: Relationship to clinical and pathologic variables. **J. Vet. Diagn. Invest.**, 1998, 10, 237-46.
117. PEÑA L., PÉREZ-ALENZA MD., RODRIGUES-BERTOS A., NIETO A. Canine inflammatory mammary carcinoma: histopathology, immunohistochemistry and clinical implications of 21 cases. **Breast. Canc. Res. Treat.**, 2003, 78, 141-8.
118. PENG L., SUN Q., LIANG Z., ZHOU Y., MAO F., GUAN J. Pure mucinous carcinoma of the breast: a clinicopathologic analysis with 56 patients. **Chinese Med. Sci. J.**, 2010, 25, 115-8.
119. PEREZ-ALENZA MD., TABANERA E., PEÑA L. Inflammatory mammary carcinoma in dogs: 33 cases (1995-1999). **J. Am. Vet. Med. Assoc.**, 2001, 219, 1110-4.
120. PÉREZ-MARTINEZ C., GARCIA-IGLESIAS MJ., DURÁN NAVARRETE AJ., ESPINOSA-ALVAREZ J., GARCÍA FERNÁNDEZ RA., LORENZANA-ROBLES N., FERNÁNDEZ-PÉREZ S., GARCÍA-MARÍN JF. Histopathological and immunohistochemical characteristics of two canine lipid-rich mammary carcinomas. **J. Vet. Med. A. Physiol. Pathol. Clin. Med.**, 2005, 52, 61-6.
121. PEROU CM., SORLIE T., EISEN MB., VAN DE RIJN M., JEFFREY SS., REES CA., POLLACK JR., ROSS DT., JOHNSEN H., AKSLEN LA., FLUGE O., PERGAMENSCHIKOV A., WILLIAMS C., ZHU SX., LONNING PE., BORRESEN-DALE AL., BROWN PO., BOTSTEIN D. Molecular portraits of human breast tumors. **Nature**, 2000, 406, 747-52.
122. PINHEIRO LG., OLIVEIRA FILHO RS., VASQUES PH., FILGUEIRA PH., ARAGÃO DH., BARBOSA PM., BESERRA HE., CAVALCANTE RV. Hemosiderin: a new marker for sentinel lymph node identification. **Acta Cir. Bras.**, 2009, 24, 432-6.
123. PINHEIRO LGP., MORAES MO., SOARES AH., LOPES AJT., NAGUÉRE MASP., GONDIM FAL., BRANDÃO CB., NASCIMENTO DCH., SOARES JPH., MENESES E SILVA JM. Estudo Experimental de linfonodo sentinela na mama da cadela com azul patente e tecnécio Tc99. **Acta Cir. Bras.**, 2003, 18, 545-52.
124. POLTON, G. Mammary tumors in dogs. **Irish Vet. J.**, 2009, 62, 1, 50-6.
125. QUEIROGA F., LOPES C. Tumores mamários caninos, pesquisa de novos fatores prognósticos. **Rev. Port. Ciênc. Vet.**, 2002, 97, 119-27.
126. REIS-FILHO JS., LAKHANI SR. The diagnosis and management of pre-invasive breast disease: genetic alterations in pre-invasive lesions. **Breast Cancer Res.**, 2003, 5, 313-19.

127. RESSEL L., MILLANTA F., POLI A. Canine invasive lobular carcinoma of mammary gland: morphological and immunohistochemical characterization of three cases. **J. Comp. Pathol.**, 2010, 1-5.
128. RIBEIRO GM. **Carcinoma em tumor misto da mama da cadela: avaliação de aspectos morfológicos e perfil imunofenotípico.** 73f. (Mestrado) – Patologia, Universidade Federal de Minas Gerais, Belo Horizonte, 2010.
129. RIBEIRO LGR., DAMASCENO KA., COSTA NETO JM., D'ASSIS MJMH., SILVA NS., AGUIAR PHP., CASSALI GD., ESTRELA-LIMA A. Expressão da COX-2 nos carcinomas matrios de cadelas. **Vet. Foco**, 2009, 6, 134-9.
130. RIBEIRO, GM., ROCHA, RM., BERTAGNOLLI, AC., CASSALI, GD. Morphological aspects and immunophenotypic profiles of mammary carcinomas in benign-mixed tumors of female dogs. **Vet. Med. International**, 2012, 7.
131. RIVA GT., HART BL., FARVER TB., OBERBAUER AM., MESSAM LL., WILLITS N., HART LA. Neutering dogs: effects on joint disorders and cancers in Golden Retrievers. **Plos One**, 2013, 8, 10.
132. RODASKI S., DE NARDI AB. Fármacos naturais. Eds. **Quimioterapia Antineoplásica em Cães e Gatos.** São Paulo: Medvet., 2008, 96-109.
133. RODASKI S., DE NARDI AB., PIEKARZ CH. Quimioterapia antineoplásica. Eds. **Oncologia em cães e gatos.** São Paulo: Roca, 2009.
134. ROSEN PP. Eds. **Rosen's Breast Pathology.** Mucinous carcinoma. 3 Ed. Lippincott Williams & Wilkins, 2009: 515-35.
135. ROSEN PP. Eds. **Rosen's Breast Pathology.** Papillary carcinoma. 3 Ed. Lippincott Williams & Wilkins, 2009: 423-48.
136. ROSEN PP. Eds. **Rosen's Breast Pathology.** Secretory carcinoma. 3 Ed. Lippincott Williams & Wilkins, 2009: 563.
137. ROSEN PP., OBERMAN HA. Eds. **Tumors of the mammary gland. atlas of tumor pathology.** Fasc. 7. Invasive lobular carcinoma. Armed Forces Institute of Pathology, Washington DC. 1993:168-75.
138. SALGADO BS. MONTEIRO LN., COLODEL MM., FIGUEIROA FC., SOARES LM., NONOGAKI S., ROCHA RM., ROCHA NS. Clinical, cytologic, and histologic features of a mammary micropapillary carcinoma in a dog. **Vet. Clin. Pathol.**, 2013, 42, 382-5.
139. SCHNEIDER R., DORN CR., TAYLOR DON. Factors influencing canine mammary tumor development and postsurgical survival. **J. Natl. Cancer Inst.**, 1969, 43, 1249-1.
140. SCHOPPMANN SF., BIRNER P., STUDER P., BREITENEDER-GELEFF S. Lymphatic microvessel density and lymphovascular invasion assessed by anti-podoplanin immunostaining in human breast cancer. **Anticancer Res.**, 2001, 21, 2351-5.
141. SEIXAS F., PALMEIRA C., PIRES MA., LOPES C. Mammary invasive micropapillary carcinoma in cats: clinicopathologic features and nuclear DNA content. **Vet. Pathol.**, 2007, 44, 842-848.
142. SILVA AE., SERAKIDES R., CASSALI GD. Carcinogênese hormonal e neoplasias hormônio-dependentes. **Ciênc. Rural**, 2004, 34, 625-33.
143. SILVER SA., TAVASSOLI AF. Mammary ductal carcinoma *in situ* with microinvasion. **Am. Cancer Soc.**, 1998, 82, 2382-90.
144. SINGLETARY SE., PATEL-PAREKH L., BLAND KI. Treatment trends in early-stage invasive lobular carcinoma: a report from the National Cancer Data Base. **Ann. Surg.**, 2005, 242, 281-9.
145. SOBIN L., WITTEKIND C. **TNM classification of malignant tumors.** Eds. New York: Wiley-Liss, 1997.
146. SORENMO K. Canine mammary gland tumors. **Vet. Clin. North Am. Small Anim. Pract.**, 2003, 33, 573-96.
147. SORENMO KU., DEANNA RW., GOLDSMIDT RH. Tumors of the mammary gland. WITHROW SJ., VAIL DM. **Withrow & MacEwen's small animal clinical oncology.** 5^o Ed. Philadelphia: W. B. Saunders Company. 2013, 553-571.
148. SORENMO KU., RASOTTO R., ZAPPULLI V., GOLDSCHMIDT MH. Development, anatomy, histology, lymphatic drainage, clinical features, and cell differentiation markers of canine mammary gland neoplasias. **Vet. Pathol.**, 2011, 48-85.
149. SORLIE T., TIBSHIRANI R., PARKER J., HASTIE T., MARRON JS., NOBEL A., DENG S., JOHNSEN H., PESICH R., GEISLER S., DEMETER J., PEROU CM., LONNING PE., BROWN PO., DALE ALB., BOTSTEIN D. Repeated observation of breast tumor subtypes in independent gene expression data sets. **Proc. Natl. Acad. Sci. Unit. States Am.**, 2003, 100, 8418-23.
150. SOUZA CHM., TOLEDO-PIZA E., AMORIN R., BARBOZA A., TOBIAS KM. Inflammatory mammary carcinoma in 12 dogs: Clinical features, cyclooxygenase-2 expression, and response to piroxicam treatment. **Can. Vet. J.**, 2009, 50, 506-10.
151. SOUZA FW., BRUN MV., NARDI AB., HUPPES RR., RAPOSO TMM., KASPER PN., OLIVEIRA MT., GUEDES RL. Linfadenectomia laparoscópica em cadela com neoplasia mamária. **Ciênc. Rural**, 2013, 43, 750-3.
152. STERNLICHT MD., KEDESHIAN P., SHAO ZM., SAFARIANS S., BARSKY SH. The human myoepithelial cell is a natural tumor suppressor. **Clin. Cancer Res.**, 1997, 3, 1949-58.
153. STRATMANN N., FAILING K., RICHTER A., WEHREND A. Mammary tumor recurrence in bitches after regional mastectomy. **Vet. Surg.**, 2008, 37, 82-86.
154. SUSANECK SJ., ALLEN TA., HOOPES J., WITHROW SJ., MACY DW. Inflammatory mammary

- carcinoma in the dog. **J. Am. An. Hosp. Assoc.**, 1983, 19, 971-6.
155. SUZUKI F., SAITO A., ISHI K., OKAZAKI T., KINA K., KOYATSU J., SUGIYAMA K. Secretory carcinoma of the breast: an immunohistochemical and ultrastructural study. **Med. Electron. Microsc.**, 1999, 32, 50-6.
156. TAVARES WLF., FIGUEIREDO MS., SOUZA AG., BERTAGNOLLI AC., LAVALLE GE., CAVALCANTI G., CASSALI GD. Evaluation of dose and side effects of tamoxifen in female dogs. **V ONCOVET. Vet. Comp. Oncol.**, 2009, 7, 93-4.
157. TAVASSOLI FA., DEVILEE P. **Pathology and genetics of tumors of the breast and female genital organs**. 1 ed. Tumors of the breast. Lyon: IARC Press. 2003:09-112.
158. TERZIAN ACB., ZUCCARI DAPC., PEREIRA RS., PAVAM MV., COELHO J. Avaliação da caspase 3 e ki 67 como marcadores prognósticos nas neoplasias mamárias em cadelas. **Braz. J. Vet. Res. Anim. Sci.**, 2007, 44, 96-102.
159. TOKUDOME N., SAKAMOTO G., SAKAI T., SARUMARU S., OKUYAMA N., HORI F., HORII R., AKIYAMA F., TANABE M., SAITO K., TAKAHASHI K., KASUMI F. A Case of carcinosarcoma of the breast. **Breast Cancer**, 2005, 12, 149-53.
160. UENG S., MEZZETTI T., TAVASSOLI FA. Papillary neoplasias of the breast: a review. **Arch. Pathol. Lab. Med.**, 2009, 133, 893-907.
161. UVA P., AURISICCHIO L., WATTERS J., LOBODA A., KULKARNI A., CASTLE J., PALOMBO F., VITI V., MESITI G., ZAPPULLI V., MARCONATO L., ABRAMO F., CILIBERTO G., LAHM A., MONICA N., RINALDIS E. Comparative expression pathway analysis of human and canine mammary tumors. **BMC Genomics**, 2009, 10, 1-20.
162. VELDHUEN N., WATTERSON J., BRASH M., MILNER J. Identification of tumor-associated and germ line p53 mutations in canine mammary cancer. **Brit. J. Cancer**, 1999, 81, 409-415.
163. WAHED A., CONNELLY J., REESE T. E-cadherin expression in pleomorphic lobular carcinoma: an aid to differentiation from ductal carcinoma. **Ann. Diagn. Pathol.**, 2002, 6, 349-51.
164. WELLS S., BENNETT A., WALSH P., PEAUROI J. Clinical usefulness of intradermal fluorescein and patent blue violet dyes for sentinel lymph node identification in dogs. **Vet. Comp. Oncol.**, 4, 114-22, 2006.
165. WERNER PR., WERNER J. Avaliação histopatológica. DALECK CR. Ed. **Oncologia em cães e gatos**. São Paulo: Roca, 2009, 121-34.
166. WILLIAMS LE., PACKER RA. Association between lymph node size and metastasis in dogs with malignant melanoma: 100 cases (1987–2001). **J. Am. Vet. Med. Assoc.**, 2003, 222, 1234-1236.
167. WOLFF AC., HAMMOND MEH., SCHWARTZ JN., HAGERTY KL., ALLRED DC., COTE RJ., DOWSETT M., FITZGIBBONS PL., HANNA WM., LANGER A., MCSHANE LM., PAIK S., PEGRAM MD., PEREZ EA., PRESS MF., RHODES A., STURGEON CATHARINE., TAUBE SE., TUBBS R., VANCE GH., VIJVER MV., WHEELER TM., HAYES DF. American Society of Clinical Oncology/College of American Pathologists guideline recommendations for human epidermal growth factor receptor 2 testing in breast cancer. **J. Clin. Oncol.**, 2007, 25, 118-45.
168. YAMAGAMI T., KOBAYASHI T., TAKAHASHI K., SUGIYAMA M. Prognosis for canine malignant mammary tumors based on TNM and histologic classification. **J. Vet. Med. Sci.**, 1996, 58, 1079- 83.
169. YAZIJI H., GOWN AM., SNEIGE N. Detection of stromal invasion in breast cancer: the myoepithelial markers. **Adv. Anat. Pathol.**, 2000, 7, 100-109.
170. ZUCCARI DAPC., PAVAM MV., TERZIAN ACB., PEREIRA RS., RUIZ CM., ANDRADE JCA. Immunohistochemical Evaluation of e-cadherin, Ki-67 and PCNA in Canine Mammary Neoplasia: Correlation of Prognostic Factors and Clinical Outcome. **Pesq. Vet. Bras.**, 2008, 28, 207-15.
171. ZUCCARI DAPC., SANTANA AE., CURY PM., CORDEIRO JA., ZANCHETTA NETTO D. Immunocytochemical study of Ki-67 as a prognostic marker in canine mammary neoplasia. **Vet. Clin. Pathol.**, 2004, 33, 23-28.
172. ZUCCARI DAPC., SANTANA AE., ROCHA NS. Correlação entre a citologia aspirativa por agulha fina e a histologia no diagnóstico de tumores mamários de cadelas. **Braz. J. Vet. Res. Anim. Sci.**, 2001, 38, 38-41.