



## Case Report

# Gastric *Braunina cordiformis* and a review of helminth parasitism in the finless porpoise (*Neophocaena phocaenoides*)

Eric Lombardini<sup>1\*</sup>, Thanida Haetrakul<sup>2</sup>, Sui H. Kuit<sup>3,4</sup>, Nantarika Chansue<sup>2</sup>

<sup>1</sup>Armed Forces Research Institute of Medical Sciences (AFRIMS), Bangkok, 10400, Thailand.

<sup>2</sup>Ornamental Aquatic Animals and Aquatic Animals for Conservation Research Unit, Faculty of Veterinary Science, Chulalongkorn University, Patumwan, Bangkok, 10330, Thailand.

<sup>3</sup>The MareCet Research Organization, Shah Alam, Selangor, Malaysia.

<sup>4</sup>Institute of Biological Sciences, University of Malaya, Kuala Lumpur, Malaysia

\*Corresponding Author: eric.d.lombardini.mil@mail.mil

Submitted August, 14<sup>th</sup> 2018, Accepted November, 21<sup>st</sup> 2018

## Abstract

A pregnant adult female finless porpoise (*Neophocaena phocaenoides*) stranded off the coast of Phuket, Thailand and died during attempted rehabilitation. The cadaver was frozen for use in a Marine mammal stranding training event. During necropsy, the animal was observed to have approximately 60% of the gastric mucosa embedded with exophytic, heart shaped digenean trematodes interpreted to be *Braunina cordiformis*. Tissue samples were collected from the stomach to include the embedded parasites and these were evaluated histopathologically, confirming the diagnosis. This is the first report of *Braunina cordiformis* trematodes in Asian waters and the first report of the parasite in a finless porpoise.

**Key words:** *Braunina cordiformis*, digenean trematode, finless porpoise, South-East Asia.

## Introduction

There are only rare reports of pathology in finless porpoises, and none describing disease in the populations of the species in the coastal waters of South East Asia. This case report describes a novel parasite-host interaction observed during post mortem in a pregnant, adult female finless porpoise which stranded off the coast of Thailand.

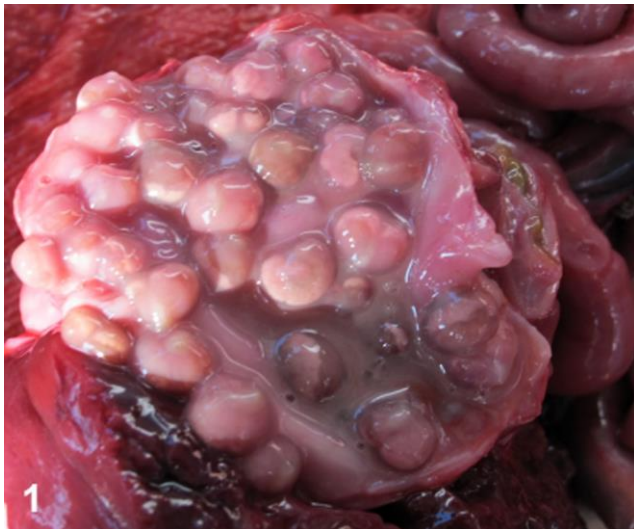The digenean trematode, *Braunina cordiformis*, has been reported in a handful of cetacean species to include Atlantic bottlenose dolphins (*Tursiops truncatus*), Commerson's dolphins (*Cephalorhynchus commersonii*), dusky dolphins (*Lagenorhynchus obscurus*) and common dolphins (*Delphinus delphis*) in Patagonia and Tierra del Fuego (1, 2, 3, 14), tucuxi dolphins (*Sotalia guianensis*) in Brazil (11), black dolphins (*Cephalorhynchus eutropia*) in Chile (18), Guiana dolphin (*Sotalia guianensis*) (11), rough toothed dolphin (*Steno bredanensis*) (15), Risso's dolphins (*Grampus griseus*), a Striped dolphin (*Stenella coeruleoalba*) and Atlantic Bottlenose dolphins in the

Adriatic sea (5) and Indo-Pacific bottlenose dolphin (*Tursiops aduncus*) in South Africa (15, 16). The parasite has also been reported in Atlantic bottlenose dolphins off the coast of the United States (6, 10, 16). The parasite typically attaches to the wall of the duodenal ampoule, however it has been reported to occur in both the fundic and pyloric compartments of the stomach (5, 16).

## Case report

A pregnant, adult female, finless porpoise (*Neophocaena phocaenoides*) was found stranded but alive off the coast of Phuket, Thailand. Unfortunately, the animal and her fetus died during attempted rehabilitation. The cadaver had been frozen for use in a training event specific to marine mammal medicine and pathology. During a demonstration of necropsy technique, the gastric parasitism in the mother was observed, described and sampled. In this case, the trematodes were firmly embedded into the gastric epithelium, and while they were

predominantly located in the pyloric stomach, the parasites also extended into the pylorus and obscured the ampulla of the duodenum. The trematodes presented as coalescing, botryoid masses of exophytic individual parasites (Fig. 1). The parasites were approximately 5-8 mm in diameter, heart shaped and pale brown with a white dividing line. These were attached to the gastric mucosa by a short stalk while the bulk of the parasite was free within the gastric lumen.



**Figure 1.** Embedded in the gastric mucosa of an adult female finless porpoise are myriad heart shaped digenean trematodes.

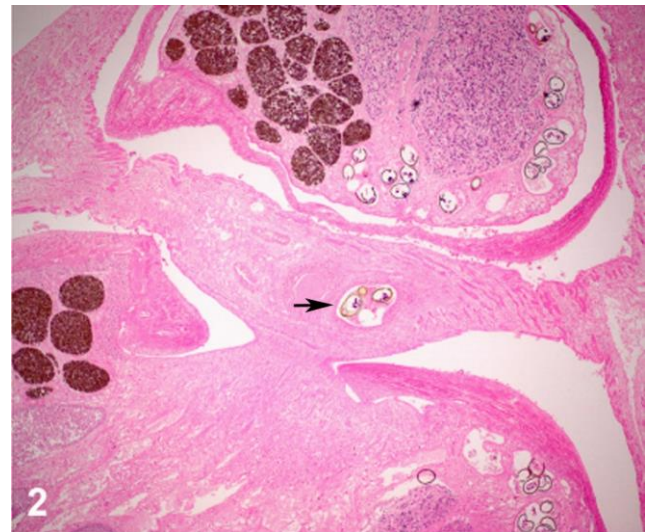
At necropsy, all organs were examined, and samples from all tissues were collected and fixed in 10% neutral-buffered formalin. Representative sections of all tissues were embedded in paraffin, sectioned at 6 µm, and stained with hematoxylin and eosin. Unfortunately, freezing artifacts were observed at histopathological examination.

Microscopically, the gastric mucosa was multifocally eroded adjacent to the attachment points of the trematodes' stalk-like suckers. Underlying the eroded mucosa was a deposition of fibrosis admixed with moderate numbers of eosinophils, lymphocytes and histiocytes as well as rare neutrophils.

The parasites themselves were comprised of a spongy parenchyma bounded by a tegument and containing innumerable vitellaria or vitelline glands, occasional dark testicular tissue and within sections of uterus in the trematodes are high numbers of irregularly oval eggs which measure approximately 100 x 50 µm, have a 2-3 µm thick yellow-brown shell, and contain a multinucleated miracidium. Rarely cecae were observed in section (Fig. 2).

*B. cordiformis* lesions in Risso's dolphins, Atlantic bottlenose dolphins and a striped dolphin from the Adriatic were found to have focal mechanical injury to the gastric mucosa, but lacked an inflammatory response (5).

Our findings are more consistent with those described in Atlantic bottlenose dolphins off of the coastal United States, in which *B. cordiformis* infection was associated with extensive gastric fibrosis combined with an inflammatory response predominated by eosinophils and neutrophils concentrated on the point of attachment (10).



**Figure 2.** Microscopically, individual trematodes are comprised of spongy parenchyma containing reproductive tissue, vitelline glands and high numbers of ova (arrow). (Hematoxylin and Eosin, 40X).

## Discussion

The finless porpoise (*Neophocaena phocaenoides*), also known as the Indian porpoise, is primarily found within coastal areas of the Indian Ocean, extending from the Persian Gulf to the shores of Myanmar, Thailand, Malaysia and Indonesia. The genus *Neophocaena* includes at least two species: *N. asiaeorientalis* in East Asia and *N. phocaenoides* in the Indian Ocean (9). The *N. asiaeorientalis* is described as comprising at least two subspecies which are known as the East Asian and the narrow-ridged finless porpoise or Yangtze finless porpoise. The pathology of *N. asiaeorientalis* had been described from populations sampled in both Japanese waters and in waters off the coast of China (17, 19). The helminthology of that species (sub-species) has been described from those studies and a range of parasites were identified, to include the respiratory tract nematodes *Pharurus sunameri*, *P. asiaeorientalis*, *Stenurus nanjingensis*, *Halocercus pingi*, *H. sunameri* and *H. taurica*. The acanthocephalid, *Corynosoma* sp. was identified in sections of intestine, as were *Diphyllobothrium fuhrmanni* and *Tetrabothrius* sp. cestodes. The trematodes that were reported were comprised of *Nasitrema spathulatum*, *N. sunameri*, *Campula oblonga* and *Synthesium elongatum* (17, 19). *Braunina cordiformis* was not observed. An additional study conducted a thorough investigation of stranded East

Asian finless porpoises in the waters surrounding Hong Kong and identified verminous pneumonia secondary to the *H. pingi* lungworm in 10 out of 32 animals examined (12).

Beyond these three studies, there are only scant reports of pathology in finless porpoises (12, 13) and even less describing the parasitism of the species and vanishingly rare reports on the pathology of any kind in *N. phocaenoides*. A single report describes a trematode, *Synthesium tursionis*, in the intestine of a stranded Indian porpoise discovered in Goa, adjacent to the mouth of the Zoari river (4). Mortality of the East Asian species has been described as being primarily associated with natural causes such as the previously described verminous pneumonia which has been reported to reach such concentrations of the parasites as to obstruct the airways. Other causes include shark predation, three cases of reproductive pathology (one vaginal tumor and two cases of uterine prolapse). Human interaction results for the remainder of reported causes, comprised of boat strikes and entanglement in fish nets (7, 8, 12). No such study exists for mortality of the Indian porpoise.

This study is the first report of *Braunina cordiformis* trematodes in Asian waters and the first report of the digenean parasite in a finless porpoise.

## References

1. Berón-Vera B, Crespo EA, Raga JA, Fernández M. Parasite communities of common dolphins (*Delphinus delphis*) from Patagonia: the relation with host distribution and diet and comparison with sympatric hosts. *J Parasitol.* 2007;93(5):1056-60.
2. Berón-Vera B, Pedraza SN, Raga JA, Gil de Pertierra A, Crespo EA, Alonso MK, Goodall RNP. Gastrointestinal helminths of Commerson's dolphins *Cephalorhynchus commersonii* from central Patagonia and Tierra del Fuego. *Dis Aquat Organ.* 2001;47(3):201-8.
3. Dans SL, Reyes LM, Pedraza SN, Raga JA, Crespo EA. Gastrointestinal helminths of the dusky dolphin, *Lagenorhynchus obscurus*, off Patagonian coasts, in the Southwestern Atlantic ocean. *Mar Mammal Sci.* 1999;15:649-60.
4. Hafeezullah M. On a trematode (Digenea: Campulidae) of a marine Mammal from Arabian Sea. *Rec Zool Surv India.* 1986;83(1):41-8.
5. Hrabar J, Bočina I, Gudan Kurilj A, Đuras M, Mladineo I. Gastric lesions in dolphins stranded along the Eastern Adriatic coast. *Dis Aquat Organ.* 2017;125(2):125-39.
6. Inskeep W, Gardiner CH, Harris RK, Dubey JP, Goldston RT. Toxoplasmosis in Atlantic bottle-nosed dolphins (*Tursiops truncatus*). *J Wildl Dis.* 1990;26(3):377-82.
7. Jefferson TA, Braulik GT. Preliminary report on the ecology of the finless porpoise in Hong Kong waters. *IBI Reports.* 1999;9:41-54.
8. Jefferson TA, Curry BE, Kinoshita R. Mortality and morbidity of Hong Kong finless porpoises, with emphasis on the role of environmental contaminants. *Raffles Bulletin of Zoology.* 2002;10:161-71.
9. Jefferson, TA, Wang JY. Revision of the taxonomy of finless porpoises (genus *Neophocaena*): the existence of two species. *J Mar Anim Ecol.* 2011;4:3-16.
10. Johnson DG, Ridgway SH. Parasitism in some Marine Mammals. *J Am Vet Med Assoc.* 1969;155:1064-72.
11. Marigo J, Ruoppolo V, Rosas FC, Valente AL, Oliveira MR, Dias RA, Catão-Dias JL. Helminths of *Sotalia guianensis* (Cetacea: Delphinidae) from the south and southeastern coasts of Brazil. *J Wildl Dis.* 2010;46(2):599-602.
12. Parsons EC, Jefferson TA. Post-mortem investigations on stranded dolphins and porpoises from Hong Kong waters. *J Wildl Dis.* 2000;36(2):342-56.
13. Ozaki Y. Trematode parasites of Indian porpoise *Neophocaena phocaenoides* Gray. *J Sci Hiroshima Univ.* 1935;3:115-38.
14. Romero MA, Fernández M, Dans SL, García NA, González R, Crespo EA. Gastrointestinal parasites of bottlenose dolphins *Tursiops truncatus* from the extreme Southwestern Atlantic, with notes on diet composition. *Dis Aquat Organ.* 2014;108(1):61-70.
15. Santos CP, Rohde K, Ramos R, di Benedetto AP, Capistrano L. Helminths of cetaceans on the southern coast of Brazil. *J Helminthol Soc Wash.* 1996;63:149-52.
16. Schryver HF, Medway W, Williams JF. The stomach fluke *Braunina cordiformis* in the Atlantic bottlenose dolphin. *J Am Vet Med Assoc.* 1967;151(7):884-6.
17. Shiozaki A, Amano M. Population- and growth-related differences in helminthic fauna of finless porpoises (*Neophocaena asiaeorientalis*) in five Japanese populations. *J Vet Med Sci.* 2017;79(3):534-41.
18. Torres P, Oporto JA, Brieva LM, Escare L. Gastrointestinal helminths of the cetaceans *Phocoena spinipinnis* (Burmeister, 1865) and *Cephalorhynchus eutropia* (Gray, 1846) from the southern coast of Chile. *J Wildl Dis.* 1992;28(2):313-5.
19. Wan XL, Zheng JS, Li WX, Zeng XY, Yang JW, Hao YJ, Wang D. Parasitic infections in the East Asian finless porpoise *Neophocaena asiaeorientalis* sunameri living off the Chinese Yellow/Bohai Sea coast. *Dis Aquat Organ.* 2017;125:63-71.