



Diagnostic Exercise
From The Latin Comparative Pathology Group*

Vitamin A deficiency in peafowl with secondary visceral urate deposition

Erin Edwards¹ and Laura Rice¹.

¹ Texas A&M Veterinary Medical Diagnostic Laboratory (TVMDL), College Station, TX 77843.

**Corresponding author: E-mail: erin.edwards@tvmdl.tamu.edu

Clinical History:

In a flock of approximately 180 peafowl, several were showing signs of a possible upper respiratory infection and had mouth gaping per the owner. They were also reported to be lethargic, to have excessive phlegm or mucus in the mouths, had trouble swallowing, and were losing weight. They were being treated with Baytril and Metronidazole with no improvement. Approximately eight had died. Five peafowl were submitted for necropsy and diagnostic work-up, including three peahens and two peacocks.

Necropsy and Microscopic Findings:

In all five peafowl, the oral cavity contained excess mucus. The oral, crop, and esophageal mucosa had disseminated, smooth, raised, round nodules with a central pore. The proximal esophagus was the most severely affected site. The nodules measured on average ~2 mm in diameter. Upon squeezing some of these nodules, pale tan, caseous material could be expressed. In all five peafowl, the heart was diffusely coated by abundant white, chalky, urate material. Similar though lesser amounts of urates partially coated the surface of the liver and other coelomic membranes. In one peahen, the ureters were multifocally distended and contained consolidated accumulations of tan to pale yellow, caseous material. The kidneys in this bird were pale.

Follow-up Questions:

- *Morphologic diagnoses*
- *Cause*
- *Pathogenesis*

**The Diagnostic Exercises are an initiative of the Latin Comparative Pathology Group (LCPG), the Latin American subdivision of The Davis-Thompson Foundation and published in cooperation with the Brazilian Journal of Veterinary Pathology. These exercises are contributed by members and non-members from any country of residence.*

Consider submitting an exercise! A final document containing this material with answers and a brief discussion will be posted on the CL Davis website:

<https://davisthompsonfoundation.org/diagnostic-exercise/>

Editor-in-chief for this Diagnostic Exercise: Claudio Barros
Associate Editor for this Diagnostic Exercise: Raquel R. Rech



Gross and Microscopic Images:

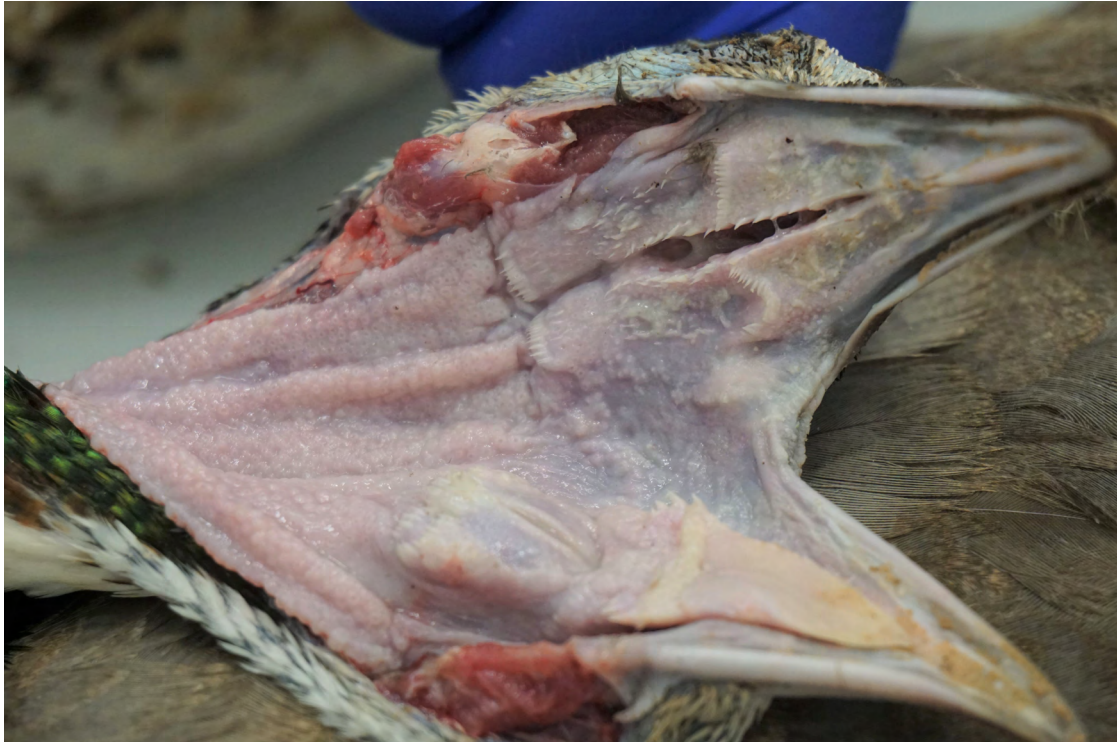

Figure 1. The esophageal mucosa contains numerous smooth nodules with pores. Fewer nodules also affect mucosa of the oropharynx and the base of the tongue.

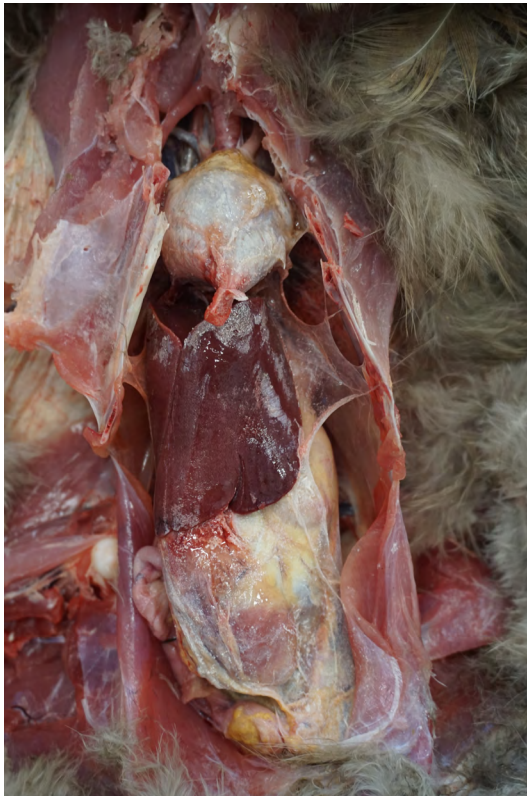

Figure 2. Abundant white, chalky material (urates) coats the heart and fills the pericardium. There are thinner layers of similar material over the coelomic membranes covering the liver, ventriculus, and intestines.

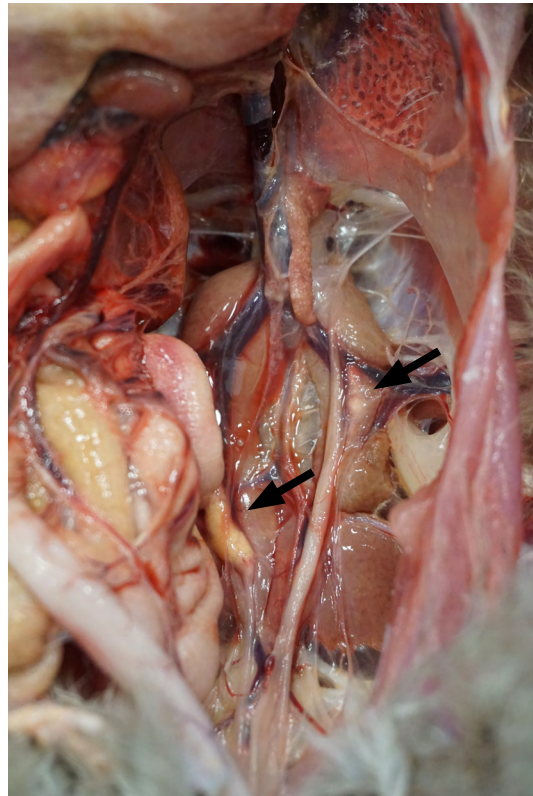

Figure 3. The ureters contain two accumulations of tan to pale yellow, caseous material (arrows). The kidneys are pale.

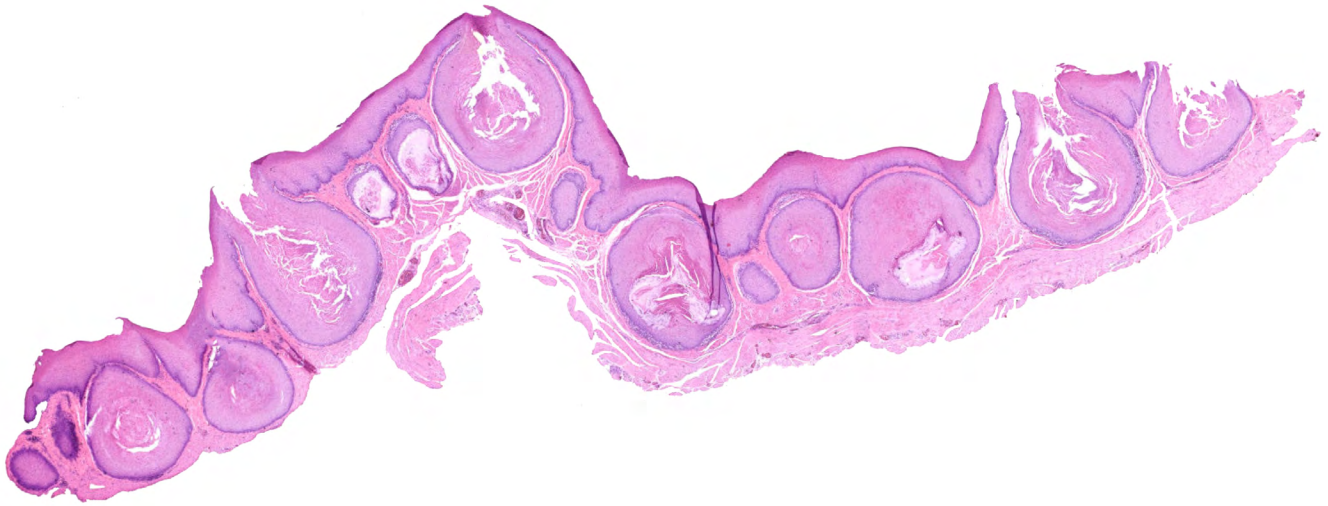

Figure 4. Mucous glands throughout the esophagus are enlarged and filled with abundant squamous cells and keratin. Some have a pore that opens through the mucosal surface.

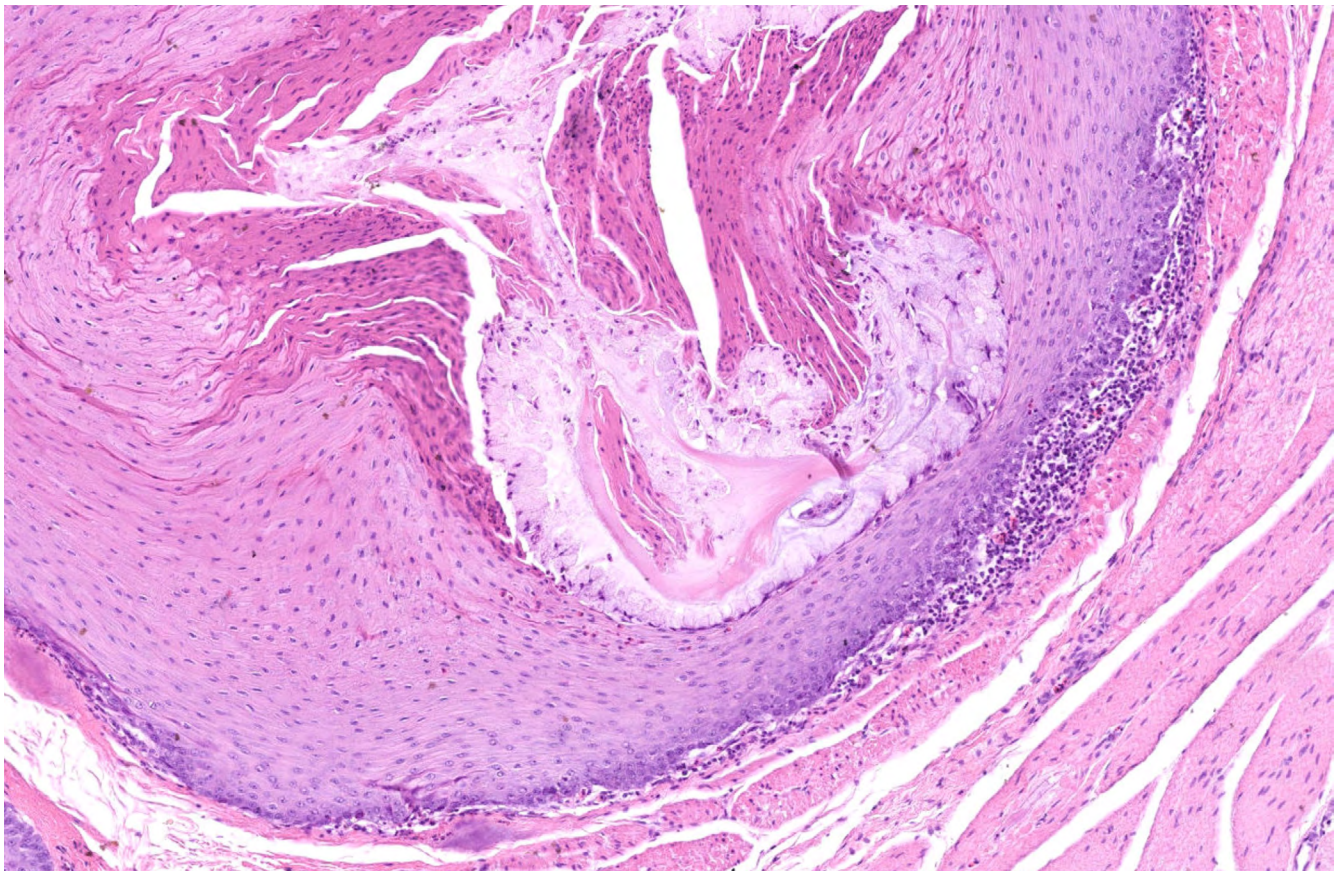


Figure 5. Higher magnification of a gland with remnant mucoïd differentiation. The majority of the gland has been replaced by squamous metaplasia with production of keratin. Small amounts of lymphocytes and plasma cells surround the gland.

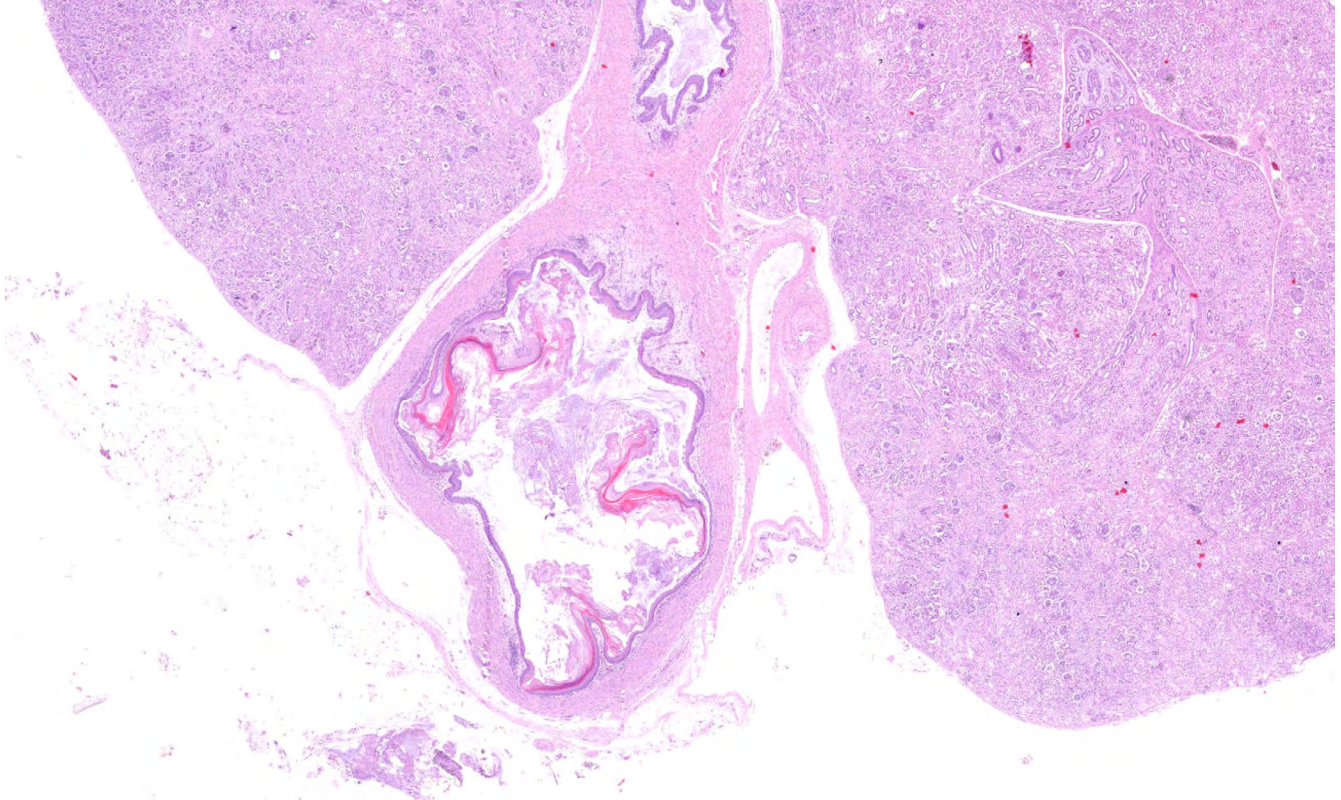


Figure 6. Distension of the ureter with accumulation of keratin.

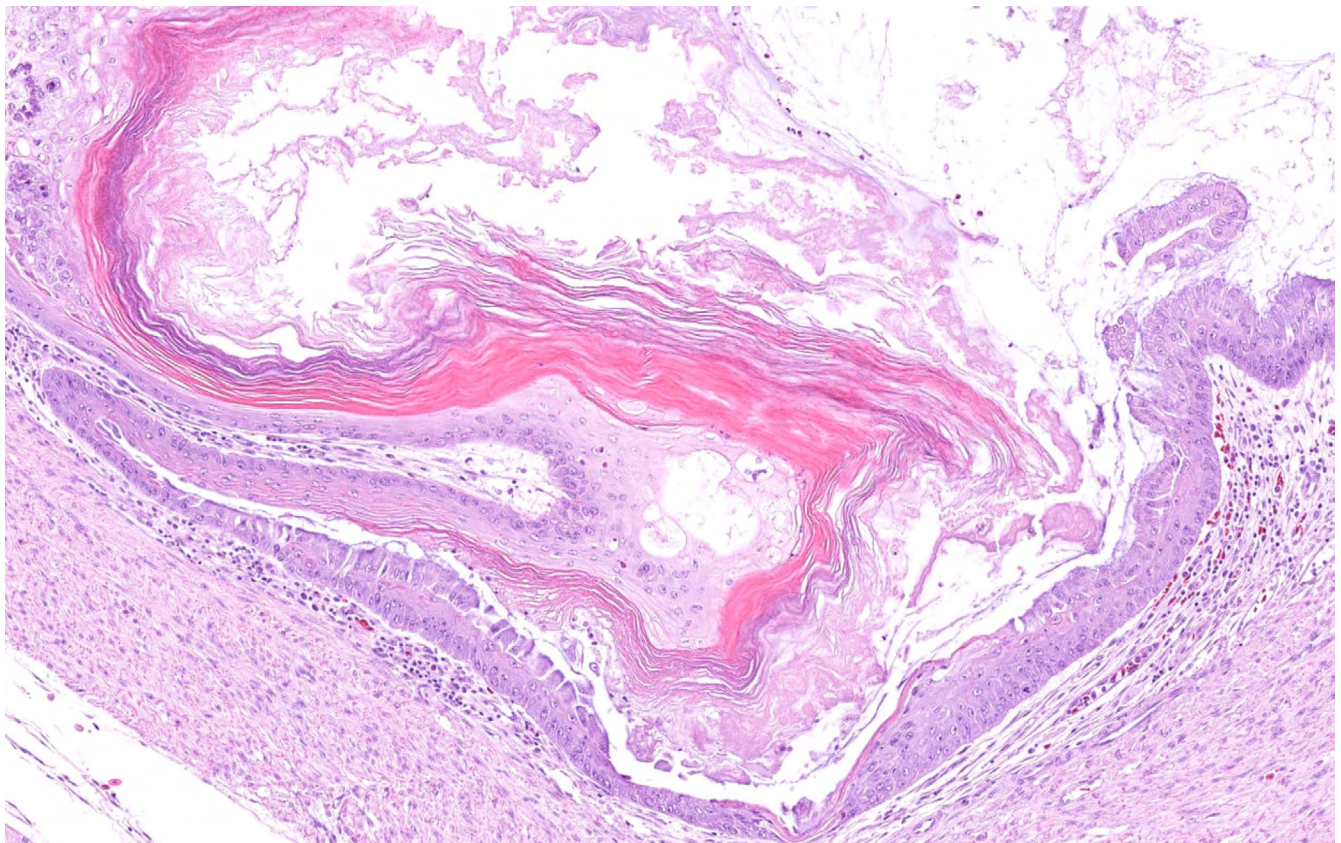


Figure 7. Higher magnification of the ureter. There is squamous metaplasia of the epithelial cells lining the ureter with production of keratin.

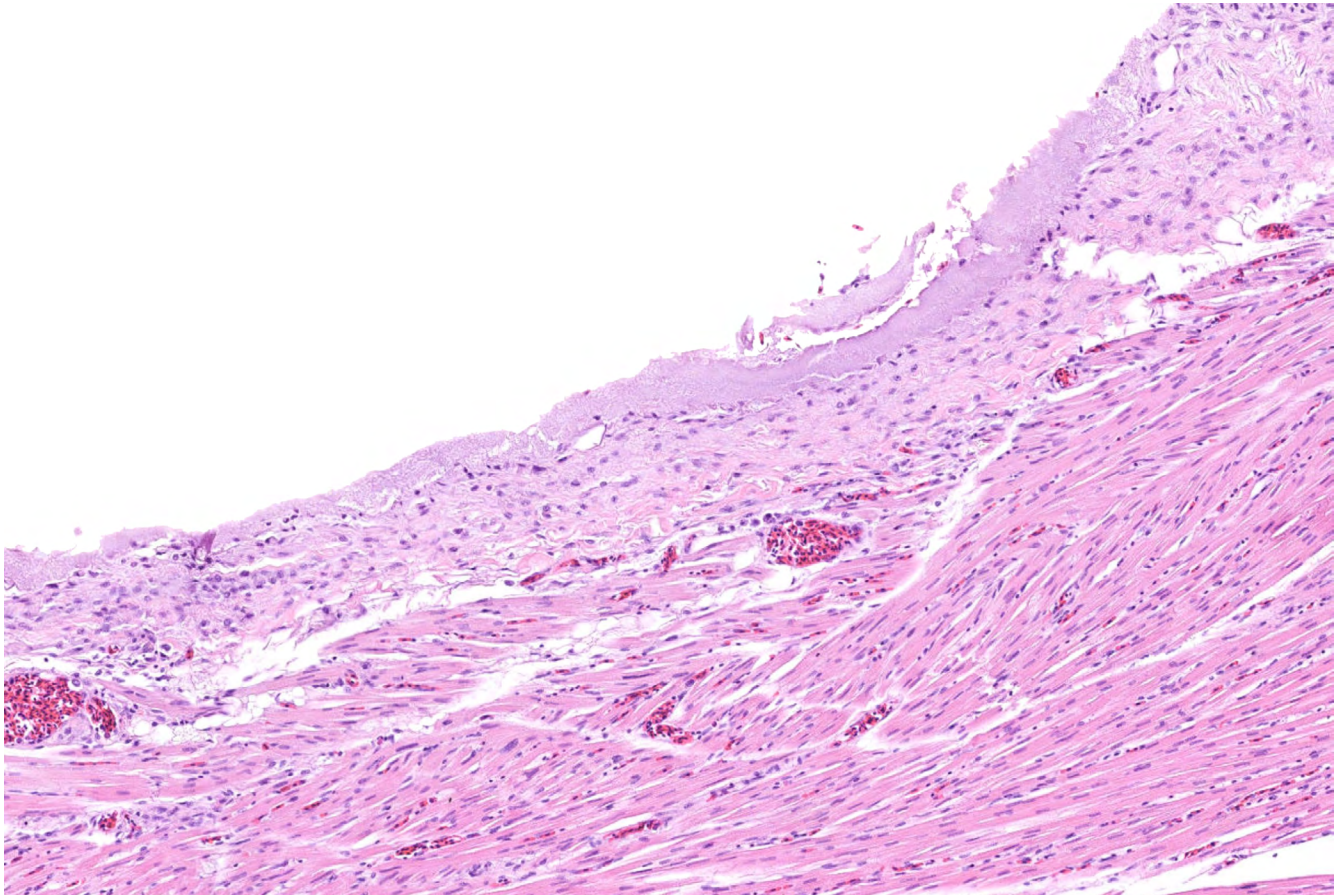


Figure 8. A layer of lightly basophilic, amorphous, urate material lines the epicardium.

Histological Description:

Esophagus: Esophageal mucous glands are enlarged and distended (Fig. 4). Affected glands bulge and occasionally have a visible pore that opens through the mucosal surface. The gland lumens are full of keratin and squamous epithelial cells. Some glands have complete squamous metaplasia with no goblet cells remaining, while in other areas there are small regions of remnant cuboidal to columnar epithelium with goblet cell differentiation and production of little mucus (Fig. 5). Small amounts of lymphocytes and plasma cells multifocally surround the distended glands.

Kidney: The ureter is distended, and the lumen is partially filled with keratin layers (Fig. 6). The lining urinary epithelium shows squamous metaplasia (Fig. 7). Throughout the renal parenchyma, there are frequent urate tophi characterized as deposits of basophilic, radiating, crystalline material occasionally surrounded by few macrophages, multinucleated giant cells, and/or heterophils (not shown in images).

Heart: The epicardial surface is lined by a layer of lightly basophilic, amorphous, urate material (Fig. 8).

• **Morphologic Diagnosis:**

Esophagus: Glandular squamous metaplasia with keratinization, distension, and mild, multifocal, chronic, lymphoplasmacytic esophagitis

Kidney: Ureteral squamous metaplasia with keratinization, luminal obstruction, and urate tophi

Heart: Diffuse epicardial urate deposition (visceral gout)

• **Cause:** Vitamin A deficiency.

• **Confirmatory Test:** Vitamin A quantification

Vitamin A quantification can be performed on feed, serum samples, or liver samples. Samples should be protected from light after collection. Selected liver samples in this case were submitted since no feed or serum samples were provided. In one peahen and one peacock, vitamin A levels measured 2.93 ug/g and 10.75 ug/g, respectively. Reference ranges for peafowl were not available; however, normal liver vitamin A levels in chickens range from 245 – 1,225 ug/g.

• **Pathogenesis:** Deficient dietary intake of vitamin A → squamous metaplasia of respiratory, alimentary, and genitourinary epithelium → production of keratin in the ureter → ureteral obstruction → failed excretion of uric acid → uricemia → visceral urate deposition

Comments:

Vitamin A deficiency, also called hypovitaminosis A, is a nutritional disease resulting from low dietary levels of vitamin A. Vitamin A is an essential fat-soluble vitamin, has diverse roles in the body, and is important for mucous membrane integrity, vision, growth, and immune system health (2,6). In poultry diets and rations, alfalfa meal and/or corn are the typical sources of vitamin A. Vitamin A levels in feed can be low in poorly rationed diets, old diets with prolonged storage of corn, or in diets with rancid fat (6).

Vitamin A is converted to retinoic acid in the body. Retinoic acid regulates cell growth and differentiation, particularly for mucus-secreting, moist epithelium such as that lining the conjunctiva, respiratory tract, upper digestive tract, and genitourinary tracts (2,4). With insufficient levels of vitamin A, these epithelia undergo squamous metaplasia with differentiation of the basal cells into squamous cells rather than the typical cuboidal to columnar epithelial cells and goblet cells (1, 3,4). These layers often become stratified and keratinized. Additionally, there is associated loss of cilia with failure of mucociliary clearance.

In adult poultry, clinical signs typically develop 2-5 months after the birds consume vitamin-A deficient diets due to vitamin A storage reserves available in the liver (6). Clinical signs and gross lesions correlate to the moist membranes affected by vitamin A deficiency. The

conjunctiva and sinuses may be swollen with excess mucus and potentially caseous debris accumulating. Differentials should include infectious coryza, fowl cholera, avian poxvirus, and other infectious upper respiratory diseases (6). Mucosal surfaces of the oral cavity, oropharynx, esophagus, and sometimes crop may be partially coated by plaques of pale tan to yellow, caseous debris. In many cases, this is where lesions first appear (4). At this earlier stage, differentials could include avian poxvirus, candidiasis, and trichomoniasis. In more advanced cases such as seen in these peafowl, there are raised, nodular to pustule-like masses corresponding to distended mucous glands filled with keratin and squamous cells (1,3). This appearance should lend more confidence to vitamin A deficiency as the cause.

Though less common than upper respiratory and upper digestive tract lesions, other moist to mucous-lined membranes should be examined for changes at necropsy such as the lower respiratory tract, lower digestive tract, urinary tract, and reproductive tract. This case is an excellent example of how the ureters can be affected.

Histologically, affected membranes show squamous metaplasia with proliferation of squamous cells in place of typical cuboidal to columnar epithelium (4,5). In the esophagus and oropharynx, this change is most prominent within mucous glands and their ducts (4). Glands are often distended and obstructed. They may be filled with keratin, squamous cells, and/or plugged with mucus. Inflammation is typically minor though it may be more prevalent in areas of gland rupture.

As a secondary condition, these peafowl also demonstrated extensive visceral urate deposition (VUD), also known as visceral gout or acute urate deposition. VUD occurs following failed excretion of uric acid, which is primarily excreted through the renal proximal tubules and glomeruli (5). Causes of failed or reduced excretion can include dehydration, renal diseases such as nephritis, and post-renal obstructions. This results in uricemia with precipitation of urates within the kidneys and on mesothelial surfaces. In one peahen shown here, the gout primarily developed secondary to ureteral keratin obstruction caused by the vitamin A deficiency. Lesser amounts of keratin may have obstructed ureters in the other peafowl without mass formation. Dehydration was also likely a major contributing factor in these peafowl given the excess mucus in the oral cavity.

In summary, this is a case of vitamin A deficiency in adult peafowl. The peafowl demonstrated characteristic raised, pored masses in the oropharynx and esophagus corresponding to distended mucous glands with squamous metaplasia and keratinization. They also showed visceral urate deposition (visceral gout) with one peahen showing squamous metaplasia of the ureter and accumulation of obstructing keratin. Vitamin A deficiency was confirmed with vitamin A quantification of liver samples.

References:

1. Aye PP, Morishita TY, Saif YM, Latshaw JD, Harr BS, Cihla FB. Induction of vitamin A deficiency in turkeys. *Avian Dis* 2000;44: 809-17.
2. Cortes PL, Tiwary AK, Puschner B, Crespo RM, Chin RP, Bland M, Shrivaprasaid HL. Vitamin A deficiency in turkey poults. *J Vet Diagn Invest* 2006;18: 489-94.
3. Crespo R, Franca MS, Fenton H, Shivaprasad HL. Galliformes and columbiformes. In: Terio KA, McAloose D, St. Leger J eds. *Pathology of Wildlife and Zoo Animals*. Cambridge, MA: Elsevier Inc.; 2018. p. 742.
4. Klasing KC, Korver DR. Nutritional diseases. In: Swayne DE, editor. *Diseases of poultry*. 14th Ed, Vol 2. Hoboken, NJ: John Wiley & Sons, Inc.; 2020. pp. 1259-62.
5. Schmidt RE, Reavill DR, Phalen DN. Urinary System. In: *Pathology of Pet and Aviary Birds*. 2nd Ed. Hoboken, NJ: John Wiley & Sons, Inc.; 2015. p. 129.
6. Shivaprasad HL. Nutritional diseases In: Boulianne M, ed. *Avian Disease Manual*. 8th Ed. Jacksonville, FL: AAAP; 2019. pp. 149-51.